

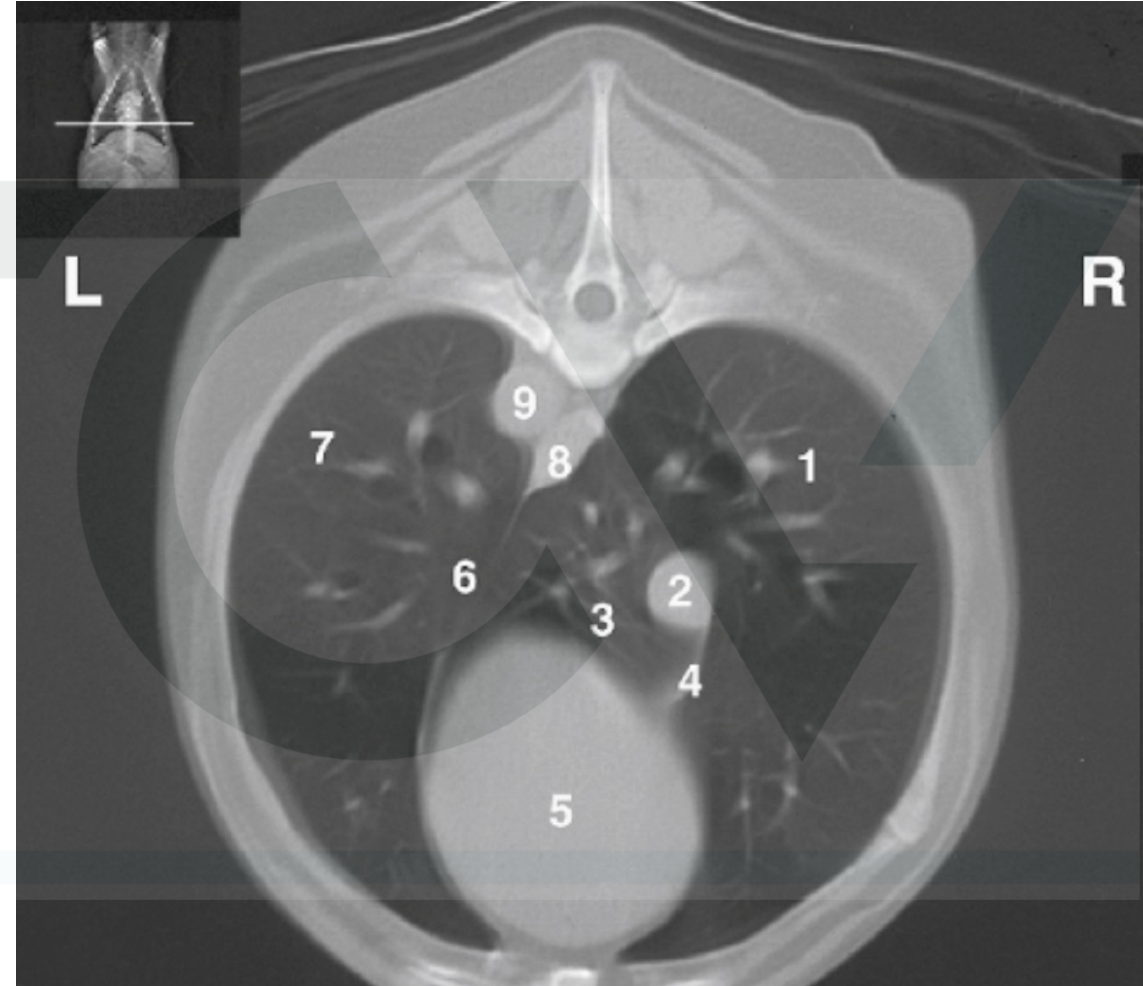
MCQ  
Chapter 90 : The oesophagus

Tobias club 7/10/21



Regarding this CT image, which legend is correct ?

- A. 2. caudal vena cava / 4. Plica vena cava / 8. Oesophagus / 9. Aorta
- B. 2. Caudal vena cava / 3. Accessory lobe / 4. Ventral mediastinum-phrenicopericardial ligament / 8. Aorta
- C. 2. Oesophagus/ 6. Plica vena cava / 8. Vena Cava / 9. Left pulmonary vein
- D. 3. Accessory lobe / 7 Left caudal lobe/ 8. Aorta / 9. Left pulmonary artery



Regarding Swallowing, which statement is correct ?

- A. Oropharyngeal phase is a voluntary process in comparison to oesophageal and gastro oesophageal phase.
- B. Patients with pharyngeal dysphagia have normal movement of bolus through pharynx, but bolus will fail to pass through cricopharyngeal sphincter
- C. Oesophageal swallowing disorders may be caused by mechanical, functional or inflammatory conditions. The functional disorders are most commonly secondary to Peripheral neuropathies, myasthenia gravis or brainstem lesions
- D. Cricopharyngeal asynchrony is an incoordination between contraction of pharyngeal contractor muscles and relaxation of upper esophageal sphincter. The majority of food remains in pharynx, with small portion passing through upper esophageal sphincter.

The high complication rate of oesophageal surgery is not related to:

- A. Lack of serosa and lack of omentum
- B. Tension at surgical site and constant motion caused by swallowing and respiration
- C. Post operative oesophagitis
- D. Segmental nature of blood supply

Which statement is correct regarding oesophageal vascularization

- A. Oesophagus has a rich, intramural plexus of anastomosing vessels in muscular layer that can support long segments of esophagus
- B. The cranial two-thirds of thoracic esophagus vascularized by bronchoesophageal artery and remaining thoracic esophagus by esophageal branches of aorta or azygos artery
- C. The thoracic esophagus drain into dorsal intercostal veins and portal venous system
- D. Most ischemic necrosis at esophageal incision are associated with damage to intramural vascular supply rather than segmental vessels

Which statement is not correct regarding oesophageal approach

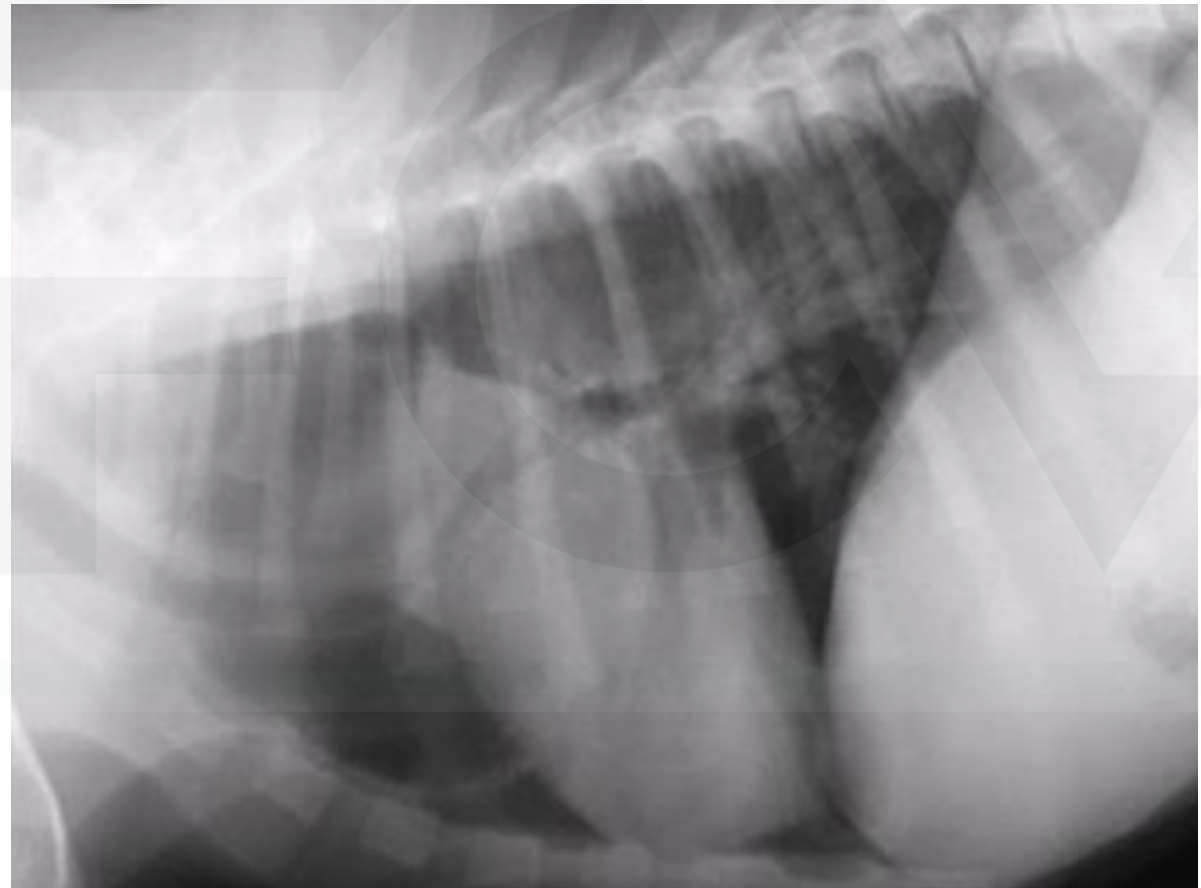
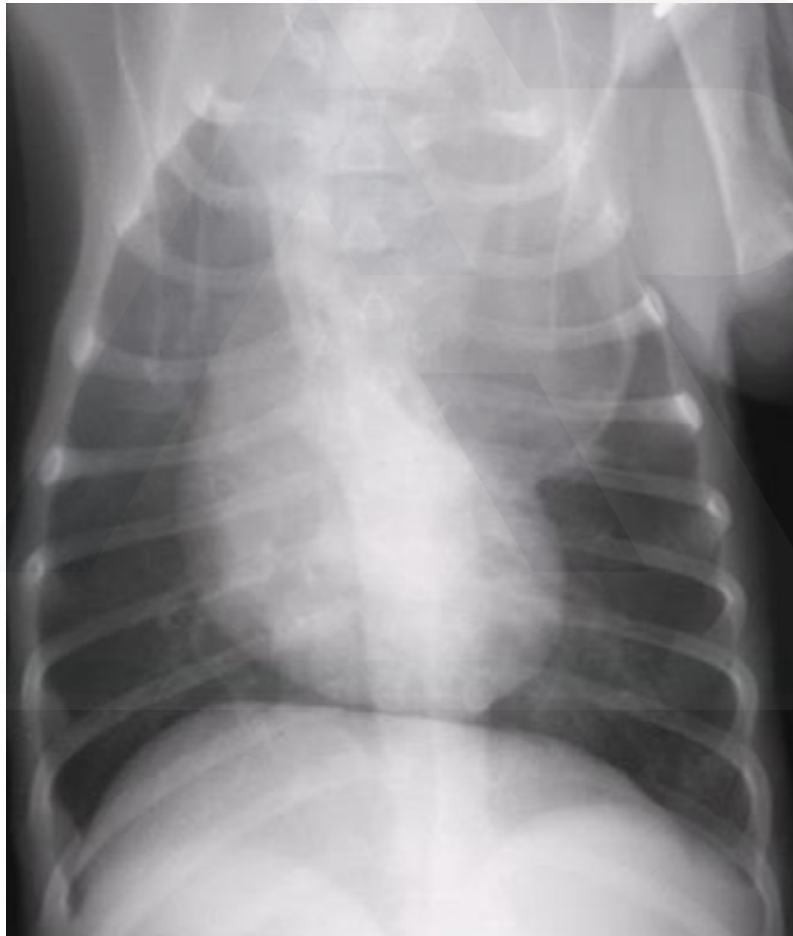
- A. Caudal thoracic esophagus can be exposed via a right-sided 7<sup>th</sup> 8<sup>th</sup> 9<sup>th</sup> intercostal thoracotomy to avoid caudal vena cava and the dorsal and ventral vagus nerves must be identified and preserved
- B. Cranial thoracic esophagus can be exposed via a left 3<sup>rd</sup> 4<sup>th</sup> intercostal thoracotomy with ventral retraction of brachiocephalic trunk and subclavian vessels
- C. Cranial thoracic esophagus can be exposed via a right 3<sup>rd</sup> 4<sup>th</sup> 5<sup>th</sup> intercostal thoracotomy with ventral retraction of trachea and can be combined with retraction or ligation of azygos vein to increase exposure of esophagus at base of heart
- D. The cervical oesophagus can be exposed via a ventral approach of the neck and avoid damage to recurrent laryngeal nerve during tracheal retraction. This approach can be extended via cranial median sternotomy.

Which statement is not correct regarding oesophageal resection and anastomosis

- A. Circumferential partial myotomy is performed by an incision of the outer muscle layer 2 to 3 cm proximal or distal to anastomosis leaving inner muscle layer intact. A separation of muscle layers improved by injecting saline into muscularis
- B. Circumferential partial myotomy can be performed to reduce anastomotic tension and myotomy heals by secondary intention with a high risk of stricture or diverticulum formation
- C. “on-lay” patch is used to reinforce existing esophagus and is applied on esophagotomy incisions or esophageal anastomoses at risk for dehiscence
- D. Omental pedicle flap can support caudal thoracic esophageal wounds and can close small defects because of its vascularity and availability and may decrease esophageal stricture formation



A 12 week old German Shepherd presents for history of regurgitation. The regurgitation began when the dog ate solid food. There is no problems with water drinking. Radiographs were performed.







A 12 week old German Shepherd presents for history of regurgitation. The regurgitation began when the dog ate solid food. There is no problem with water drinking. Radiographs were performed.

What is not a radiographic finding in this case ?

- A. Ventral deviation of trachea and marked ventral curvature and compression of trachea cranial to the heart
- B. Gas and fluid dilated oesophagus
- C. Mass effect in the cranial mediastinum
- D. Well-defined mass in the craniodorsal aspect of the mediastinum



A 12 week old German Shepherd presents for history of regurgitation. The regurgitation began when the dog ate solid food. There is no problems with water drinking. Radiographs were performed.

What is not a differential diagnosis in this case ?

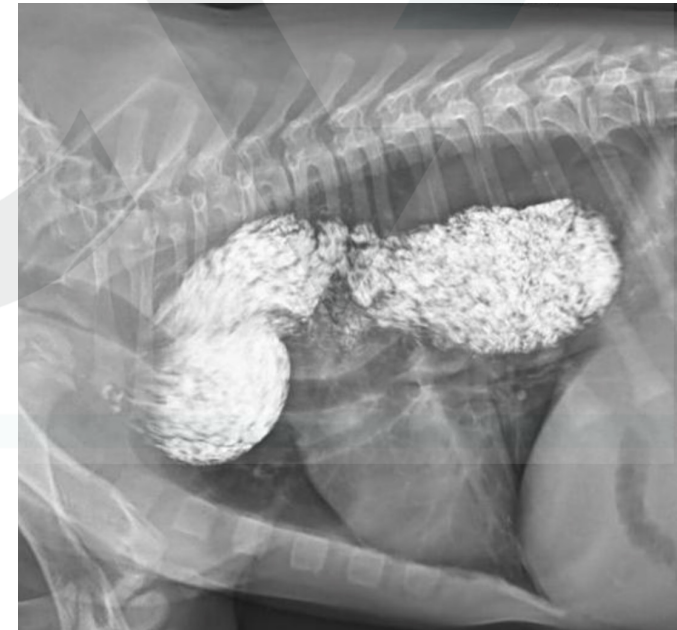- A. Oesophageal stricture
- B. Segmental myasthenia gravis
- C. Congenital megaesophagus
- D. Thymoma



A 12 week old German Shepherd presents for history of regurgitation. The regurgitation began when the dog ate solid food. There is no problems with water drinking. Radiographs were performed.

Which statement is correct regarding the following exam ?

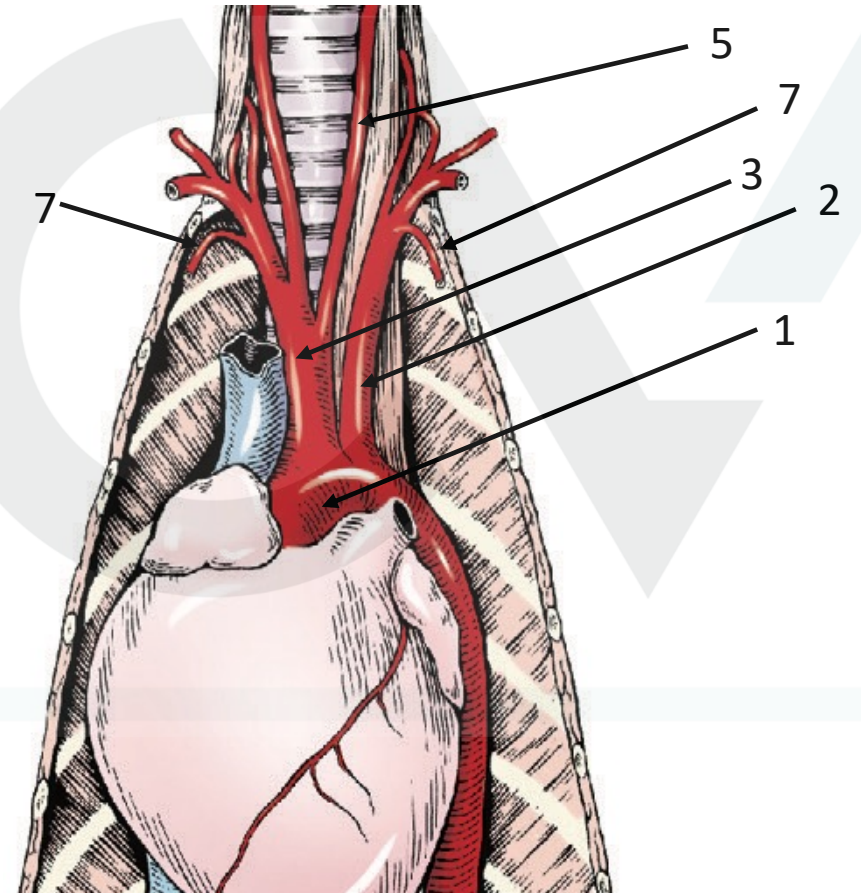
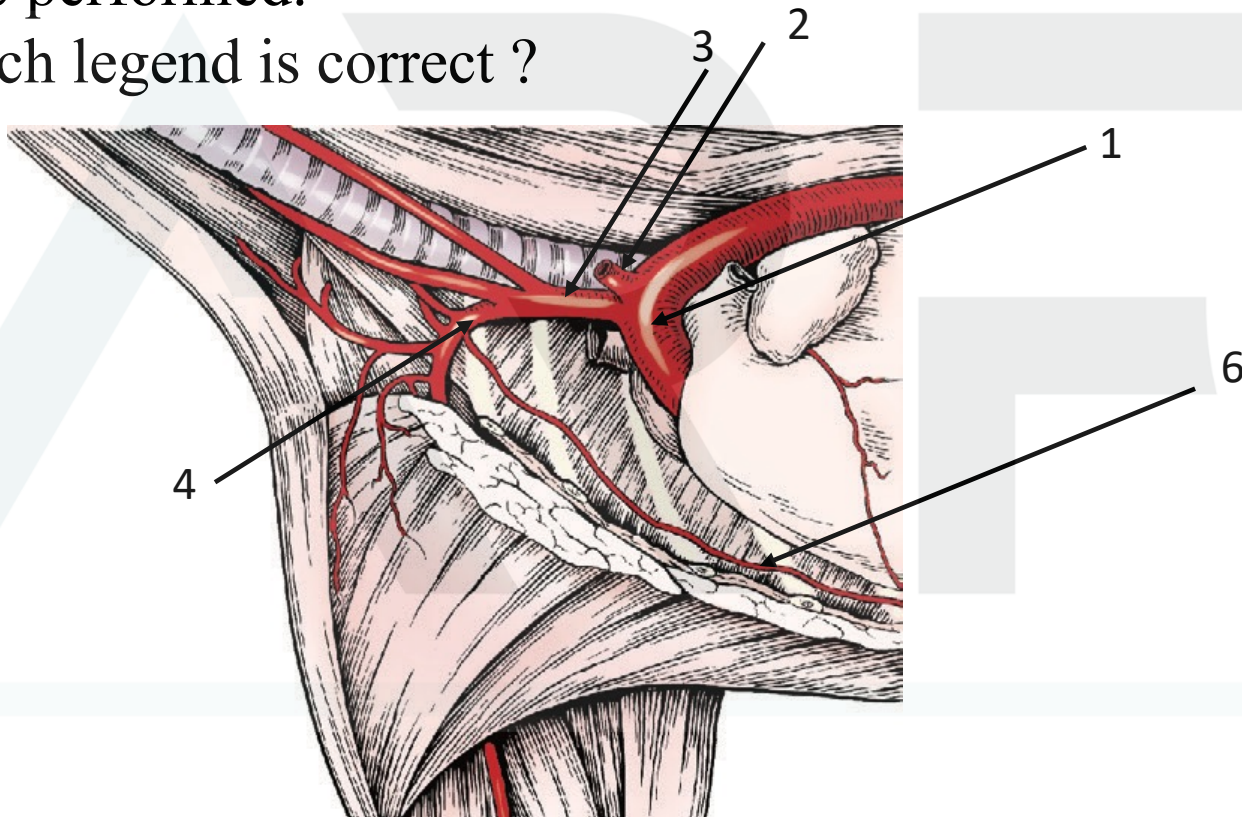
- A. Oesophagogram is performed with hypo-osmolar and nonionic Iodinated contrast media in suspension or in food
- B. Oesophagogram is used to document abnormal esophageal peristaltic activity
- C. Contraindications for a barium swallow include survey radiographic evidence of pneumothorax, pneumomediastinum, and pleural fluid, which are signs of potential esophageal perforation
- D. Oesophagogram is useful in determining type of vascular ring anomaly





A 12 week old German Shepherd presents for history of regurgitation. The regurgitation began when the dog eated solid food. There is no problems with water drinking. Radiographs were performed.

Which legend is correct ?







A 12 week old German Shepherd presents for history of regurgitation. The regurgitation began when the dog ate solid food. There is no problems with water drinking. Radiographs were performed.

Which legend is correct ?

- A. 1. aortic arch / 2. left subclavian / 3. brachiocephalic trunk / 4. right axillary / 5. common carotid artery / 6. internal thoracic artery
- B. 1. Descending thoracic artery / 2. left brachiocephalic trunk / 3. right brachiocephalic trunk / 4. right subclavian / 5. common carotid artery / 6. internal thoracic artery / 7. cervical arteries
- C. 1. aortic arch / 2. left brachiocephalic trunk / 3. right brachiocephalic trunk / 4. right subclavian / 5. common carotid artery / 7. internal thoracic arteries
- D. 1. aortic arch / 2. left subclavian / 3. brachiocephalic trunk / 4. right subclavian / 5. common carotid artery / 7. internal thoracic arteries



A 12 week old German Shepherd presents for history of regurgitation. The regurgitation began when the dog ate solid food. There is no problem with water drinking. Radiographs were performed.

Which statement is not correct ?

- A. Persistent right aortic arch with aberrant left subclavian artery and left ligamentum arteriosum gives 2 strictures and persistent right aortic arch with aberrant left subclavian artery and right ligamentum arteriosum gives 1 stricture
- B. Ductus arteriosus may remain patent in up to 10% of dogs with persistent right aortic arch and right ligamentum arteriosum
- C. Double aortic arch with persistence of both left and right 4<sup>th</sup> aortic arches produce significant tracheal stenosis
- D. Most common vascular ring anomaly described in dogs is the aberrant right subclavian artery which is not described in cats



A 12 week old German Shepherd presents for history of regurgitation. The regurgitation began when the dog ate solid food. There is no problem with water drinking. Radiographs were performed.

Which statement is not correct ?

- A. Persistent right aortic arch with aberrant left subclavian artery and left ligamentum arteriosum gives 2 strictures and persistent right aortic arch with aberrant left subclavian artery and right ligamentum arteriosum gives 1 stricture
- B. Ductus arteriosus may remain patent in up to 10% of dogs with persistent right aortic arch and right ligamentum arteriosum
- C. Double aortic arch with persistence of both left and right 4<sup>th</sup> aortic arches produce significant tracheal stenosis
- D. Most common vascular ring anomaly described in dogs is the aberrant right subclavian artery which is not described in cats



A 12 week old German Shepherd presents for history of regurgitation. The regurgitation began when the dog ate solid food. There is no problem with water drinking. Radiographs were performed.

Regarding complication, which factor is not associated with prognosis ?

- A. Degree of esophageal constriction and dilatation
- B. Severity of debilitation and age of the animal
- C. Presence and severity of aspiration pneumonia before correction
- D. Loss of neuromuscular function