

MCQ
Chapter 92 : Intestine

Tobias club 26/10/21

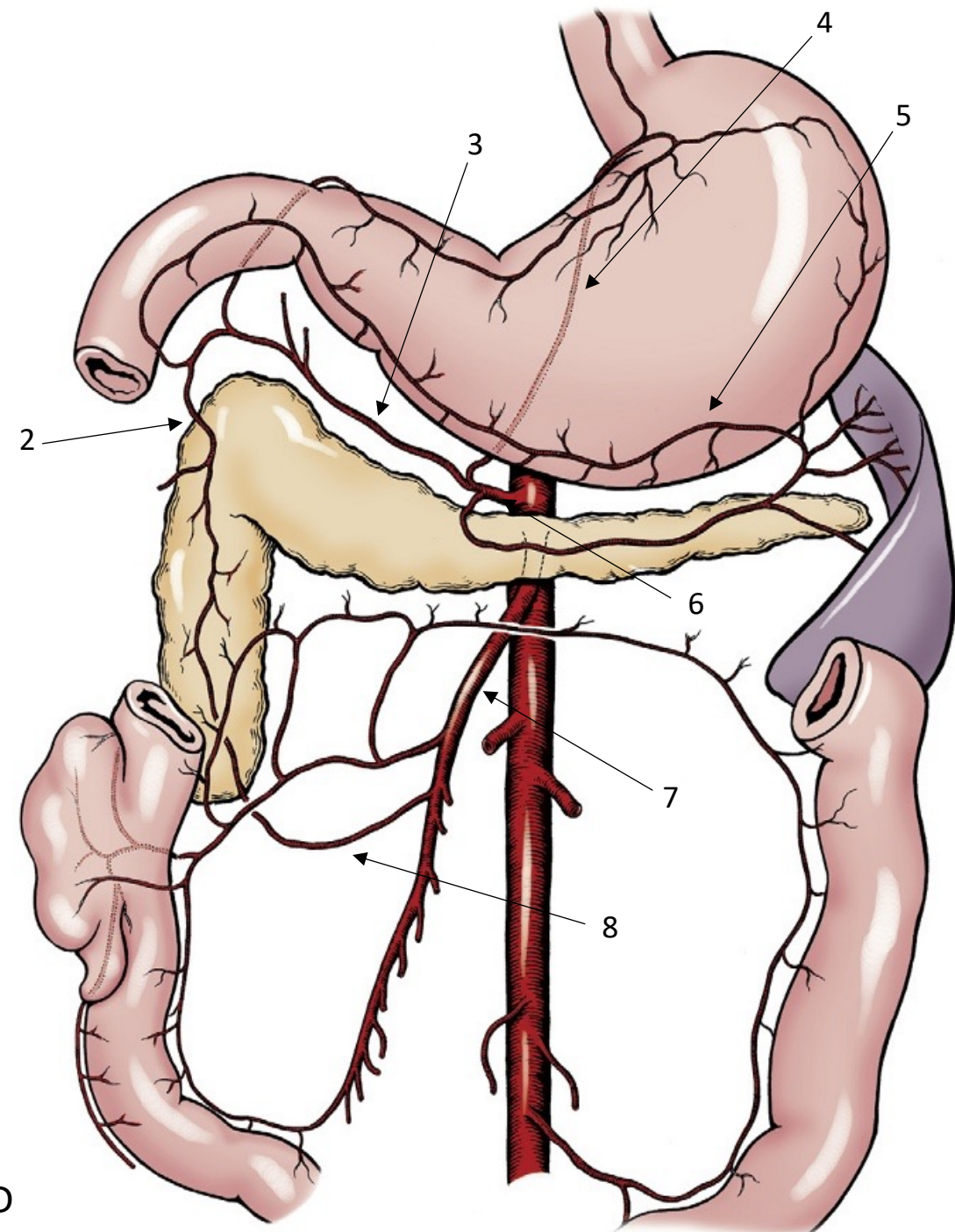


Which statement is not correct regarding pancreatic ducts

- A. In dogs, common bile duct enters duodenum at major duodenal papilla adjacent to pancreatic duct
- B. In cats, common bile duct and pancreatic duct conjoin just before their entry into duodenum at major duodenal papilla.
- C. In dogs, Accessory pancreatic duct enters at minor duodenal papilla and is the principal conduit for pancreatic secretions
- D. Only about 40% of cats have accessory pancreatic duct exiting a minor duodenal papilla

Which legend is correct ?

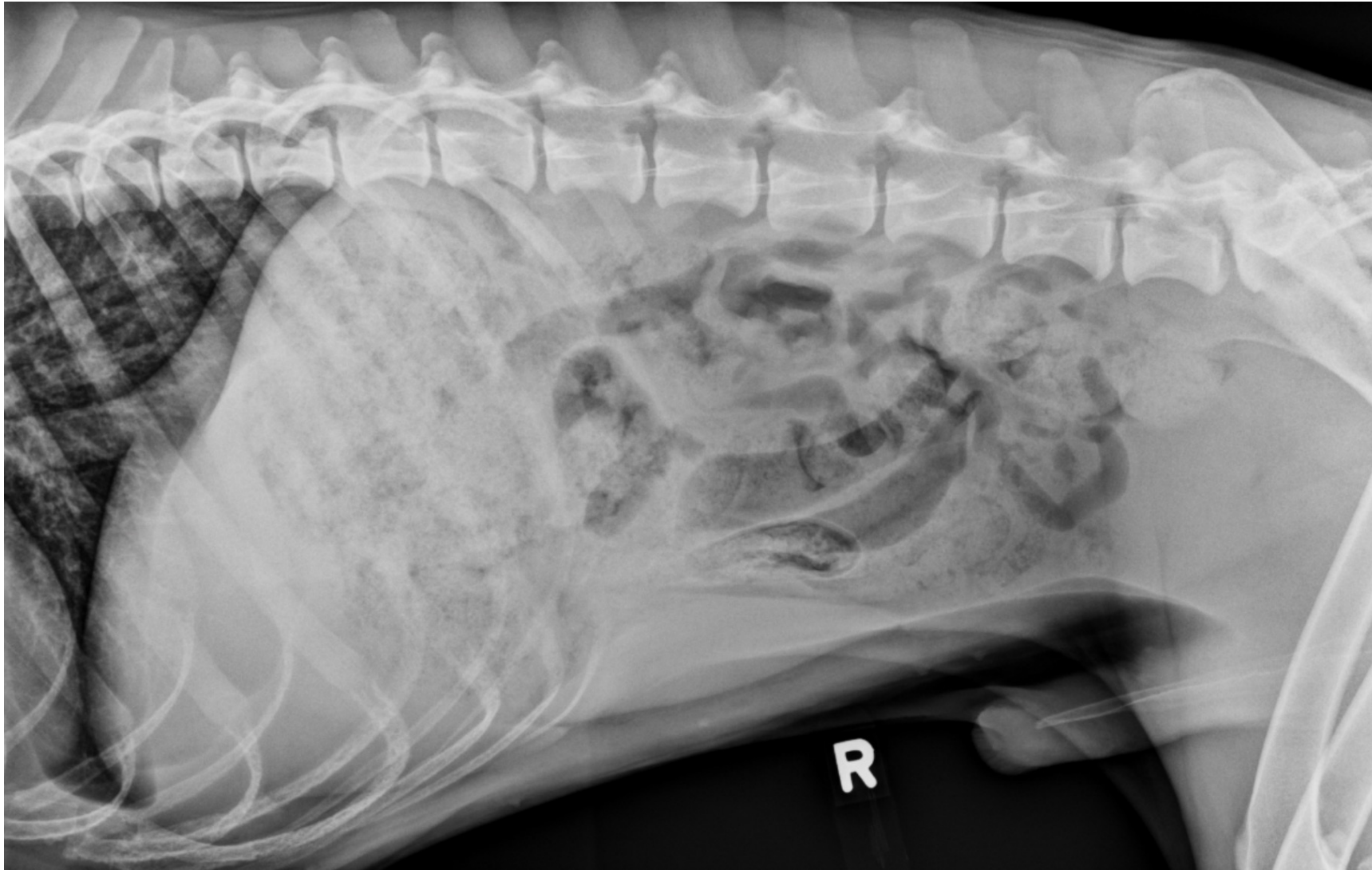
- A. 2. R gastric / 4. L gastric/ 5. L Gastroepiploic / 6. Coeliac / 7. cranial Mesenteric
- B. 2. Cranial pancreatico-duodenal/ 3. hepatic / 4. L Gastric / 6. Coeliac / 7. cranial mesenteric
- C. 2. R gastroepiploic / 3/ hepatic/ 4. L Gastric / 6. cranial mesenteric/ 7. caudal mesenteric
- D. 2. R gastroepiploic / 3. Gastroduodenal / 5. L Gastroepiploic / 7. cranial mesenteric / 8. caudal pancreatico-duodenal

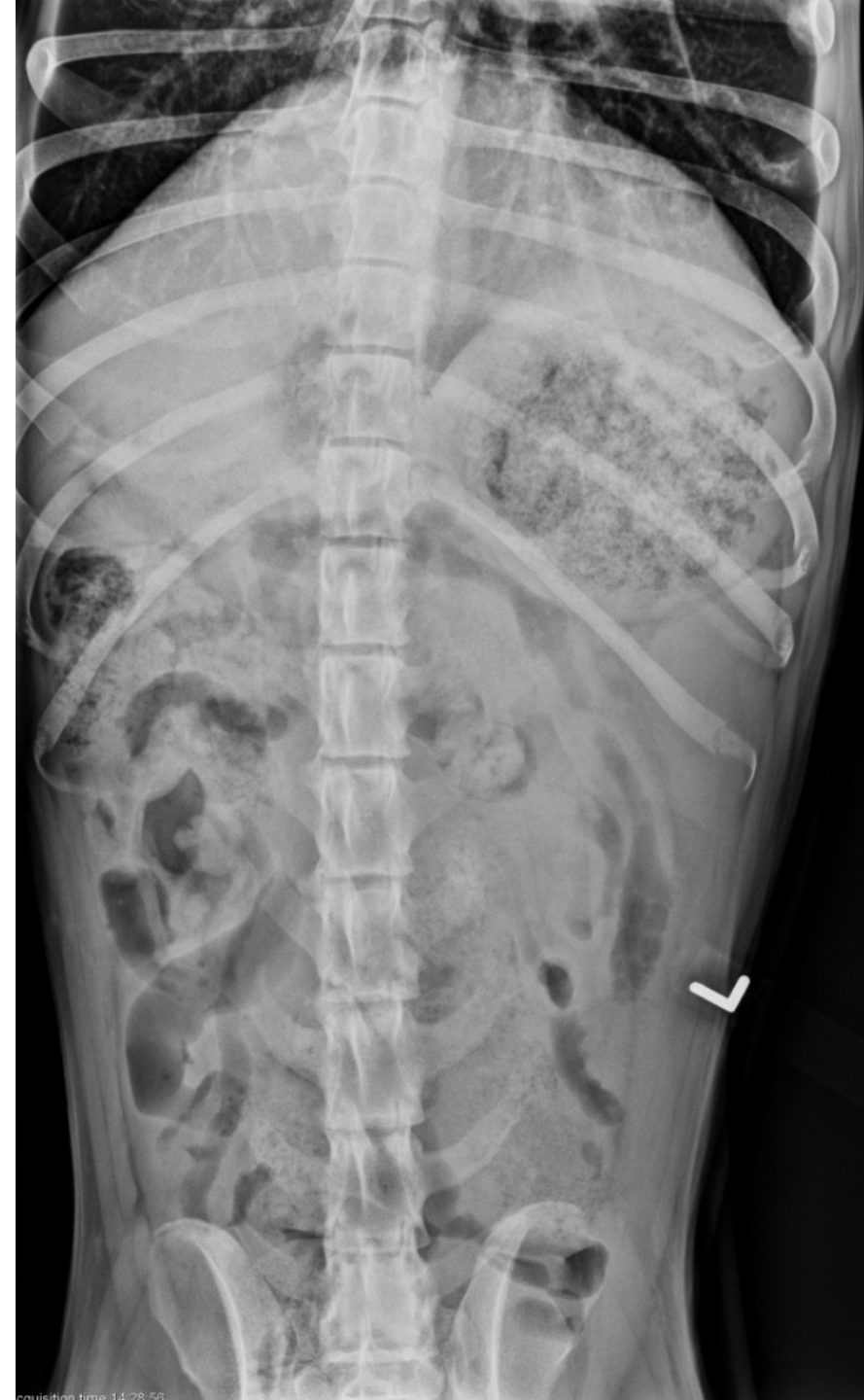
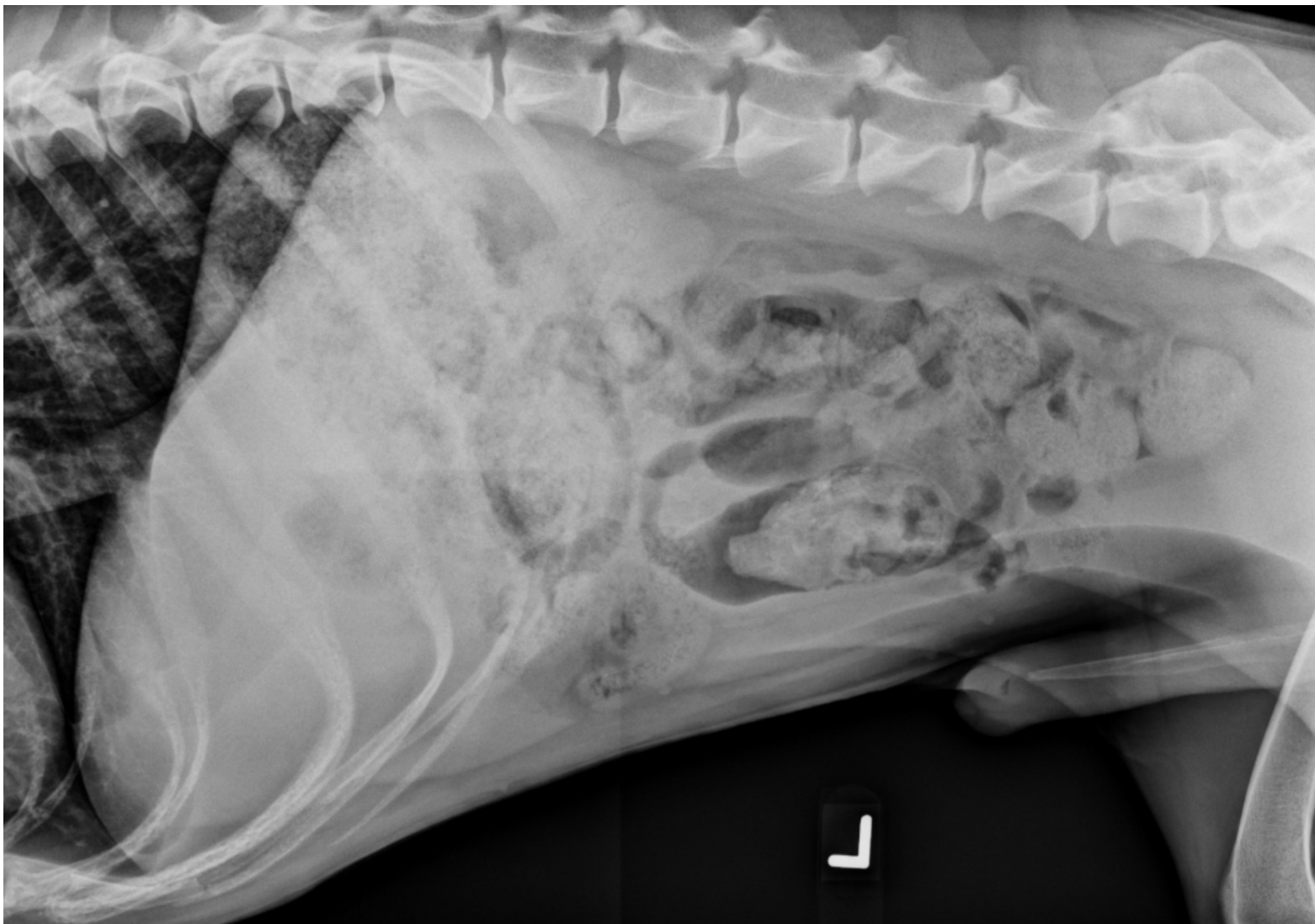
Which statement is not correct regarding vascularization of intestine

- A. Cranial mesenteric vein arborizes in mesentery, collects blood from jejunum, ileum, and caudal duodenum before terminating in distal portal vein
- B. Gastroduodenal vein in cats drains proximal duodenum and enters portal vein proximally
- C. Cranial mesenteric artery anastomoses proximally with branch of celiac artery along descending duodenum and distally with branch of caudal mesenteric artery along descending colon
- D. Cranial mesenteric artery course in mesentery and anastomose with each other in series of arcades from which short vasa recta extend directly into intestinal wall

A 6 year old male Malinois presented for vomiting, lethargy since 3 days.





What is your radiographic findings ?

- A. On the right lateral projection, there is mild enlargement of several small intestinal loops. On the left lateral projection, there is a distended bowel loop that contains a fusiform, radiopaque object. On the v/d projection, there is a small intestinal loop on the right side that is twice the diameter of other loops.
- B. On the left lateral projection, the pylorus is filled with gas, which highlights a soft tissue mass. The mass is near the origin of the duodenum, and is likely fixed in the pylorus as it is on the non-dependent side.
- C. On the right lateral and v/d projections, the stomach is enlarged and fluid-filled. The remainder of the abdomen appears normal.
- D. On abdominal radiographs, the liver, spleen, and kidneys are enlarged. There is a moderate amount of feces in his colon consistent with his history of megacolon. There is a gas distended loop of small intestine in the right ventral abdomen that indicates a mild, focal enlargement and possible small intestinal obstruction.

What is your diagnosis

- A. Small intestinal mass
- B. Small intestinal foreign body obstruction
- C. Peritonitis
- D. Intussusception

Which ratio comparing maximum small intestinal diameter to height of L5 body in dog and cranial end plate of L2 in cats is correct ?

- A. In dogs, ratios < 1.4 : unlikely to have intestinal obstruction
- B. In dogs, ratio > 2.0 : very high likelihood
- C. In cats, - ratios < 1.4 : more likely to have nonobstructive intestinal disorders
- D. In cats, ratios > 2.0 : associated with high likelihood of intestinal obstruction

Animals with small intestine obstruction or ileus have a risk for hypokalemia, hyponatremia, and hypochloremia. Preexisting imbalances corrected before surgery. Which statement is correct regarding electrolyte ?

- A. The rate of potassium supplementation should not exceed 0.2 mEq/kg/h without electrocardiographic (ECG) monitoring to avoid potential cardiotoxic effects
- B. Classic clinical signs of muscle weakness due to hyponatremia in cats : cervical flexion, stiff, stilted gait and pelvic limb weakness that can result in plantigrade stance
- C. Vomiting with excessive loss of gastric fluids give a risk for hypokalemia, hypochloremia and metabolic alkalosis.
- D. Severe hypokaliemia can be treated with calcium gluconate at a dose of 0.5 to 1 mL/kg over 10 to 20 minutes

An enterotomy was performed to remove the FB in the jejunum ? Which statement is correct regarding intestinal surgery

- A. The volume of saline required to achieve normal peristaltic intraluminal pressure in 10-cm segment of healthy bowel containing closed enterotomy site = 6 to 9 mL with digital occlusion and 2 to 5 mL with Doyen occlusion
- B. Clinical factors as presence of peristalsis, vascular pulsations, intestinal color correlate with histologic severity of damage or survival of animal. Fluorescence is a more reliable indicator of mucosal viability than true intestinal viability in dogs
- C. A comparative study of simple interrupted and continuous patterns to close enterotomy showed low and comparable rate of enteric leakage with either pattern but simple interrupted elicit adhesion formation and greater initial narrowing of intestinal lumen
- D. Experimental study showed that omentum, when wrapped around avascular small intestine anastomosis forms adherent sheath capable of preventing perforation and fatal leakage and revascularizing region

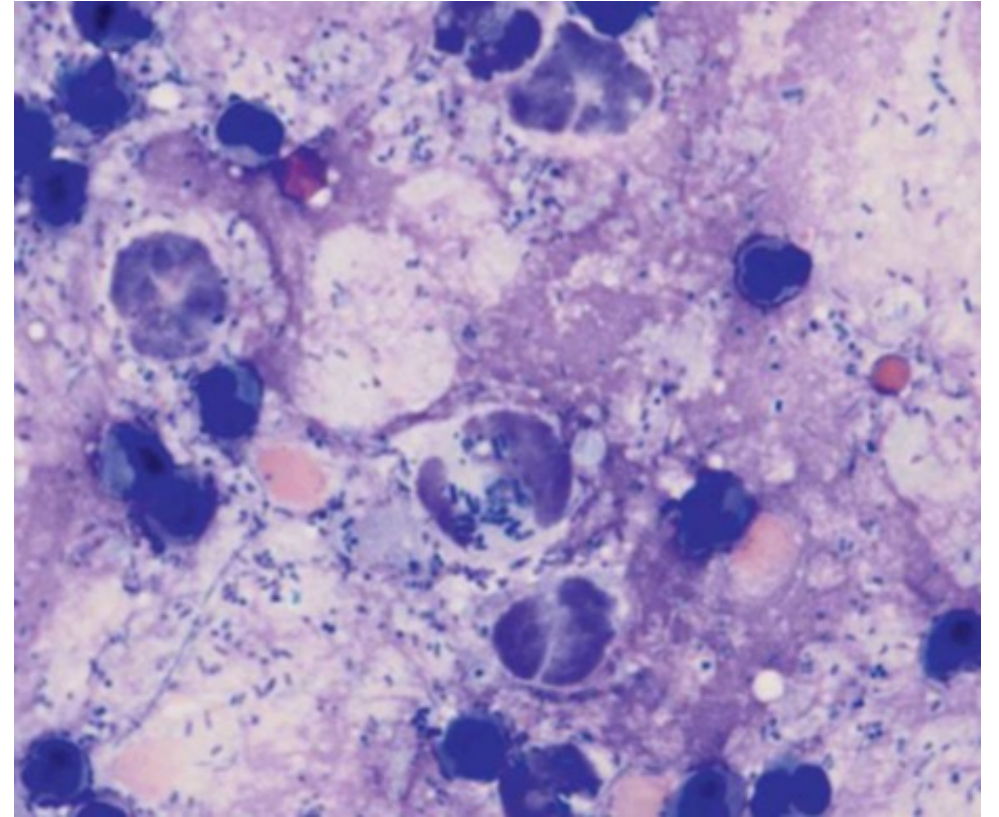
Temperature recommendations for lavage solution is within :

- A. 35° C to 37° C
- B. 36° C to 38° C
- C. 37° C to 39° C
- D. 38° C to 40° C

Abdominal ultrasound revealed peritoneal fluid. A direct smear prepared from the peritoneal fluid is shown.

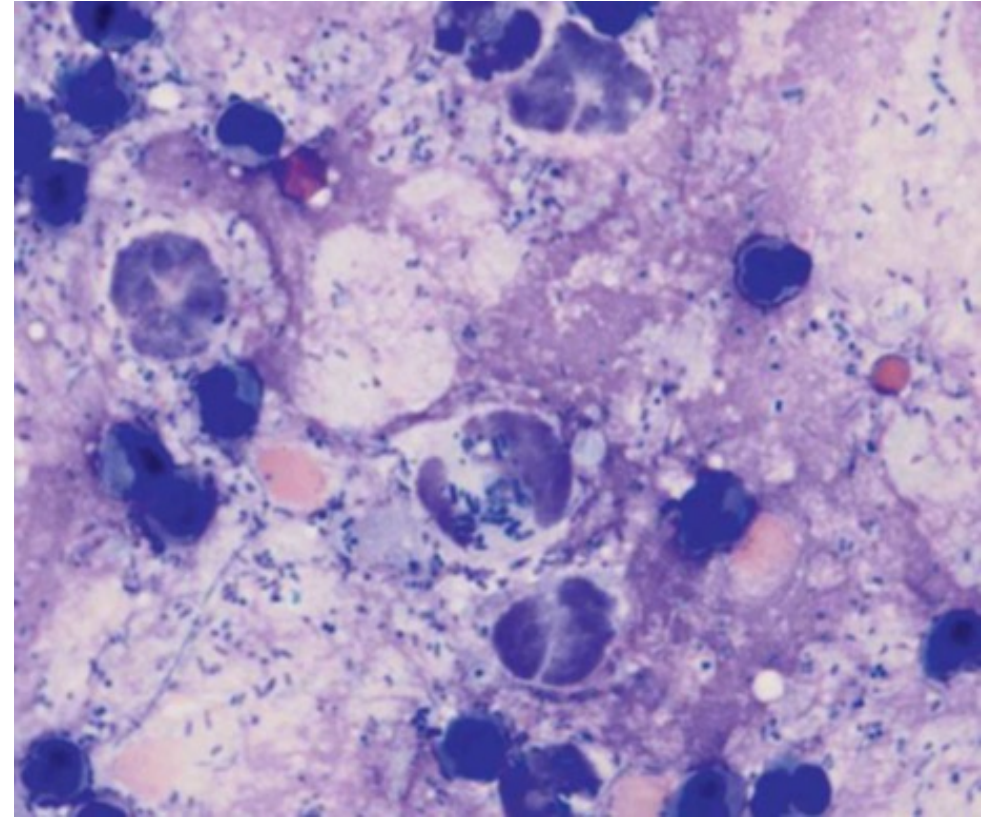
How would you classify the fluid ?

- A. Transudate
- B. Exsudate with aseptic inflammation
- C. Exsudate with septic inflammation
- D. Modified transudate



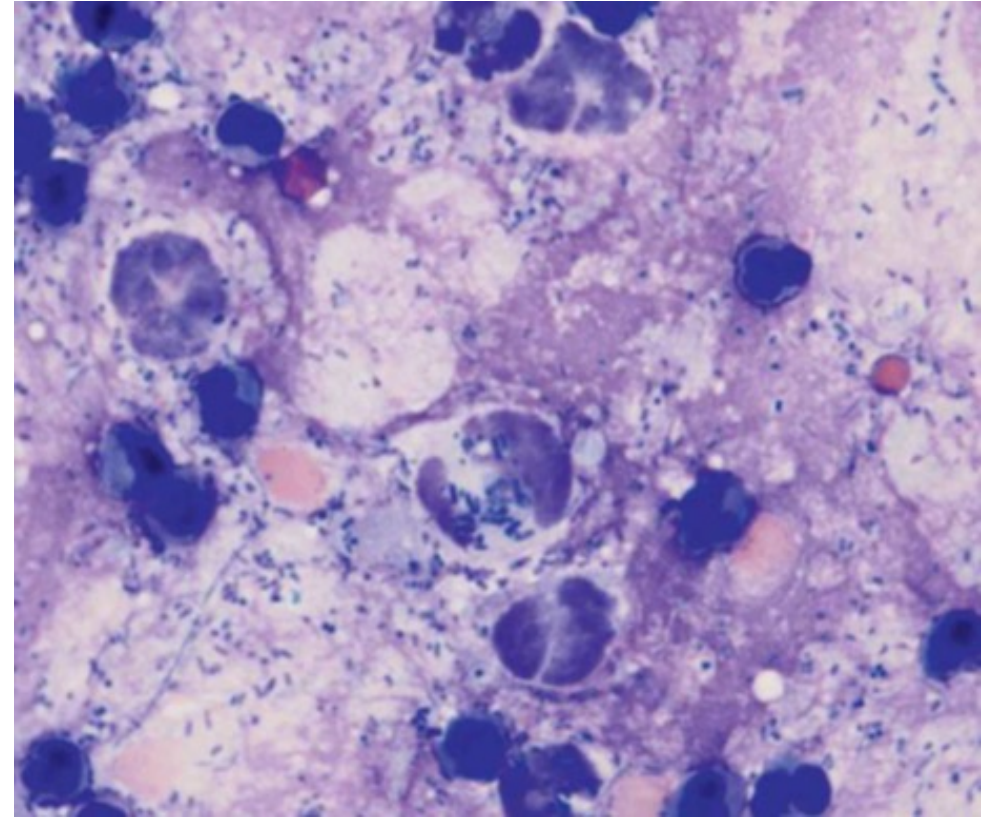
Septic peritonitis was diagnosed. Which parameter is not predictors of leakage from anastomoses or enterotomies

- A. Hypoalbuminemia
- B. Hypotension
- C. Hypoglycemia
- D. Longer length of bowel resected



Abdominal auscultation in this dog may reveal

- A. Increased bowel sounds
- B. Decreased or absent bowel sound
- C. Increased Gastric sounds
- D. Movement of fluids



Regarding septic peritonitis following GI surgery.

- A. Increased bowel sounds
- B. Decreased or absent bowel sound
- C. Increased Gastric sounds
- D. Movement of fluids