

# Proximodistal and caudocranial position of the insertion of the patellar ligament on the tibial tuberosity and patellar ligament length of normal stifles and stifles with grade II medial patellar luxation in small-breed dogs

Liene Feldmane DVM | Lars F. H. Theyse DVM, PhD, DECVS

Department for Small Animals, Soft Tissue & Orthopedic Surgery Service, College of Veterinary Medicine, University of Leipzig, Leipzig, Germany

## Correspondence

Lars F. H. Theyse, College of Veterinary Medicine, Department for Small Animals, Soft Tissue & Orthopedic Surgery Service, University of Leipzig, An den Tierkliniken 23, D-04103 Leipzig, Saxony, Germany. Email: lars.theyse@kleintierklinik.uni-leipzig.de

## Abstract

**Objective:** To assess the role of the proximodistal and caudocranial relative position of the patellar ligament insertion on the tibia and patellar ligament length-to-patellar length ratio (PLL:PL) in small-breed dogs with and without grade II medial patellar luxation (MPL).

**Study Design:** Retrospective study.

**Sample Population:** Dogs weighing  $\leq 15$  kg, including 43 stifles with MPL and 34 control stifles.

**Methods:** The proximodistal and caudocranial relative position of the patellar ligament insertion was determined as a ratio using the vertical (VTT) and horizontal distance (HTT) between the tibial tuberosity insertion and the tibial plateau divided by the tibial plateau length (TPL). In addition, PLL:PL and tibial plateau angle (TPA) were determined.

**Results:** The VTT:TPL ratio was lower in affected stifles (95% CI: 0.86–0.94) than in the control group (0.93–1.01;  $p = .01$ ). No other difference was identified between affected and normal stifles.

**Conclusion:** The only difference identified in this study consisted of a more proximal position of the patellar ligament insertion in the stifles of small-breed dogs with grade II MPL.

**Clinical Significance:** The more proximal position of the patellar ligament insertion will result in a more proximal position of the patella in the trochlear groove and may contribute to the development of MPL. Potentially, this will also affect the risk of recurrence of MPL after surgical treatment.

## 1 | INTRODUCTION

Patellar luxation is a common cause of hind limb lameness in dogs.<sup>1–3</sup> It is considered one of the most frequent

diseases of the stifle joint.<sup>2,4</sup> The patella can luxate out of the femoral trochlear groove either medially, laterally, or bidirectionally.<sup>5</sup> Medial patellar luxation (MPL) is the most common form with around 84%–95% of dogs

This is an open access article under the terms of the Creative Commons Attribution-NonCommercial-NoDerivs License, which permits use and distribution in any medium, provided the original work is properly cited, the use is non-commercial and no modifications or adaptations are made.

© 2021 The Authors. *Veterinary Surgery* published by Wiley Periodicals LLC on behalf of American College of Veterinary Surgeons.

suffering from MPL. Lateral or bidirectional luxation is diagnosed in about 2%–16% and 3% of dogs, respectively.<sup>1,5–8</sup> Bilateral MPL is present in up to 50% of affected dogs.<sup>3,5,9</sup> All breeds of dogs can be affected by MPL, but the prevalence of medial patellar luxation in small-breed dogs is reported to be 12 times higher than in large-breed dogs.<sup>1</sup> Toy breeds are predisposed to develop this condition.<sup>1,4,8–17</sup> In view of these findings, MPL is considered to be an inherited developmental disorder.<sup>1,5,12</sup> Traumatic patellar luxation is extremely rare in dogs.<sup>1</sup> The primary consideration in the etiology of MPL is that affected dogs develop musculoskeletal abnormalities in the pelvic limbs during growth. These malformations lead to an imbalance of the stifle extensor mechanism alignment and instability of the patella.<sup>2,12,18,19</sup> The main anatomical anomalies described include a shallow trochlear groove, femoral varus, internal torsion of the proximal tibia, medial displacement of the tibial tuberosity, and hypoplasia of the patella.<sup>18–22</sup> Nevertheless, several studies show discrepancies in the assumed pathogenesis of MPL. For example, coxa vara was believed to be one of the most important contributors to the formation of MPL in dogs.<sup>22</sup> Recent studies found a physiological or increased angle of inclination in the femurs of animals suffering from MPL.<sup>6,18,21,23</sup> In addition, patella alta and an increased ratio of patellar ligament length to patellar length (PLL:PL) are considered to be present in large-breed dogs with MPL.<sup>7,24,25</sup> In contrast, studies in medium and small breeds showed PLL:PL ratios to be within the physiological range in both healthy and affected animals.<sup>12,13,21,26,27</sup> The extensive research and the differences in results indicate the complexity of the disease and the still unclear pathogenesis of MPL.

The surgical treatment of MPL is mainly based on the severity of clinical signs.<sup>1,9,14</sup> The primary function of the surgical correction is to realign the extensor mechanism and to stabilize the patella thus restoring proper function of the stifle joint. If indicated, deepening of the femoral trochlear groove can be part of the intervention.<sup>3,12,14,17,27</sup> The standard procedures include imbrication of the lateral femoropatellar ligament and fascia, release of the medial femoropatellar ligament and fascia, tibial tuberosity transposition, femoral trochleoplasty and, if necessary, osteotomies of the femur or tibia.<sup>1,3,8,10,12–14,22</sup> The overall recurrence rate of patellar luxation is still high at 8%–48% of operated animals with 6%–18% of dogs requiring revision surgery.<sup>1,3,8,10,14,15,17,28</sup> The main reason for recurrence is believed to be an incomplete knowledge of the anatomical deformities and functional deficits responsible for MPL.<sup>7</sup>

To the best of our knowledge, there has been no study assessing the role of the proximodistal and caudocranial relative position of the insertion of the patellar ligament on the tibial tuberosity as a factor in medial patellar luxation.

We hypothesized that an alteration in the proximodistal and/or caudocranial relative position of the insertion of the patellar ligament could be associated with MPL. The more proximal and cranial relative position of the patellar ligament insertion could potentially lead to a more proximal position of the patella in the femoral trochlea, instability of the patella during development of the stifle extensor mechanism, and subsequent MPL.

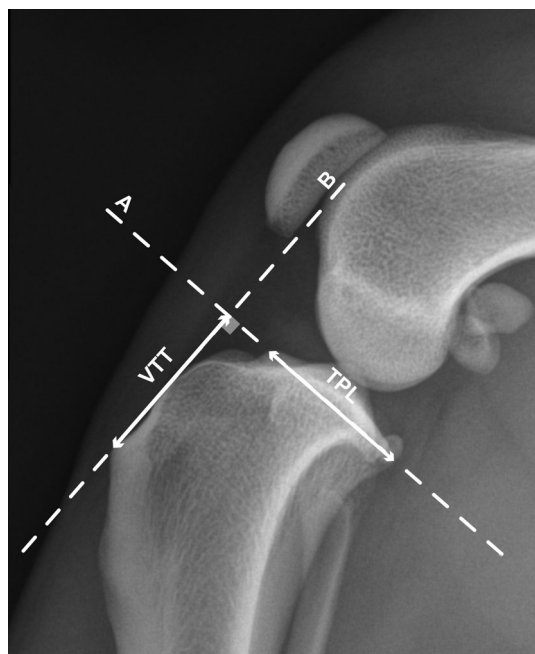
## 2 | MATERIALS AND METHODS

### 2.1 | Dogs

This study evaluated medical records of dogs admitted to the hospital with MPL from June 2016 to April 2019. The collected data included information about breed, weight, age, gender, affected hindlimb (right, left or both), grade of MPL and a full orthopedic workup. Only animals with MPL weighting  $\leq 15$  kg, a documented orthopedic examination and a complete set of stifle radiographs were included. Dogs in the MPL group were classified into four grades defining grade I as a patella that can only be luxated manually with immediate spontaneous reduction and without any clinical signs, grade II as a patella that can be luxated manually but also luxates spontaneously thus causing clinical signs but still with spontaneous reduction, grade III as a patella that is luxated all of the time, but with the possibility of manual reduction, and grade IV as a patella that is luxated all of the time without the possibility of manual reduction.<sup>22</sup> Only dogs with unilateral or bilateral grade II MPL were included in the study as this is the most common form of the disease.<sup>1,3,7,9,14–17</sup> In addition, only dogs with grade II MPL allowed for correct radiographic evaluation of the geometry of the proximal tibia and patellar tendon insertion without distortion. A control group was formed consisting of healthy dogs without MPL, any other stifle joint pathology and with a similar weight and size distribution.

### 2.2 | Radiographs and measurements

Mediolateral radiographs of the stifle joint from each dog were used to perform the measurements. Correct positioning was determined as superposition of femoral condyles, superposition of tibial intercondylar eminences and clear delineation of the tibial plateau.<sup>18,26,29–31</sup> A blind investigation of the data was conducted. The radiographic length of the tibial plateau in a cranial to caudal direction in the mediolateral views was used to allow for calculation of ratios independent of the size of dog or magnification of radiographic images.<sup>25</sup> The proximodistal relative position of the insertion of the patellar ligament on the tibial

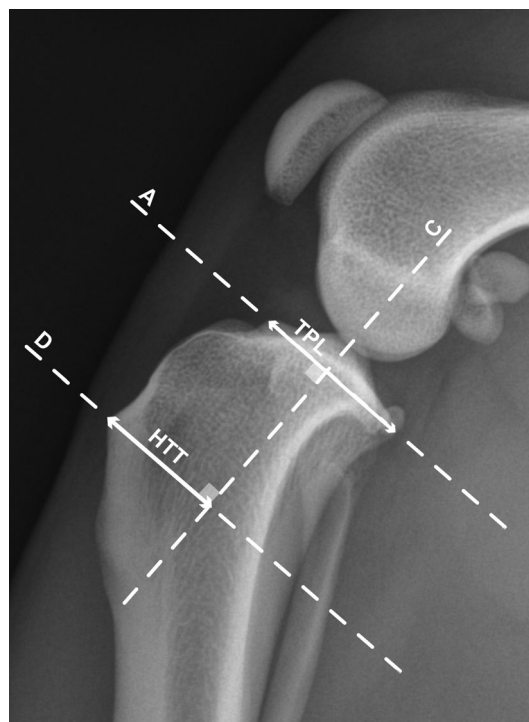

**FIGURE 1** Measurement of the ratio vertical tibial tuberosity distance to tibial plateau length (VTT:TPL). Measurement of the proximodistal relative position of the insertion of the patellar tendon on the tuberosity of the tibial crest on a mediolateral radiograph. A. Dashed line drawn through the tibial plateau; tibial plateau length (TPL) measured from the most cranial to the most caudal point; B. dashed line through the distal insertion of the patellar tendon and perpendicular to the line A; vertical tibial tuberosity (VTT) distance measuring from the most distal insertion of the patellar tendon on the tuberosity to line A

tuberosity was defined as a ratio of the vertical distance of the tibial tuberosity insertion to the level of the tibial plateau divided by the tibial plateau length (VTT:TPL) (Figure 1). The caudocranial relative position of the insertion of the patellar tendon on the tibial tuberosity was determined as a ratio of the horizontal distance of the tibial tuberosity insertion to the center of the tibial plateau divided by the tibial plateau length (HTT:TPL) (Figure 2). The bony landmarks were defined and verified by both authors blinded to the actual diagnosis. To assess the possible contributing effect of the patellar ligament length on the patella position, the PLL:PL ratios were measured using the modified method described by Mostafa and colleagues.<sup>7</sup> The tibial plateau angle (TPA) was determined to exclude any potential effect on VTT:TPL and HTT:TPL ratios.<sup>32</sup> All measurements were done by the first author using the dedicated imaging software (IntelliSpace PACS, Philips, Eindhoven, Netherlands) to avoid interpersonal variability.

### 2.3 | Statistical analysis

An unpaired t-test was used to compare the measured VTT:TPL, HTT:TPL, and PLL:PL ratios, and TPA



**FIGURE 2** Measurement of the ratio horizontal tibial tuberosity distance to tibial plateau length (HTT:TPL). Measurement of the caudocranial relative position of the insertion of the patellar tendon on the tuberosity of the tibial crest on a mediolateral radiograph. A. Dashed line drawn through the tibial plateau; tibial plateau length (TPL) measured from the most cranial to the most caudal point; C. dashed line drawn through the center of the tibial intercondylar eminences and perpendicular to the line A; D. dashed line through the distal insertion of the patellar tendon on the tuberosity perpendicular to line C; horizontal tibial tuberosity (HTT) distance measuring from the distal insertion of the patellar tendon on the tuberosity to line C

between the dogs with and without MPL. The level of significance was fixed at  $p < .05$ . The 95% confidence intervals (CIs) were calculated for both groups and all ratios. All medical data are shown as mean and standard deviation (SD). Data analysis was conducted using the statistical package of MS Excel (Microsoft Excel, Microsoft, Redmond, Washington).

## 3 | RESULTS

### 3.1 | Control dogs without medial patellar luxation

The control group included 34 stifles of 29 dogs. The radiographs included 18 right stifles and 16 left stifles. The mean weight  $\pm$  SD in the control group was  $9.1 \pm 2.9$  kg and the mean age  $\pm$  SD was  $6.9 \pm 3.8$  years. The group consisted of 13 females (10 intact and 3 spayed)

and 16 males (6 intact and 10 castrated) with a female-to-male ratio of 1:1.2. The control group included 13 breeds with 9 mixed breed dogs, 4 each of Yorkshire Terriers and Jack Russel Terriers, 2 each of Beagles and Cocker Spaniels, and 1 each of French Bulldog, Cavalier King Charles Spaniel, Sheltie, West Highland White Terrier, Bolonka Zwetna, Lhasa Apso, Pug and Parson Russel Terrier.

### 3.2 | Dogs with medial patellar luxation

The MPL group included 43 stifles of 29 dogs. The mean body weight  $\pm$  SD was  $7.3 \pm 3.6$  kg and the mean age  $\pm$  SD was  $4.3 \pm 2.9$  years. The age in the MPL group was lower than in the control group ( $p = .005$ ). There was no difference in body weight. The group consisted of 12 females (6 intact and 6 spayed) and 17 males (10 intact and 7 castrated) with a female-to-male ratio of 1:1.4. Seventeen breeds were representing the MPL group and included four each of Pugs and mixed breed dogs, two each of Yorkshire Terriers, Chihuahuas, Pomeranians, Maltese, French Bulldogs, Miniature Pinchers, and one each of Cavalier King Charles Spaniel, West Highland White Terrier, Bolognese, Biewer Terrier, Jack Russel Terrier, Cairn Terrier, Miniature Dachshund, Boston Terrier and Beagle. The number of dogs affected by bilateral and unilateral MPL was almost equal with 14 and 15 animals, respectively. Overall, 23 right stifles and 20 left stifles were included in the study.

### 3.3 | The ratios of the proximodistal relative position and caudocranial relative position of the insertion of the patellar ligament

The mean  $\pm$  SD of the VTT:TPL ratio was lower in the MPL group with  $0.90 \pm 0.13$  (95% CI: 0.86–0.94) against  $0.97 \pm 0.13$  (95% CI: 0.93–1.01) in the control group ( $p = .01$ ). This finding was consistent with a more proximal relative position of the insertion of the patellar ligament on the tibia. No difference was identified in the caudocranial relative position of the insertion of the patellar tendon on the tibia between both groups with the mean  $\pm$  SD of the HTT:TPL ratio of  $1.01 \pm 0.13$  (95% CI: 0.97–1.05) in the MPL group and  $1.04 \pm 0.11$  (95% CI: 1.00–1.08) in the control group ( $p = .33$ ).

### 3.4 | The ratio of the patellar ligament length to the patellar length and tibial plateau angle measurements

There was no difference in the relative patellar ligament length between both groups with the mean  $\pm$  SD of the

PLL:PL ratio of  $1.78 \pm 0.18$  (95% CI: 1.72–1.84) in the MPL group and  $1.82 \pm 0.20$  (95% CI: 1.75–1.89) in the control group ( $p = .42$ ). The TPA was similar for the MPL group ( $25.7^\circ \pm 2.7^\circ$ ) and the control group ( $25.3^\circ \pm 2.7^\circ$ ) ( $p = .47$ ).

## 4 | DISCUSSION

The only difference detected in this population of small-breed dogs consisted of a lower VTT:TPL ratio in stifles with grade II MPL compared to control joints. This finding is consistent with the patellar ligament insertion located more proximally on the tibia in dogs affected by MPL, potentially affecting the position of the patella relative to the femoral trochlea. The true position of the patella in the trochlear groove was not assessed in our study. In contrast, no difference was found in the HTT:TPL ratio and thus craniocaudal relative position of insertion. Theoretically, differences in TPA could have affected the measurements of VTT:TPL and HTT:TPL ratio. The influence of TPA was discarded as there were no differences between both groups. As there were no differences in the HTT:TPL ratios between both groups, the reported differences in VTT:TPL ratio can be interpreted as a genuine alteration in the relative position of the tibial tuberosity. Although the dogs in the MPL group were younger than the controls, all dogs in the MPL group had complete fusion of their tibial apophysis. This finding would exclude any configurational changes due to growth potential.

Patella alta or proximal shift of the patella has been associated with the development of MPL in medium- to giant-breed dogs.<sup>7</sup> The patellar ligament connects the patellar bone with the tuberosity of the tibial crest and is believed to be nonelastic.<sup>25,26</sup> Several studies found a longer patellar tendon in large-breed dogs with MPL compared to a healthy population, which could lead to patella alta.<sup>7,24</sup> However, our study found no difference in the PLL:PL ratios in small-breed dogs with MPL, which is consistent with previous studies in small breeds showing no association between patellar ligament length and MPL.<sup>21,26</sup> With a similar patellar ligament length, a more proximal insertion of the patellar ligament on the tibial tuberosity would have the potential to shift the patellofemoral contact area proximally, thus decreasing patellofemoral stability. During physiological loading with correct joint angles, the patella is stabilized within the trochlea. During extension of the stifle joint, the patella moves proximally in the trochlear groove, which can affect the buttressing effect of the trochlear ridges and stabilization through the femoropatellar ligaments.<sup>24–26</sup> A proximal shift of the patellar ligament



insertion could potentially contribute to the development of MPL. Furthermore, the chronic loss of patellar bone pressure on the femoral trochlea could interfere with the formation and maintenance of an adequate trochlear groove and further increase the likelihood of developing MPL.<sup>7</sup> Our study showed the normal VTT:TPL ratio to range from 0.93 to 1.01 (95% CI). Therefore, VTT:TPL values <0.93 could indicate a pathologic configuration characterized by a too proximal relative position of the patellar ligament insertion.

Standardized correctly positioned mediolateral radiographs enabled both ratios to be accurately and quickly obtained. This makes the whole procedure simple and reproducible in a standard clinical environment. As we used ratios for our assessment, measurements were independent of the size of the dog or the magnification of the radiographic image.<sup>25</sup> An earlier study showed PLL:PL ratios were independent of flexion angle of the stifle.<sup>26</sup> A limitation of our study was the static radiographical assessment of MPL, whereas patellar luxation is a dynamic process. The position of the patella in the trochlear groove depends on extension and flexion angles of the stifle and is therefore dynamic in nature. Assessing the position of the patella in the trochlear groove on caudocranial or craniocaudal radiographic projections is therefore also subject to clear bias as standardization of the extension angle is merely impossible. These measurements will not reflect the true dynamic position of the patella. An additional limitation was that we did not assess conformational changes of the trochlea. To overcome the limitations of our static imaging techniques, including radiography and CT, the problem of true patellar position during movement can only be visualized with fluoroscopy on a treadmill. In addition, the study is limited by the retrospective nature. Recorded medical data rely on completeness and accuracy when documenting clinical information. Moreover, orthopedic examination and MPL grading depend on experience and are subjective. Another limitation could be the number of dogs and stifle joints used in this study. A larger number of animals could result in a more accurate analysis. Using only one certain breed with and without MPL could also show whether there are breed-specific differences. Although outside the scope of the present study, it would be interesting to assess the VTT:TPL ratio in small-breed dogs with grade 3 and 4 MPL. Whether the proximal shift of the patellar ligament insertion plays a role in the development of MPL or is a result of MPL has to be determined.

In conclusion, our study showed a more proximal position of the insertion of the patellar ligament on the tibial tuberosity in small-breed dogs with grade II MPL. This may result in a more proximal position of the patella

in the trochlear groove and contribute to the development of MPL. Potentially, this will also affect the risk of recurrence of MPL after surgical treatment.

## CONFLICT OF INTEREST

The authors declare no conflicts of interest related to this study.

## AUTHORS CONTRIBUTION

Liene Feldmane: participated in the design of the study; collected the medical data and radiologic images; participated in the development of the measurement technique, performed the statistical analysis and interpretation of the results; drafted the manuscript. Lars F.H. Theyse: developed the concept of the study, participated in the design of the study and the development of the measurement technique; revised the results of the study; revised the drafted manuscript. Both authors read and approved the final manuscript.

## REFERENCES

1. Alam MR, Lee JI, Kang HS, et al. Frequency and distribution of patellar luxation in dogs. *Vet Comp Orthop Traumatol*. 2007; 20(1):59-64.
2. Ramírez-Flores GI, Del Angel-Caraza J, Quijano-Hernández IA, Hulse DA, Beale BS, Victoria-Mora JM. Correlation between osteoarthritic changes in the stifle joint in dogs and the results of orthopedic, radiographic, ultrasonographic and arthroscopic examinations. *Vet Res Commun*. 2017;41(2): 129-137.
3. Wangdee C, Theyse LFH, Techakumphu M, Soontornvipart K, Hazewinkel HAW. Evaluation of surgical treatment of medial patellar luxation in Pomeranian dogs. *Vet Comp Orthop Traumatol*. 2013;26(06):435-439.
4. LaFond E, Breur GJ, Austin CC. Breed susceptibility for developmental orthopedic diseases in dogs. *J Am Anim Hosp Assoc*. 2002;38(5):467-477.
5. Wangdee C, Leegwater PAJ, Heuven HCM, van Steenbeek FG, Techakumphu M, Hazewinkel HAW. Population genetic analysis and genome-wide association study of patellar luxation in a Thai population of Pomeranian dogs. *Res Vet Sci*. 2017;111:9-13.
6. Bound N, Zakai D, Butterworth SJ, Pead M. The prevalence of canine patellar luxation in three centres clinical features and radiographic evidence of limb deviation. *Vet Comp Orthop Traumatol*. 2009;22(1):32-37.
7. Mostafa AA, Griffon DJ, Thomas MW, Constable PD. Proximodistal alignment of the canine patella: radiographic evaluation and association with medial and lateral patellar luxation. *Vet Surg*. 2008;37(3):201-211.
8. Arthurs GI, Langley-Hobbs SJ. Complications associated with corrective surgery for patellar luxation in 109 dogs. *Vet Surg*. 2006;35(6):559-566.
9. Campbell CA, Horstman CL, Mason DR, Evans RB. Severity of patellar luxation and frequency of concomitant cranial cruciate ligament rupture in dogs: 162 cases (2004–2007). *J Am Vet Med Assoc*. 2010;236(8):887-891.

10. Cashmore RG, Havlicek M, Perkins NR, et al. Major complications and risk factors associated with surgical correction of congenital medial patellar luxation in 124 dogs. *Vet Comp Orthop Traumatol.* 2014;27(04):263-270.
11. Daems R, Janssens LA, Béosier YM. Grossly apparent cartilage erosion of the patellar articular surface in dogs with congenital medial patellar luxation. *Vet Comp Orthop Traumatol.* 2009;22(03):222-224.
12. Towle HA, Griffon DJ, Thomas MW, Siegel AM, Dunning D, Johnson A. Pre- and postoperative radiographic and computed tomographic evaluation of dogs with medial patellar luxation. *Vet Surg.* 2005;34(3):265-272.
13. Mortari AC, Rahal SC, Vulcano LC, da Silva VC, Reinaldo SV. Use of radiographic measurements in the evaluation of dogs with medial patellar luxation. *Can Vet J.* 2009;50(10):1064-1068.
14. Gallegos J, Unis M, Roush JK, Agulian L. Postoperative complications and short-term outcome following single-session bilateral corrective surgery for medial patellar luxation in dogs weighing <15 kg: 50 cases (2009-2014). *Vet Surg.* 2016;45(7):887-892.
15. Linney WR, Hammer DL, Shott S. Surgical treatment of medial patellar luxation without femoral trochlear groove deepening procedures in dogs: 91 cases (1998-2009). *J Am Vet Med Assoc.* 2011;238(9):1168-1172.
16. Segal U, Or M, Shani J. Latero-distal transposition of the tibial crest in cases of medial patellar luxation with patella Alta. *Vet Comp Orthop Traumatol.* 2012;25(4):281-285.
17. Clerfond P, Huneault L, Dupuis J, Moreau M, Auger J. Unilateral or single-session bilateral surgery for correction of medial patellar luxation in small dogs: short and long-term outcomes. *Vet Comp Orthop Traumatol.* 2014;27(6):484-490.
18. Phetkaew T, Kalpravidh M, Penchome R, Wangdee C. A comparison of angular values of the pelvic limb with Normal and medial patellar luxation stifles in Chihuahua dogs using radiography and computed tomography. *Vet Comp Orthop Traumatol.* 2018;31(02):114-123.
19. Fitzpatrick CL, Krotscheck U, Thompson MS, Todhunter RJ, Zhang Z. Evaluation of tibial torsion in Yorkshire terriers with and without medial patellar luxation. *Vet Surg.* 2012;41(8):966-972.
20. Soparat C, Wangdee C, Chuthate S, Kalpravidh M. Radiographic measurement for femoral varus in Pomeranian dogs with and without medial patellar luxation. *Vet Comp Orthop Traumatol.* 2012;25(3):197-201.
21. Yasukawa S, Edamura K, Tanegashima K, et al. Evaluation of bone deformities of the femur, tibia, and patella in toy poodles with medial patellar luxation using computed tomography. *Vet Comp Orthop Traumatol.* 2016;29(1):29-38.
22. Singleton B. The surgical correction of stifle deformities in the dog. *J Small Anim Pract.* 1969;10(1964):59-69.
23. Newman M, Voss K. Computed tomographic evaluation of femoral and tibial conformation in English Staffordshire bull terriers with and without congenital medial patellar luxation. *Vet Comp Orthop Traumatol.* 2017;30(04):33-41.
24. Johnson AL, Broadus KD, Hauptman JG, Marsh S, Monsere J, Sepulveda G. Vertical patellar position in large-breed dogs with clinically normal stifles and large-breed dogs with medial patellar luxation. *Vet Surg.* 2006;35(1):78-81.
25. Johnson AL, Probst CW, DeCamp CE, Rosenstein DS, Hauptman JG, Kern TL. Vertical position of the patella in the stifle joint of clinically normal large-breed dogs. *Am J Vet Res.* 2002;63(1):42-46.
26. Wangdee C, Theyse LFH, Hazewinkel HAW. Proximo-distal patellar position in three small dog breeds with medial patellar luxation. *Vet Comp Orthop Traumatol.* 2015;28(4):270-273.
27. Wangdee C, Hazewinkel HAW, Temwichitr J, Theyse LFH. Extended proximal trochleoplasty for the correction of bidirectional patellar luxation in seven Pomeranian dogs. *J Small Anim Pract.* 2015;56(2):130-133.
28. Willauer CC, Vasseur PB. Clinical results of surgical correction of medial luxation of the patella in dogs. *Vet Surg.* 1987;16(1):31-36.
29. Reif U, DeJardin LM, Probst CW, Decamp CE, Flo GL, Johnson AL. Influence of limb positioning and measurement method on the magnitude of the tibial plateau angle. *Vet Surg.* 2004;33(4):368-375.
30. Buirkle CL, Aulakh KS, Gines JA, Rademacher N, Liu CC, Barnes K. Effect of tibial rotation on the tibial plateau angle measurement in dogs: an ex vivo study. *Vet Surg.* 2019;48(3):408-416.
31. Grierson J, Sanders M, Guitan J, Pead M. Comparison of anatomical tibial plateau angle versus observer measurement from lateral radiographs in dogs. *Vet Comp Orthop Traumatol.* 2005;18(4):215-219.
32. Wilke VL, Conzemius MG, Michael F, Evans RB, Ritter M. Comparison of tibial plateau angle between clinically normal greyhounds and Labrador retrievers with 440 and without rupture of the cranial cruciate ligament. *J Am Vet Med Assoc.* 2002;221(10):1426-1429.

**How to cite this article:** Feldmane L, Theyse LFH. Proximodistal and caudocranial position of the insertion of the patellar ligament on the tibial tuberosity and patellar ligament length of normal stifles and stifles with grade II medial patellar luxation in small-breed dogs. *Veterinary Surgery.* 2021;50(5):1017-1022. <https://doi.org/10.1111/vsu.13661>