Hemiepiphysiodesis for the Correction of Distal Femoral Valgus in Growing Dogs

Luca Vezzoni[1] Ida Forzisi[2] Antonio Ferretti[3] Aldo Vezzoni[1]

[1] Surgical Department, Clinica Veterinaria Vezzoni, Cremona, Italy
[2] Surgical Department, Clinica Veterinaria Gina, Annicco, Cremona, Italy
[3] Surgical Department, Clinica Veterinaria Ferretti, Legnano, Italy

Address for correspondence Luca Vezzoni, DVM, DECVS, Cert SAOS, Clinica Veterinaria Vezzoni, Via Delle Vigne 190, Cremona 26100, Italy (e-mail: lucavezzoni@me.com).

Vet Comp Orthop Traumatol

Abstract

Objectives The aim of this study was to describe hemiepiphysiodesis for the treatment of distal femoral valgus in immature dogs and to evaluate its effect on the anatomical lateral distal femoral angle (aLDFA).

Methods Skeletally immature dogs with distal femoral valgus deformities that had undergone hemiepiphysiodesis between November 2012 and March 2020 at two private veterinary practices were included. Criteria for inclusion in the study were a preoperative aLDFA below the previously published reference range (94 ± 3.3 degrees) and radiographs of the femur taken preoperatively and at growth plate closure.

Results A total of 11 dogs fulfilled the inclusion criteria, and a total of 17 limbs were treated. The mean aLDFA was 82.1 ± 3.2 degrees (range: 76–87 degrees) preoperatively and 93.1 ± 5 degrees (range: 76–99 degrees) at the final re-evaluation. The mean difference between the preoperative and final aLDFA was +11 degrees, which was significant. Undercorrection occurred in 2/17 cases, whereas overcorrection was not recorded. The implants were removed in 12/17 cases, and rebound growth occurred in 3 of these.

Clinical Significance Hemiepiphysiodesis for the treatment of distal femoral valgus is a technique that allows for increase in aLDFA and should be considered as an early treatment in affected immature dogs. Monitoring for possible overcorrection using serial radiography is important. Implant removal when the desired aLDFA has been achieved is recommended because the incidence of rebound growth is uncommon in dogs.

Keywords
- angular limb deformity
- hemiepiphysiodesis
- dog
- femoral valgus
- patellar luxation

Introduction

Angular limb deformities of the appendicular bones can lead to severe gait abnormalities in dogs, and the associated maldistribution of joint forces often results in lameness, pain and osteoarthritis. Angular limb deformities are the result of altered physeal development caused by an inherited condition or by trauma and other physeal disturbances.[1,2] Abnormal growth of the distal femoral physis manifests as either valgus or varus deviation of the limb distal to the deformity, which can alter alignment of the patellar and quadriceps mechanism with subsequent patellar luxation.[3–5] In particular, distal femoral valgus may be associated with lateral patellar luxation, osteochondritis dissecans of the lateral condyle or both, especially in large-breed dogs.[6–8]

Carl Hueter and Richard von Volkamann proposed an orthopaedic rule of bone growth called the 'Hueter–Volkamann Law', which states that compression forces inhibit growth and tensile forces stimulate growth.[9] Frost introduced a chondral modelling theory,[10] which stated that

received
March 2, 2021
accepted after revision
September 8, 2021

Georg Thieme Verlag KG,
Rüdigerstraße 14,
70469 Stuttgart, Germany

DOI https://doi.org/10.1055/s-0041-1736381.
ISSN 0932-0814.

physeal growth decreases with high compression loads but increases with moderate loads. Therefore, pathological compression of a portion of the physis can arrest bone growth in that portion leading to the development of angular limb deformities. Based on this principle, various hemiepiphysiodesis techniques used in human medicine are aimed at halting bone growth to allow gradual correction of bone deformities during residual growth.[11–14] In veterinary medicine, this principle has been used to correct angular limb deformities in foals, particularly metacarpal, radial, tibial and metatarsal deformities.[15,16] In 2016, hemiepiphysiodesis using staples or plates was described as an effective early treatment for proximal tibial valgus in 19 growing dogs; the study emphasized the importance of age at the time of surgery as well as regular reassessment.[17]

The use of medial distal hemiepiphysiodesis to treat valgus deformity of the distal femur in growing dogs was first described by Vaughan[5] and then by Denny,[18] but the results of this technique have never been reported. The purpose of this study was to describe the surgical technique for distal medial femoral hemiepiphysiodesis and to evaluate its effect on the anatomical lateral distal femoral angle (aLDFA).

Materials and Methods

The medical records of dogs that underwent medial distal femoral hemiepiphysiodesis for the correction of distal femoral valgus between November 2012 and March 2020 at Vezzoni Veterinary Clinic and Ferretti Veterinary Clinic were retrospectively evaluated. The following criteria had to be fulfilled for inclusion in the study: radiographic and clinical evaluation preoperatively and at growth plate closure; a preoperative aLDFA less than 94 degrees, based on the published reference range of 94 ± 3.3 degrees[19]; and the presence of abnormal gait attributable to valgus conformation of the distal femur (knock-knee deformity). Data retrieved included signalment, type of deformity, concurrent orthopaedic diseases, implants used for hemiepiphysiodesis, concomitant surgical procedures, subjective lameness grade before surgery and at final re-evaluation, aLDFA before surgery and at final re-evaluation, sagittal plane alignment before surgery and at final re-evaluation, time of implant removal if applicable, complications and subsequent surgical revision if required. Complications were considered major if there was a requirement for additional surgery or medical treatment. Minor complications included those not requiring additional surgery or medical treatment.

Preoperative Evaluation

A radiographic study was performed in all dogs, including craniocaudal and mediolateral views of the femurs to evaluate the alignment in the frontal plane and in the sagittal plane. The frontal plane alignment was evaluated as described for the measurement of aLDFA.[19] The sagittal plane alignment was evaluated measuring the centre of rotation of normal angulation ($CORONA_1$ and $CORONA_2$) as previously described.[20] All measurements were made by the same individual (LV).

Surgical Technique

All surgeries were performed by three of the authors (AV, LV, AF). Dogs were positioned in dorsal recumbency and the operation was performed using a standard medial approach to the stifle.[21] The extent of the surgical approach varied according to the need of concurrent procedures.

The caudal belly of the sartorius muscle was retracted caudally and the cranial belly of the sartorius muscle and the vastus medialis muscle was retracted cranially. A small gauge needle was used to mark the location of the femoral growth plate and the femorotibial joint, which was confirmed by fluoroscopy. Hemiepiphysiodesis was performed using a plate or one or two staples at surgeon's discretion.

For plate application (►**Fig. 1**), a 1.8 mm Kirschner wire was inserted in the medial femoral condyle in a mediolateral direction, approximately halfway between the growth plate and articular surface. Fluoroscopy was used to confirm proper insertion and positioning of the Kirschner wire. A 5-hole, 2.4 mm veterinary cuttable plate (Veterinary Instrumentation, Sheffield, United Kingdom) was contoured to match the medial surface of the femoral condyle. The Kirschner wire was removed, and the hole remaining in the femoral condyle was used to fix the plate by inserting a 2.4 mm screw in the most distal plate hole to engage the full width of the lateral femoral condyle. Plate orientation was evaluated via fluoroscopy, and a 2.4 mm monocortical screw was inserted in the most proximal plate hole, proximal to the growth plate line. The planned screw length was approximately half the mediolateral width of the distal femur.

For staple application (►**Fig. 2**), commercially available titanium staples (Kyon, Zurich, Switzerland), ranging from 10 to 16 mm in width, were used. The size of the staple chosen was determined by matching its width to the proximal-to-distal length of the epiphysis, measured from the joint line to the growth plate line. A 1.8 mm Kirschner wire was inserted in the femoral condyle as previously described, and a dedicated drill guide was secured to the bone over the Kirschner wire and aligned parallel to the long axis of the femur by fluoroscopic guidance. The proximal hole was then drilled with the 1.8 mm Kirschner wire proximal to the growth plate line. The staple was inserted into the holes and gently impacted with a dedicated impactor until fully seated. Depending on the surgeon's preference and the size of the dog, one or two staples were used with the second staple positioned ~5 mm cranial to the first.

When lateral patellar luxation was present, medial reticular imbrication or a combination of reticular imbrication and block trochleoplasty was performed. Osteochondral autografting was done in cases with osteochondritis dissecans of the lateral condyle (COR, Precision Targeting Cartilage Repair System, DePuy Synthes, Zuchwil, Switzerland). Wound closure was routine in all cases. Postoperative radiographs were obtained to confirm correct implant positioning. A modified Robert Jones bandage was applied for 24 hours and restriction of physical activity was recommended for 4 weeks. Skin suture removal was done 2 weeks postoperatively. After discharge, the dogs received amoxicillin/clavulanic acid (20 mg/kg per os, thrice daily)

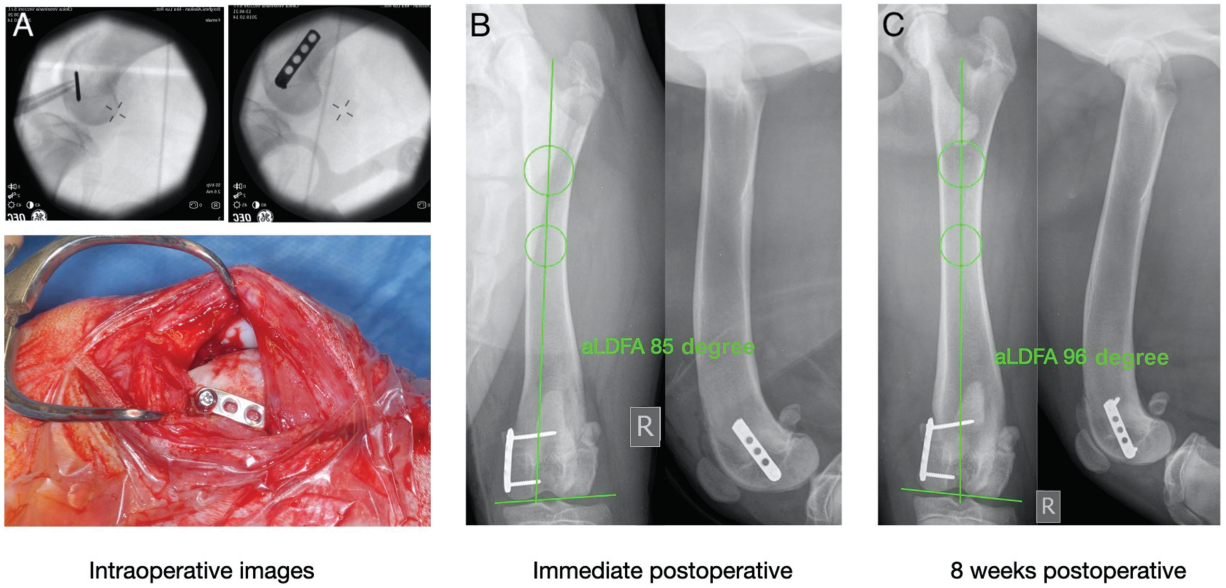

Fig. 1 Intraoperative images (**A**), immediate postoperative radiographs (**B**) and 8-week re-evaluation radiographs (**C**) after application of a 2.4 mm veterinary cuttable plate for distal femoral hemiepiphysiodesis in a 6 months old Cane Corso. aLDFA, anatomical lateral distal femoral angle.

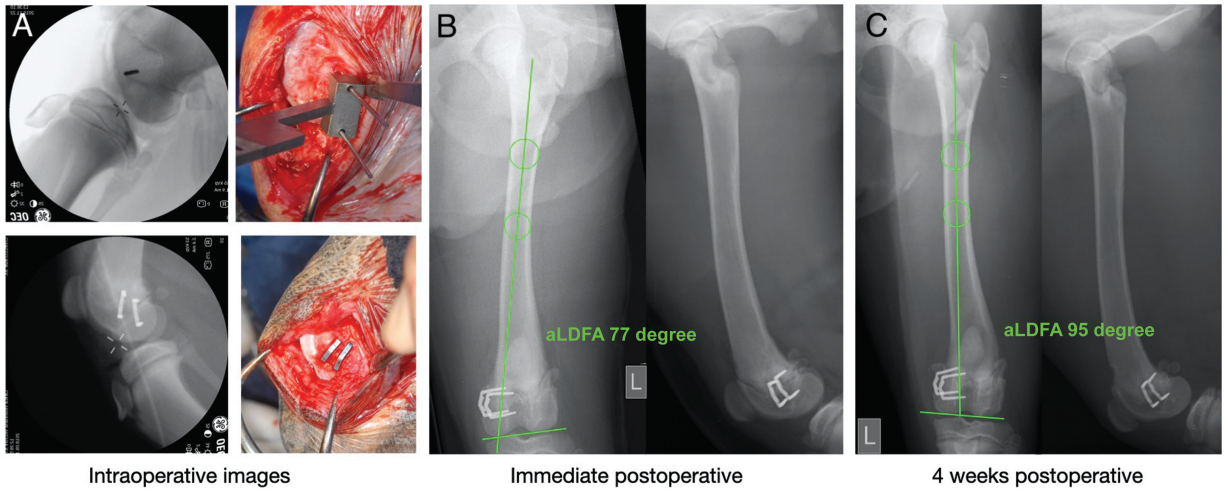

Fig. 2 Intraoperative images (**A**), immediate postoperative radiographs (**B**) and 4-week re-evaluation radiographs (**C**) after application of two 14 mm staples for distal femoral hemiepiphysiodesis in a 6 months old Maremmano Shepherd Dog. aLDFA, anatomical lateral distal femoral angle.

for 5 days and meloxicam (0.05 mg/kg per os, once daily) for 1 week and then on alternate days for another week.

Outcome Evaluation

Clinical and radiographic examinations were used to determine outcome. Clinical and radiographic examinations were done at varying time points based on clinical progression and the surgeon's preference. Radiographs were recommended every 2 weeks until 6 months of age and then monthly until correction was considered complete or the growth plate had closed. All clinical examinations were performed by the attending surgeon and included visual assessment of limb conformation. Subjective evaluation of lameness was used to determine clinical outcome using the following five-point scoring system: 1 = no lameness; 2 = mild intermittent weight-bearing lameness; 3 = persistent moderate weight-bearing lameness; 4 = persistent severe weight-bearing lameness, with or without intermittent non-weight bearing; and 5 = persistent non-weight-bearing lameness.

Statistical Analysis

Commercially available software was used for statistical analysis (SPSS 22: IBM Corp, Armonk, New York, United States). All the values were assessed for normality using Kolmogorov–Smirnov test; then a paired *t*-test was used to compare preoperative and final re-evaluation aLDFA and procurvatum CORONA angles. To evaluate the accuracy of correction of alignment, a student *t*-test was used to compare final aLDFA with the reference value of 94 degrees. In cases in which implants had been removed, a paired *t*-test was used

to compare aLDFA at time of implant removal and at final re-evaluation. A student *t*-test was used to compare the final correction obtained with the use of transphyseal plate versus staple. Statistical significance was set at $p \leq 0.05$.

Results

Medial hemiepiphysiodesis of the distal femur was performed in 17 dogs (24 femurs). A total of 11 dogs (17 limbs) fulfilled the inclusion criteria, while 6 (7 limbs) dogs were excluded because of a missing follow-up at growth plate closure (►**Appendix Table 1** [available online only]). Nine breeds were represented including the Pyrenean Mountain Dog ($n = 2$), Bernese Mountain Dog ($n = 2$) and one each of the following breeds: Akita Inu, Alaskan Malamute, Boxer, Cane Corso, Great Dane, Maremmano Shepherd Dog and Siberian Husky. All dogs were sexually intact at the time of surgery. Five of the 11 dogs were male and six were female. At the time of surgery, the dogs had a mean bodyweight of 21.3 kg (range: 11–42 kg) and had a mean age of 5.3 ± 0.8 months old (range: 3.8–6.7 months).

Six of the 11 dogs underwent bilateral hemiepiphysiodesis, which resulted in a total of 17 operated limbs. Two dogs underwent single-session bilateral surgery, while four underwent staged surgery with a mean time of 13.7 days (range: 6–21 days) between the two surgeries. Of the 17 hemiepiphysiodesis procedures performed, nine involved the left femur and eight the right.

Concurrent diagnoses included lateral patellar luxation in 12/17 limbs, which was grade 2 in three cases, grade 3 in five cases and grade 4 in four cases; proximal tibial valgus in 2/17 limbs and osteochondritis dissecans of the lateral femoral condyle in 1/17 limbs.

Hemiepiphysiodesis was achieved using staples in 10/17 limbs and plates in 7/17 limbs. The implants used for staple hemiepiphysiodesis included a single 10 mm staple ($n = 1$), a single 12 mm staple ($n = 1$), two 10 mm staples ($n = 2$), two 12 mm staples ($n = 1$), two 16 mm staples ($n = 4$) and a combination of one 12 mm staple and one 16 mm staple ($n = 1$).

Concurrent procedures at the time of hemiepiphysiodesis included a combination of medial reticular imbrication and block trochleoplasty ($n = 10$), medial reticular imbrication ($n = 2$), osteochondral autograft transfer for the treatment of a femoral osteochondritis dissecans lesion ($n = 1$) and proximal tibial medial hemiepiphysiodesis ($n = 2$).

The mean time to final re-evaluation was 18.5 ± 10.1 weeks (range: 9.2–47.7 weeks).

Preoperatively, the mean aLDFA was 82.1 ± 3.2 degrees (range: 76–87 degrees). The mean aLDFA at final re-evaluation was 93.1 ± 5 degrees (range: 76–99 degrees), which did not differ significantly from the reference value of normal femurs (94 degrees). The mean difference between preoperative and final aLDFA was $+11 \pm 4.4$ degrees. The increase in mean aLDFA was significant ($p = 0.00001$).

In particular, the mean aLDFA in dogs treated using staples was 81.3 ± 3.9 degrees preoperatively and 92.1 ± 6.2 at the time of final re-evaluation; the mean aLDFA in dogs treated using plate was 83.2 ± 1.3 preoperatively and 94.7 ± 2.2 at final re-evaluation. The mean difference between preoperative and final aLDFA was $+10.8$ degrees for staples and $+11.3$ degrees for plate; the average amount of correction did not differ between the two groups ($p = 0.21645$).

At the time of surgery, the mean value of $CORONA_1$ was 9.2 degrees (range: 6.5–13.6 degrees) and $CORONA_2$ was 61 degrees (range: 52.8–67.7 degrees). At the time of final re-evaluation, the mean value of $CORONA_1$ was 8.2 degrees (range: 5.3–11.9 degrees) and $CORONA_2$ was 59 degrees (range: 48.7–65 degrees). The mean difference between preoperative and final $CORONA_1$ was not significant ($p = 0.25947$); The mean difference between preoperative and final $CORONA_2$ was also not significant ($p = 0.37345$)

Implants were removed in 12/17 femurs a mean of 39 days (range: 26–64 days) postoperatively. The mean age of dogs at the time of implant removal was 6.6 months (range: 4.7–8.2 months). The mean aLDFA at the time of implant removal was 95.7 ± 2.0 degrees (range: 93–99 degrees), and the mean aLDFA at growth plate closure in those cases was 94.5 ± 2.33 (range: 92–99 degrees). The difference between these two aLDFA was not significant ($p = 0.49244$). The median preoperative lameness score was 3 (range: 2–4), and the score at the final re-evaluation was 1 (range: 1–3).

No intraoperative complications were recorded. Three minor and three major postoperative complications occurred in two dogs. The minor complications were related to rebound growth. The first case of rebound growth occurred in a Pyrenean Mountain Dog with a preoperative aLDFA of 82 degrees that was treated at 6.7 months of age. The dog underwent implant removal 44 days after surgery and had a postoperative aLDFA of 95 degrees, which had decreased to 92 degrees by the final radiographic re-evaluation. The second case was a 4.9-month-old Boxer with a preoperative aLDFA of 78 degrees. Implant removal was done 28 days after surgery when the dog had a postoperative aLDFA of 95 degrees. The angle had decreased to 92 degrees by the final radiographic re-evaluation. The third case was a Bernese Mountain Dog with an aLDFA of 85 degrees that was treated at 6.2 months of age. Implant removal was done 39 days after surgery when the dog had an aLDFA of 99 degrees; the angle had decreased to 93 degrees by the final radiographic re-evaluation.

Regarding major complications, the first case was a Pyrenean Mountain Dog with bilateral grade 4 lateral patellar luxation that had undergone bilateral hemiepiphysiodesis in staged operations together with medial retinacular imbrication and trochleoplasty. However, bilateral patellar luxation recurred and was revised in staged operations by means of patellar groove replacement at the time of growth plate closure. The second dog was an Akita Inu with unilateral grade 3 lateral patellar luxation in which medial retinacular imbrication was done together with hemiepiphysiodesis. However, patellar luxation recurred, and the dog underwent block trochleoplasty 28 days after the initial surgery together with implant removal.

Discussion

Even if the extent of surgical approach varies according to the need of concurrent procedures, such as trochleoplasty, hemiepiphysiodesis can be considered a minimally invasive surgery for the correction of limb deformities in growing animals to potentially eliminate the need for more invasive corrective osteotomy in adulthood.

This technique was effective for treating growing dogs with valgus deformity of the distal femur. The final median aLDFA was 93.1 degrees, which was close to the reference value of 94 degrees, which was the lowest mean aLDFA for one breed, German Shepherd Dog, in a study of four different breeds.[19] We chose the aLDFA of German Shepherd Dogs as a reference rather than the mean value of the four breeds of 97 degrees reported by Tomlinson and colleagues[19] because all dogs in our study were morphologically closer to this breed rather than the other breeds reported in that study. Sagittal plane alignment was not significatively altered by the medial hemiepiphysiodesis, respecting the pre-existing procurvatum of the femurs.

The age of the animal at the time of hemiepiphysiodesis influences the success of the procedure. Residual growth is one of the most important factors to consider when performing hemiepiphysiodesis and can result in undercorrection, overcorrection or rebound growth. Rebound growth is the recurrence of the deformity after implant removal necessitating further surgery and is not well described in veterinary medicine.[12] Predisposing factors of rebound growth in human medicine include implant removal at a young age, a correction of 5 to 10 degrees and large initial deformity.[22] Growth after implant removal in humans is unpredictable and varies greatly in frequency and extent.[22] Hence, serial radiographs are recommended to determine the best time for implant removal. Overcorrection of the deformity by 5 degrees has been suggested as a solution to rebound growth,[23] but the risk of iatrogenic deformity must be considered should rebound growth not occur. The average age of the dogs at the time of surgery in the present study was 5.3 months. Closure of the distal femoral physis occurs between 8 and 11 months of age. Thus, residual growth would be expected to be much lower in dogs than in humans, decreasing the risk of overcorrection or rebound growth in dogs.

Implants were removed in 12/17 of our cases once femoral alignment was determined to be satisfactory and before growth plate closure. Of those 12 cases, only three had rebound growth, while the aLDFA in all others remained unchanged after implant removal. Two cases had 3 degrees of rebound growth, which may partially have been related to intraobserver variability in measurements. However, the other case had 6 degrees of rebound growth, which was less likely attributable to measurement variability.

The time of implant removal once proper femoral alignment was achieved varied from 26 to 64 days with an average of 39 days postoperatively, highlighting the speed at which correction occurred and the importance of monitoring the correction. Interestingly, progression of the correction after implant removal did not occur in any of our cases, suggesting that temporary cessation of growth in the medial portion of the physis did not lead to premature closure. Overcorrection is a potential complication that can be prevented with serial monitoring to identify optimal timing for implant removal. In our study, significant overcorrection was not recorded, and only three cases had a final aLDFA over the reference value. Therefore, implant removal once the desired aLDFA has been obtained can be recommended in dogs because of the low incidence of rebound growth or overcorrection.

Growth dynamics of the distal femur have not yet been evaluated, but a previous study on growth dynamics focusing of the proximal tibia showed that the average monthly growth rate was greatest between the 4th and 5th month and decreased steadily until the 13th month; thus, one can argue a similar effect of age on femoral growth and that dogs older than 6 months with severe valgus may not benefit from hemiepiphysiodesis because residual growth is not sufficient.[24] Breed variations may also affect the residual growth potential, with smaller breeds achieving skeletal maturity at an earlier age. Undercorrection occurred in 2/17 of our cases, in which the correction was 0 and 3 degrees (mean change in aLDFA of all dogs 11 degrees), leading to final aLDFA of 76 and 90 degrees (►**Fig. 3**). The first case was a Siberian Husky treated at 5.9 month of age and the second case was a Pyrenean Mountain Dog treated at 5.5 months of age. Both cases had undergone bilateral hemiepiphysiodesis and the contralateral limbs achieved a final correction of 9 and 10 degrees. This suggested that undercorrection was not related to insufficient residual growth but rather to suboptimal implant positioning across the growth plate. Hemiepiphysiodesis can be accomplished by means of staples or plates. In 1949, Blount and Clarke described a hemiepiphysiodesis method using staples, and in 2007, Stevens described a technique using a commercially available two-hole plate with two screws and a central small hole for temporary insertion of a Kirschner wire in the growth plate (8-plate).[12,25] Unlike staples, a plate does not compress the physis and the screws have greater purchase in the bone. Staples were shown to act as an immediate brake by inhibiting much of the peripheral growth, whereas plates were determined to have a latency period before acting as a fulcrum, depending on the intrinsic elasticity of the system.[14]

An alternative to the 8-plate is a reconstruction plate with cortical screws. No difference was noted between the two types of plates in terms of their efficacy in correction of angular limb deformities.[26] Compared with the 8-plate, the reconstruction plate is available in different lengths and can therefore be customized to the size of the dog. In our opinion, implant length is an important consideration that cannot always be addressed by the use of staples, particularly those available commercially. Interestingly, in one of our cases, a small staple (12 mm) was used on the side where undercorrection occurred, and a larger staple was used on the contralateral side (16 mm) in which the final aLDFA was good. The smaller staple length may have been positioned incorrectly across the growth plate. The largest commercially

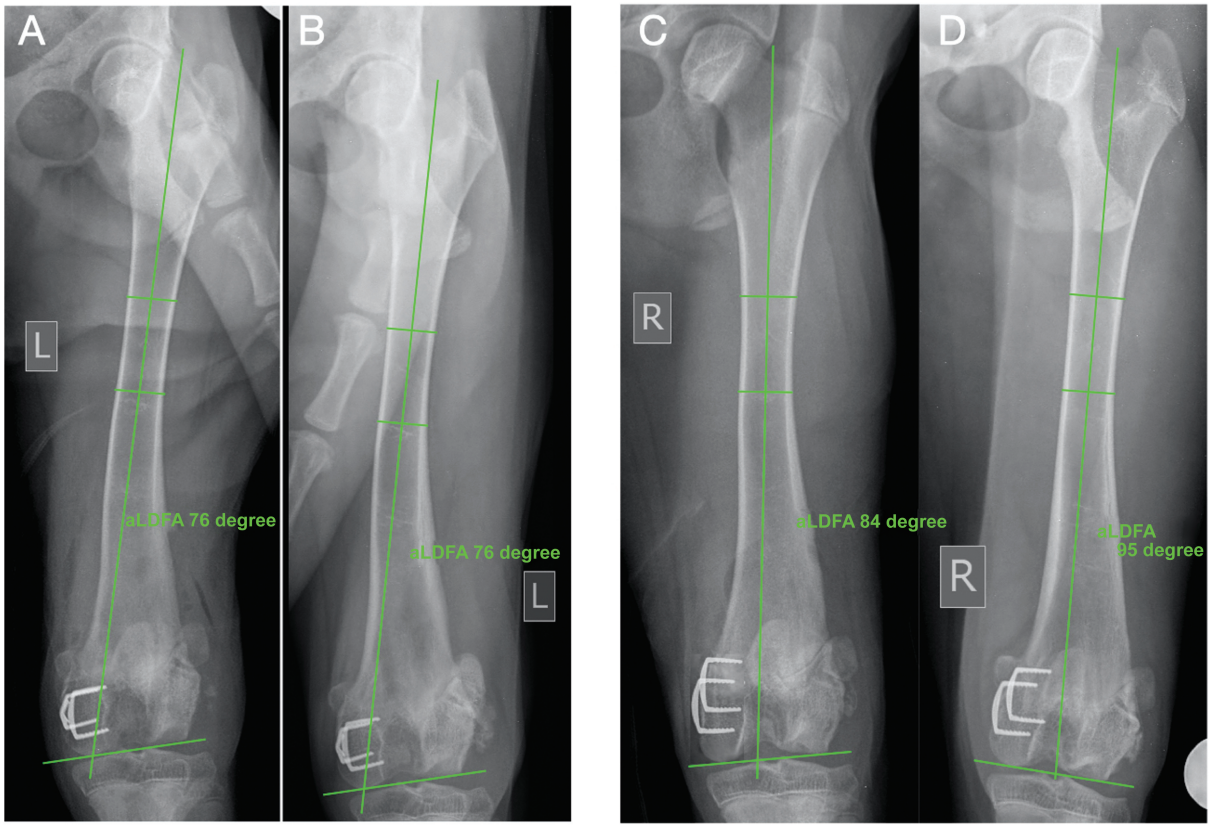

Fig. 3 Radiographic images of case 9 and 10, respectively; left and right femurs obtained of a 5.5 months old Pyrenean Mountain Dog: immediately after surgery postoperative radiographs (**A**, **C**) and recheck at growth plate closure (**B**, **D**) showing a lack of correction in the left femur and achievement of a good alignment of the right femur and lack of correction on the left femur in a 5.5-month-old Pyrenean Mountain Dog that underwent distal femoral hemiepiphysiodesis using staples. aLDFA, anatomical lateral distal femoral angle.

available staple used in our study was 16 mm, and because of the W shape of the distal femoral growth plate, correct positioning of this staple across the physis was more difficult in giant dogs. Although one solution would have been to use larger customized staples made of Kirschner wire, we felt that it was easier to use commercially available veterinary cuttable plates and cut them to the desired length. Another advantage of using cuttable plates is that they adhere tightly to the bone, which reduces the risk of loosening and extrusion. The bone holding power of cuttable plates has been demonstrated in human medicine, where this property is of great importance because corrections may take several months to years.[13] In our study, hemiepiphysiodesis was done with staples in 10/17 femurs and plates in 7/17 femurs; the low number of cases did not allow statistical evaluation, but the average correction was similar in both groups (staples: 10.8 degrees, plates: 11.3 degrees). Our results suggest that both techniques are equally effective for hemiepiphysiodesis, which is in agreement with studies in human medicine.[14,26,27] However, both our cases of undercorrection involved the use of staples and thus proper implant positioning may be easier when using a plate. Based on subjective evaluation of the ease of application, we consider the use of a bone plate our first choice when performing distal femur hemiepiphysiodesis. Fluoroscopic guidance is also recommended for achieving proper implant positioning.

Lateral patellar luxation was diagnosed in 12/17 limbs, and recurrence of luxation occurred in three. Distal femoral valgus is considered a predisposing factor for lateral patellar luxation. Restoration of femoral alignment with hemiepiphysiodesis is progressive, and thus early stabilization of the patella is important, particularly in grade 3 and 4 patellar luxation.[7] In the dog with bilateral recurrence of patellar luxation, femoral alignment was satisfactory in one femur but severe valgus deformity was still present in the contralateral limb. We, therefore, presumed that the cause of patellar luxation was associated with inadequate depth of the trochlear groove after trochleoplasty. Revision surgery was done to implant a trochlear groove prosthesis with the goal of compensating for the residual valgus by turning the prosthesis in varus orientation. The third case of patellar luxation had not undergone deepening of the trochlear groove at the initial surgery and was revised with block trochleoplasty.

Several different osteotomy techniques using various implants have been described for treatment of angular deformities of the femur, but it is a demanding surgical procedure that requires internal or external fixation and limited postoperative loading.[28–31] Corrective osteotomy is the gold standard in adult animals. Until recently, there were few studies on the early treatment of angular deformities in growing dogs. Distal femoral corrective osteotomy has been reported in growing dogs as an effective method of restoring

bone alignment, but is considered invasive and demanding.[28,32] The advantages of hemiepiphysiodesis in growing dogs include the less invasive nature of the surgery, low morbidity, less-demanding postoperative care and early return to normal limb function. This surgical technique proved to be safe and had no intraoperative complications. The three major postoperative complications were not strictly related to the hemiepiphysiodesis procedure per se. The technique allowed for a significant increase in aLDFA and should be considered as an early treatment of distal femoral deformities in immature dogs.

Author Contributions

Luca Vezzoni contributed to the study conception, study design, acquisition of data, data analysis and interpretation, drafting or revising of the manuscript, approval the submitted manuscript and is publicly accountable for relevant content. Antonio Ferretti and Aldo Vezzoni contributed to the study conception, study design, data analysis and interpretation, drafting or revising of the manuscript, approval the submitted manuscript and is publicly accountable for relevant content. Ida Forzisi contributed to the acquisition of data, data analysis and interpretation, drafting or revising of the manuscript, approval the submitted manuscript and is publicly accountable for relevant content.

Funding

None.

Conflict of Interest

None declared.

References

1 Piermattei D, Flo GL, DeCamp C. Brinker, Piermattei and Flo's Handbook of Small Animal Orthopedics and Fracture Repair. Correction of Abnormal Bone Growth and Healing. 4th edition. St. Louis: Saunders Elsevier; 2006:747–770
2 Ramadan RO, Vaughan LC. Disturbance in the growth of the tibia and femur in dogs. Vet Rec 1979;104(19):433–435
3 Paley D. Principles of Deformity Correction. 1st edition. Berlin, Germany: Springer-Verlag; 2003
4 Slocum B, Slocum TD. Patellar luxation algorithm. In: Bojrab M, ed. Current Techniques in Small Animal Surgery. 4th edition. Baltimore: The Williams & Wilkins Co; 1998:1222–1231
5 Vaughan LC. Growth plate defects in dogs. Vet Rec 1976;98(10): 185–189
6 Witte PG, Scott HW. Treatment of lateral patellar luxation in a dog by femoral opening wedge osteotomy using an interlocking nail. Vet Rec 2011;168(09):243
7 Kalff S, Butterworth SJ, Miller A, Keeley B, Baines S, McKee WM. Lateral patellar luxation in dogs: a retrospective study of 65 dogs. Vet Comp Orthop Traumatol 2014;27(02):130–134
8 Shaver SL, Mayhew KN, Sutton JS, et al. Complications after corrective surgery for lateral patellar luxation in dogs: 36 cases (2000-2011). J Am Vet Med Assoc 2014;244(04):444–448
9 Mehlman CT, Araghi A, Roy DR. Hyphenated history: the Hueter-Volkmann law. Am J Orthop 1997;26(11):798–800
10 Frost HM. A chondral modeling theory. Calcif Tissue Int 1979;28 (03):181–200
11 Bowen JR, Leahey JL, Zhang ZH, MacEwen GD. Partial epiphysiodesis at the knee to correct angular deformity. Clin Orthop Relat Res 1985;(198):184–190
12 Stevens PM. Guided growth for angular correction: a preliminary series using a tension band plate. J Pediatr Orthop 2007;27(03): 253–259
13 Burghardt RD, Herzenberg JE, Standard SC, Paley D. Temporary hemiepiphyseal arrest using a screw and plate device to treat knee and ankle deformities in children: a preliminary report. J Child Orthop 2008;2(03):187–197
14 Goyeneche RA, Primomo CE, Lambert N, Miscione H. Correction of bone angular deformities: experimental analysis of staples versus 8-plate. J Pediatr Orthop 2009;29(07):736–740
15 Witte S, Hunt R. A review of angular limb deformities. Equine Vet Educ 2009;21:378–387
16 Fretz PB, Turner AS, Pharr J. Retrospective comparison of two surgical techniques for correction of angular deformities in foals. J Am Vet Med Assoc 1978;172(03):281–286
17 Olsen AM, Vezzoni L, Ferretti A, Palmer RH, Vezzoni A, Duerr F. Hemiepiphysiodesis for the correction of proximal tibial valgus in growing dogs. Vet Comp Orthop Traumatol 2016;29(04):330–337
18 Denny HR. A Guide to Canine and Feline Orthopaedic Surgery. 3th edition. Oxford: Blackwell Scientific Publications; 1993:344–345
19 Tomlinson J, Fox D, Cook JL, Keller GG. Measurement of femoral angles in four dog breeds. Vet Surg 2007;36(06):593–598
20 Peterson JL, Torres BT, Hutcheson KD, Fox DB. Radiographic determination of normal canine femoral alignment in the sagittal plane: a cadaveric pilot study. Vet Surg 2020;49(06):1230–1238
21 Johnson KA. Piermattei's Atlas of Surgical Approaches to the Bones and Joints of the Dog and Cat. 5th edition. St. Louis: Elsevier Saunders; 2013:396–399
22 Leveille LA, Razi O, Johnston CE. Rebound deformity after growth modulation in patients with coronal plane angular deformities about the knee: who gets it and how much? J Pediatr Orthop 2017
23 Zuege RC, Kempken TG, Blount WP. Epiphyseal stapling for angular deformity at the knee. J Bone Joint Surg Am 1979;61(03):320–329
24 McBrien CS Jr, Vezzoni A, Conzemius MG. Growth dynamics of the canine proximal tibial physis. Vet Surg 2011;40(04):389–394
25 Blount WP, Clarke GR. Control of bone growth by epiphyseal stapling; a preliminary report. J Bone Joint Surg Am 1949;31A (03):464–478
26 Park KH, Oh CW, Kim JW, Park IH, Kim HJ, Choi YS. Angular deformity correction by guided growth in growing children: eight-plate versus 3.5-mm reconstruction plate. J Orthop Sci 2017;22(05):919–923
27 Kumar A, Gaba S, Sud A, Mandlecha P, Goel L, Nayak M. Comparative study between staples and eight plate in the management of coronal plane deformities of the knee in skeletally immature children. J Child Orthop 2016;10(05):429–437
28 Brower BE, Kowaleski MP, Peruski AM, et al. Distal femoral lateral closing wedge osteotomy as a component of comprehensive treatment of medial patellar luxation and distal femoral varus in dogs. Vet Comp Orthop Traumatol 2017;30(01):20–27
29 DeTora MD, Boudrieau RJ. Complex angular and torsional deformities (distal femoral malunions). Preoperative planning using stereolithography and surgical correction with locking plate fixation in four dogs. Vet Comp Orthop Traumatol 2016;29(05):416–425
30 Swiderski JK, Palmer RH. Long-term outcome of distal femoral osteotomy for treatment of combined distal femoral varus and medial patellar luxation: 12 cases (1999-2004). J Am Vet Med Assoc 2007;231(07):1070–1075
31 Panichi E, Cappellari F, Olimpo M, et al. Distal femoral osteotomy using a novel deformity reduction device. Vet Comp Orthop Traumatol 2016;29(05):426–432
32 Petazzoni M, Palmer RH. Femoral angular correction and lengthening in a large-breed puppy using a dynamic unilateral external fixator. Vet Surg 2012;41(04):507–514

