BSAVA
JSAP JOURNAL OF SMALL ANIMAL PRACTICE

ORIGINAL ARTICLE

Epicondylar plate fixation of humeral condylar fractures in immature French bulldogs: 45 cases (2014-2020)

E. Kvale[1,*,‡], I. Kalmukov*, L. Grassato*, S. Kalff† and M. Solano*

*Fitzpatrick Referrals, Godalming, UK
†Pacific and Santa Cruz Veterinary Specialists, Santa Cruz, CA, USA
‡Fredrikstad Dyrehospital, Wilbergjorde 2, 1605 Fredrikstad, Norway

[1]Corresponding author email: eirik@f-d.no

Objectives: The objective of this study was to report outcome and postoperative complications following stabilisation of humeral condylar fractures in skeletally immature French bulldogs with a transcondylar screw combined with locking or hybrid locking plates.

Materials and Methods: Medical records from one referral hospital were reviewed to identify skeletally immature French bulldogs with humeral condylar fractures treated with a transcondylar screw and epicondylar locking or hybrid locking plates crossing the distal humeral physis.

Results: Forty-five fractures in 41 different dogs with a mean age of 4 months (range 3.5 to 5) were identified. Six cases had complications: two (4.4%) minor and four (8.9%) major. Short-term clinical outcome was excellent in 35 (77.8%), good in nine (20%) and poor in one (2.2%) case. Forty-one of 45 fractures reached radiographic union without further surgical intervention; the remaining four cases reached union following revision surgery. Long-term owner assessed outcome by telephone interview was graded as excellent in all available cases (26 of 41 dogs).

Clinical Significance: This study suggests that the stabilisation of humeral condylar fractures in skeletally immature French bulldogs with combinations of a transcondylar screw and epicondylar locking or hybrid locking plates crossing the distal humeral physis was safe and led comparable outcomes and complication rates to previous reports.

Journal of Small Animal Practice (2022), 1–10
DOI: 10.1111/jsap.13484

Accepted: 18 January 2022

INTRODUCTION

Humeral condylar fractures in dogs account for 41% of fractures of the humerus and are classified as lateral, medial or bicondylar (T-Y or intracondylar) (Bardet *et al.* 1983, Denny 1983). Lateral condylar fractures are the most common, accounting for 56 to 67% of reported cases, followed by bicondylar (26 to 35%) and medial (6.7 to 11%) (Bardet *et al.* 1983, Denny 1983, Rørvik 1993, Sanchez Villamil *et al.* 2020). The aetiopathogeneses of these fractures include trauma and humeral intracondylar fissure (HIF)/incomplete ossification of the humeral condyle (IOHC) (Marcellin-Little *et al.* 1994, Perry *et al.* 2015, Moores & Moores 2017, Smith *et al.* 2020). The French bulldog has been reported as a breed at risk of HIF/IOHC and is reportedly over-represented among dogs less than 12 months of age presenting with humeral condylar fractures (Smith *et al.* 2020, Franklin *et al.* 2021).

In adult dogs, rigid fixation of the condyle to the diaphysis with bone plate(s) is preferred in both unicondylar and bicondylar fractures (Perry *et al.* 2015, García *et al.* 2020, Sanchez Villamil *et al.* 2020). This has historically been advocated against in skeletally immature animals due to the risk of premature/asymmetrical physeal closure, and epicondylar pin fixation has been recommended to preserve the physis (Prieur 1989, Cook *et al.* 1999, Morgan *et al.* 2008, Cinti *et al.* 2017). The clinical significance of premature closure of the distal humeral physis is unclear, and a previous study found no evidence of reduced growth or humeral

deformity in immature dogs treated for lateral humeral condylar fractures with a transcondylar screw crossing the distal humeral physis (Lefebvre *et al.* 2008).

The objective of this study was to report outcome and postoperative complications following stabilisation of humeral condylar fractures in skeletally immature French bulldogs with a transcondylar screw combined with locking or hybrid locking plates (plates with combinations of locking and non-locking screws). Our hypothesis was that locking or hybrid locking plate fixation, with implants crossing the distal humeral physis, for management of humeral condylar fractures in skeletally immature French bulldogs is safe and results in good clinical outcomes and low postoperative complication rates.

MATERIALS AND METHODS

Inclusion criteria

Medical records from a single referral veterinary hospital were reviewed to identify skeletally immature French bulldogs undergoing open reduction and internal fixation (ORIF) of humeral condylar fractures. Skeletal immaturity was defined as the presence of an open distal humeral physis on preoperative radiographs. Only fractures treated with a transcondylar screw in combination with one or several locking bone plates, placed as locking or hybrid constructs with at least one screw engaging the distal epiphysis, were included in the study. Surgical technique, implant type and size and mode of transcondylar screw application were dependent on surgeon preference.

Medical record search and data extracted

Retrieved data from medical records included age, gender, weight, fracture configuration, size of plate and screws. Administration of postoperative antibiotics (type and duration), surgeon experience [European College of Veterinary Surgeons (ECVS)/Royal College of Veterinary Surgeons (RCVS) diplomat *versus* resident] and transcondylar screw mode (lag or positional under compression), diameter and material (surgical 316 L stainless steel *versus* titanium) were also recorded. The narrowest diameter of the humeral condyle (isthmus) between the joint surface and the supratrochlear foramen, the use of washers, construct type, number of screws in each fracture segment and radiographic evidence of a contralateral HIF at the time of fracture was recorded from preoperative and postoperative radiographs. Postoperative radiographs were also assessed for fracture reduction, and any intracondylar gaps/steps were recorded and measured.

Complications were defined as any undesirable outcome associated with the surgical procedure and classified as minor (no surgical intervention) or major (surgical intervention) as previously described (Perry *et al.* 2015). A surgical site infection was defined as superficial or deep as previously described (Turk *et al.* 2015). Details of the complications and treatments performed were recorded.

Short-term outcome was determined based on physical examination at the time of routine radiographic follow-up scheduled 4 to 6 weeks postoperatively and graded as excellent, good, fair or poor as previously described (Table 1) (Fox *et al.* 1995). Bone healing of the humeral condyle and supracondylar crest was assessed on orthogonal radiographs using a previously described classification system and defined as complete (groups 1 and 2) or incomplete (groups 3 to 5) (Hammer *et al.* 1985). Integrity of the construct, evidence of physeal closure and subjective evidence of condylar deformity were also noted.

Long-term follow-up

All identified cases were contacted for long-term follow-up by telephone at a minimum of 12 months postoperatively. The owners were asked to assess the dogs' function [catastrophic, poor, fair, good or excellent (Table 2)] based on the degree of lameness, perceived pain and ability to exercise, and invited for a long-term follow-up appointment. This included goniometric measurement of elbow range of motion, subjective gait assessment by a visual analogue scale (VAS) converted to a numeric score from 0 to 10, objective gait assessment using a pressure-sensing walkway (PSW) (StridewayTM; Tekscan Inc, South Boston, MA, USA) and completion of the Liverpool Osteoarthritis in Dogs (LOAD) questionnaire.

Surgery

All cases were premedicated with methadone hydrochloride (0.2 to 0.3 mg/kg Comfortan; Dechra, Shrewsbury, Shropshire, UK) alone or in combination with acepromazine maleate (0.01 to 0.02 mg/kg ACP; Elanco, Basingstoke, Hampshire, UK). General anaesthesia was induced with propofol (2 to 4 mg/kg Propoflo; Zoetis, Leatherhead, UK) and maintained with isoflurane (IsoFlo; Zoetis) in 100% oxygen. Cefuroxime (22 mg/kg Zinacef; GlaxoSmithKline, Middlesex, UK) was administered intravenously preoperatively within 30 minutes of first incision and repeated at 90-minute intervals throughout the procedure.

All fractures were stabilised by ORIF. Medial, lateral or bilateral approaches to the distal humerus were performed as required by the fracture configuration (Johnson 2014). In unicondylar fractures, the fractured part of the condyle was stabilised with a transcondylar screw before bone plates were placed (Figs 1 and 2). Transcondylar screws were either placed as lag screws or as positional screws after manual interfragmentary compression was applied. Temporary or permanent supracondylar Kirschner

Table 1. Clinical outcome assessed by orthopaedic surgeon

Outcome	Description
Excellent	No lameness and normal/near normal range of motion
Good	Mild lameness and normal/near normal range of motion
Fair	Moderate to severe lameness
Poor	Non-weight-bearing lameness

Table 2. Owner assessed long-term outcome

Outcome	Description
Excellent	No lameness and normal exercise level
Good	Mild lameness and normal/near normal exercise level
Fair	Moderate to severe lameness and/or exercise intolerance
Poor	Non-weight bearing lameness
Catastrophic	Amputation or euthanasia

wires were used at the surgeon's discretion to maintain reduction during plate application. In bicondylar fractures, bilateral stabilisation was performed according to fracture configuration as previously described (Fig 3) (García *et al*. 2020). Orthogonal radiographs were performed immediately postoperatively.

A modified Robert Jones bandage was applied and maintained for 24 to 48 hours. Postoperative antibiotics were administered at attending surgeons' discretion. Follow-up examination was scheduled 4 to 6 weeks postoperatively, with orthogonal radiographs of the affected humerus obtained under sedation at the same visit. Once evidence of osseous healing was noted, a gradual return to normal exercise over the following 4 weeks was advised.

RESULTS

A total of 41 dogs with 45 fractures were identified. Mean age at the time of surgery was 4 months (range 3.5 to 5 months) and mean weight was 7 kg (range 4 to 10 kg). Fifteen dogs were male and 26 were female, and all dogs were sexually entire. Thirty-five (76.1%) lateral, three (6.5%) medial and seven (15.2%) bicondylar fractures were identified. Preoperative orthogonal radiographs of both humeri were available in all cases. Two dogs suffered bilateral simultaneous fractures, and six dogs had evidence of a contralateral HIF at the time of fracture (Fig 4).

Twenty-three fractures were operated by an ECVS or RCVS diplomat and 22 were operated by a resident under direct supervision of a diplomat. Locking compression plate(s) (LCP) (Synthes, Oberdorf, Switzerland) were used in 42 fractures and VetLOX (Freelance Surgical, Sommerset, UK) plates in three cases. The plate and screw sizes used were 2.0 mm (n=46), 2.4 mm (n=3) or 2.7 mm (n=3). The mean number of screws in the proximal segment was 2 (range 1 to 3) and the mean number of screws in the distal segment was 2 (range 1 to 4). All plates had a minimum of one locking screw engaging the distal humeral epiphysis and all constructs were either all locked (n=13) or hybrid (n=39).

Forty-four transcondylar screws were made of 316 L stainless steel (43 cortical and one Synthes locking screw) and one was a VetLOX titanium locking screw. Seventeen were placed positional with the condyle compressed with point-to-point

FIG 1. Case 31, example of lateral humeral condylar fracture. (a, b) Preoperative radiographs showing lateral humeral condylar fracture. (c, d) Immediately postoperative radiographs showing fracture fixation with a transcondylar screw in combination with an epicondylar locking compression plate and a Kirschner wire. (e, f) Six weeks postoperative radiographs showing unchanged implants and osseous healing at the fracture sites

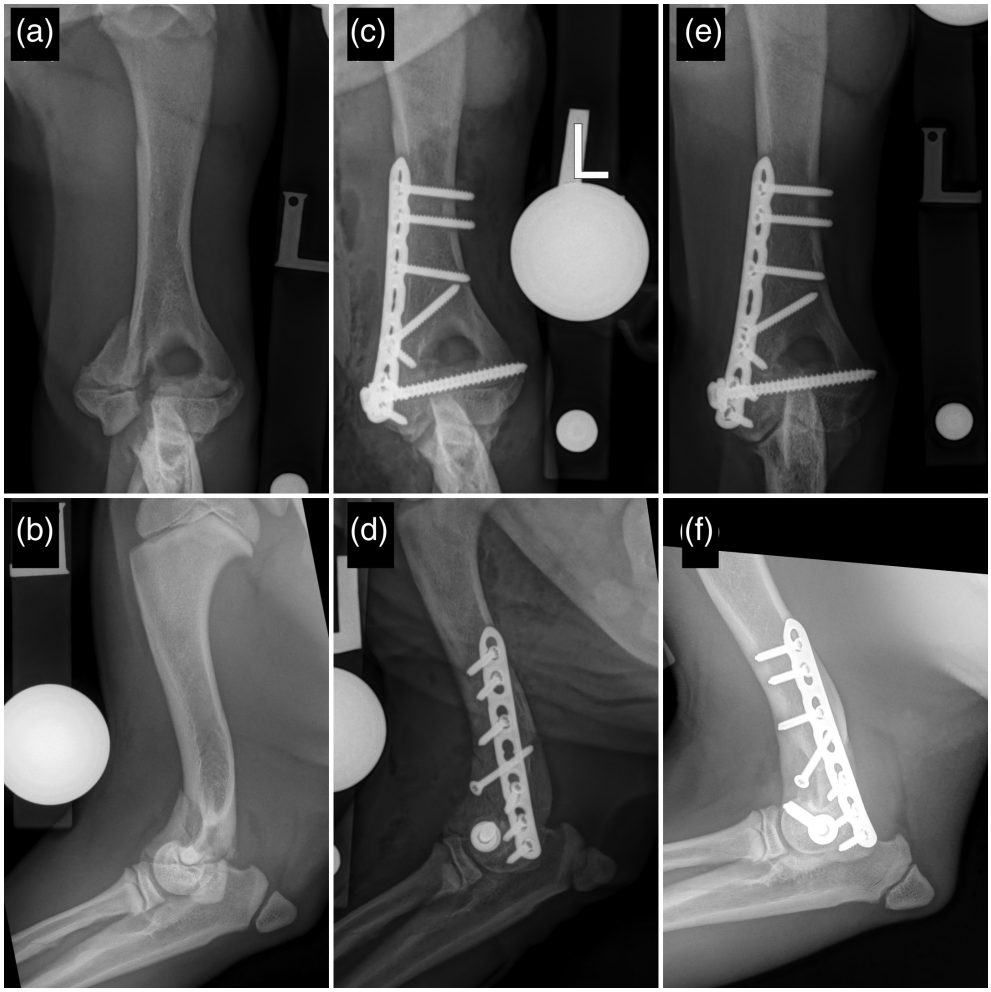

FIG 2. Case 27, example of medial humeral condylar fracture. (a, b) Preoperative radiographs showing a medial humeral condylar fracture. (c, d) Immediately postoperative radiographs showing fracture fixation with a transcondylar screw in combination with a locking compression plate and an interfragmentary lag screw. (e, f) Six weeks postoperative radiographs showing unchanged implants and osseous healing at the fracture sites

reduction forceps, 19 were placed in lag fashion and no information was available for nine fractures. A washer was used in 28 fractures. The diameters of the transcondylar screws were 2.0 mm (n=1), 2.4 mm (n=12), 2.7 mm (n=28) or 3.5 mm (n=4). The mean transcondylar screw diameter was 36% (range 25 to 47%) of the diameter of the isthmus of the humeral condyle.

Thirty-eight fractures were considered anatomically reconstructed. Three fractures had intracondylar gaps (range 1.7 to 2.6 mm), three had articular steps (range 0.6 to 0.8 mm), and one fracture had both an intracondylar gap (2.0 mm) and an articular step (0.5 mm). Of the cases with intracondylar steps and/or gaps, two fractures were lateral, two medial and three bicondylar. Two of these cases (both bicondylar) also had preoperative evidence of HIF.

Postoperative antibiotics were used in 11 of 43 surgeries for a median of 7 days (range 5 to 10). Cefalexin (20 mg/kg q12hr Therios; Ceva Animal Health, Amersham, UK) was used in 10 of 11 cases and amoxicillin–clavulanic acid (15 mg/kg q12hr Kesium; Ceva Animal Health, Amersham, UK) was used in one of 11 cases.

The short-term follow-up was available for all fractures at a mean of 5.6 weeks postoperatively (range 4 to 7 weeks). Clinical outcome was graded as excellent for 35 (77.8%) fractures, good for nine (20%) fractures and one dog had a poor short-term outcome. Forty-one of 45 fractures had reached radiographic union of both the humeral condyle and supracondylar crest at the short-term radiographic follow-up. Closure of the distal humeral physis was confirmed in all cases at that time and no evidence of condylar deformity was noted. The remaining four fractures all had major complications (Table 3); radiographic union was reached in these cases 6 to 14 weeks following revision surgery.

Postoperative complications occurred in six of 45 (13.3%) fractures (Table 3). Two fractures had minor complications, and four fractures had major complications requiring a total number of six revision surgeries. Case 32 (bilateral simultaneous lateral condylar fractures) suffered a fracture of the left medial supracondylar crest, caused by a surgical technical error (converging screws exiting the medial cortex close together creating a stress riser), on the day of the routine 6-weeks recheck. Stabilisation of the trochlea humeri to the humeral diaphysis with a 2.4-mm LCP was performed, recovery was uneventful and complete bone healing was confirmed 6 weeks later. The remaining three cases had loosening of the transcondylar screw. In case 36 (lateral condylar fracture),

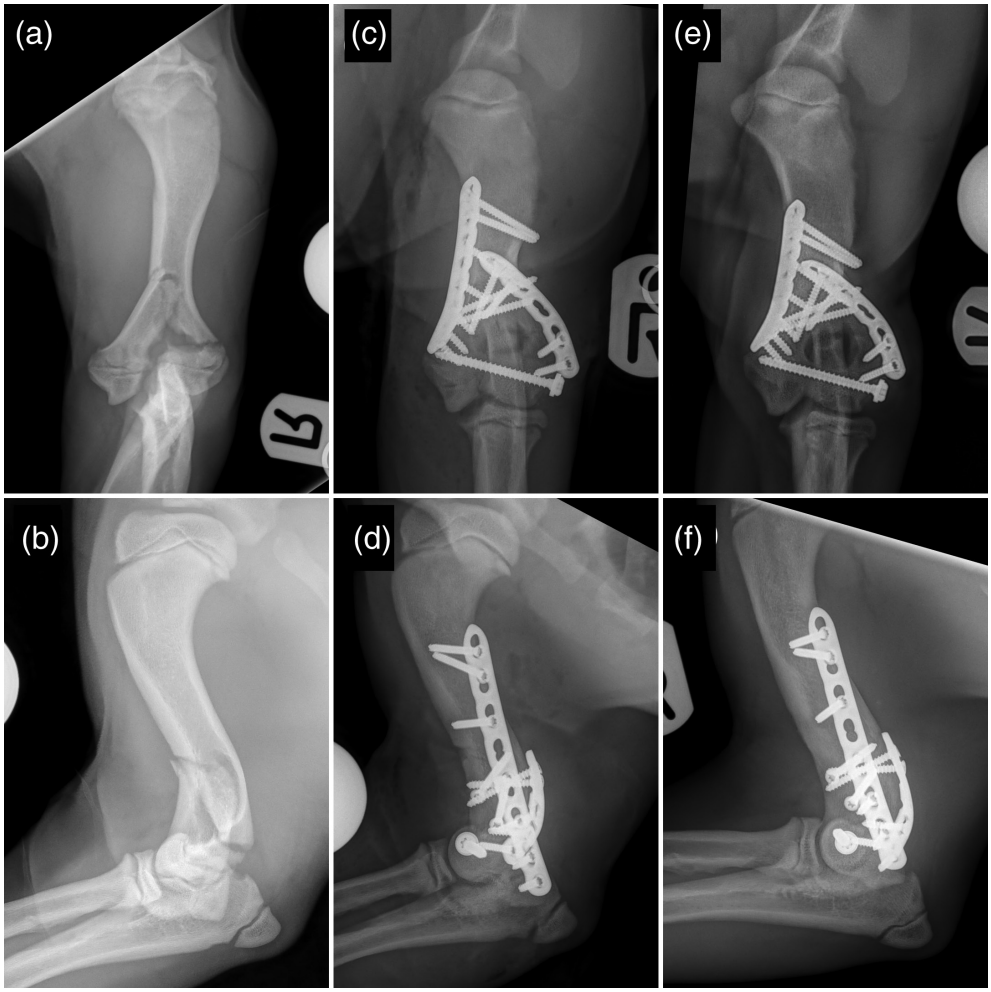

FIG 3. Case 34, example of bicondylar (T-Y) fracture. (a, b) Preoperative radiographs showing bicondylar humeral condylar fracture. (c, d) Immediately postoperative radiographs showing fracture fixation with a transcondylar screw in combination with two locking compression plates and two lag screws. (e, f) Six weeks postoperative radiographs showing unchanged implants and osseous healing at the fracture sites. Note the mild malreduction (small articular step) on the immediate postoperative radiograph (c). Also note that this is not evident on the 6-week follow-up radiograph (e)

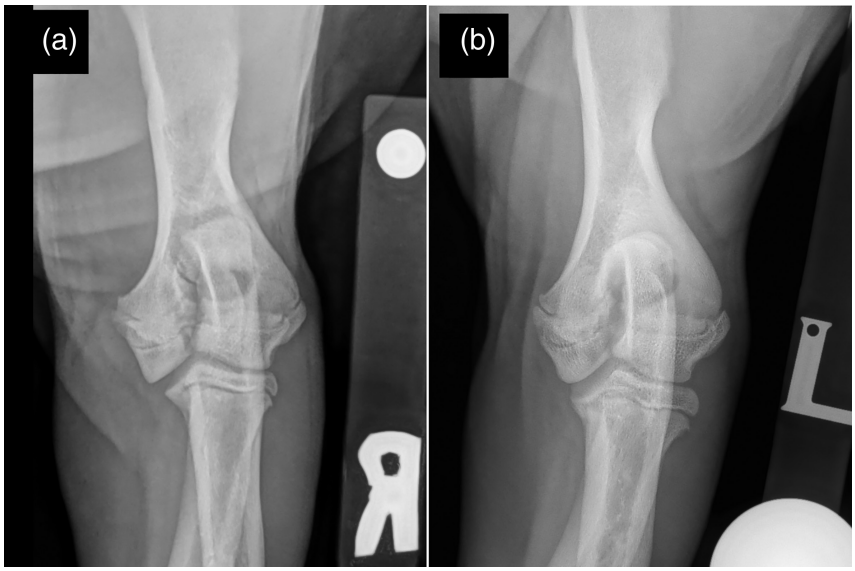

FIG 4. Case numbers 12 and 36 (a, b), examples of contralateral humeral intracondylar fissure at the time of surgery. Note the wide radiolucent line in the mid-sagittal plane of the humeral condyle in both cases

Table 3. Postoperative complications

Case	Gender	Bodyweight (kg)	Fracture configuration	Transcondylar screw material/ type/mode/size (mm)	Plate size (mm)/ type	Radiographic evidence of contralateral HIF	Contralateral fracture	Complication (weeks postoperatively)	Treatment (number of surgical interventions)	Weeks to complete healing after revision surgery	Clinical short-term outcome
28	Female	6	Lateral	Steel/cortical/ lag/2.7	2.0/LCP	Yes	Yes (7 days postoperative)	Minor: Transcondylar screw backed out (6)	No treatment (bone healing already complete)	N/A	Excellent
30	Female	6	Lateral	Steel/cortical/ lag/2.7	2.0/LCP	No	No	Minor: Superficial surgical site infection (*Staphylococcus pseudintermedius* cultured) (2)	Antibiotic therapy	N/A	Good
32	Female	6	Lateral	Steel/cortical/ lag/2.4	2.0/LCP	Simultaneous bilateral fracture	Yes (simultaneous)	Major: Medial condylar fracture (6)	ORIF (1)	6	Poor
36	Female	6	Lateral	Steel/cortical/ lag/2.4	2.0/LCP	No	No	Major: Transcondylar screw backed out (no information available of culture) (6)	Replaced with larger transcondylar screw followed by screw removal and bone grafting (2)	14	Excellent
38	Female	7	Lateral	Steel/cortical/ positional/2.7	2.0/LCP	No	No	Major: Transcondylar screw backed out (no bacterial growth) (4)	Bilateral epicondylar plate fixation and bone grafting (1)	6	Good
41	Male	7	Lateral	Steel/ cortical/not available/2.7	2.0/LCP	Yes	Yes (5 days postoperative)	Major: Transcondylar screw backed out (no bacterial growth) (4)	Replaced transcondylar screw followed by placement of transcondylar Webb bolt (2)	5	Good

HIF Humeral intracondylar fissure, LCP Locking Compression Plate, N/A Not applicable, ORIF Open reduction and internal fixation

the 2.7-mm transcondylar screw backed out 2 weeks postoperatively, and it was replaced with a 3.5-mm cortical stainless steel screw. Evidence of screw loosening was again found 3 weeks later. This was managed conservatively, and healing of the supracondylar crest without further intervention was confirmed 8 weeks after revision surgery. At that time, the transcondylar screw was removed and the transcondylar tunnel packed with autologous bone graft due to further screw displacement and widening of transcondylar tunnel. Osseous union across the humeral condyle was confirmed 6 weeks later. In case 38 (lateral condylar fracture), the transcondylar screw was found to be loose 5 weeks postoperatively and extensive dilation of the transcondylar tunnel was noted. No safe trajectory for a new transcondylar screw was found, and orthogonal epicondylar plating and autologous bone grafting of the transcondylar bone tunnel were performed. Bone healing across the condyle at the previous transcondylar tunnel and supracondylar crest was confirmed 6 weeks later. In case 41 (lateral condylar fracture), humeral condylar non-union and transcondylar screw loosening was found at the routine recheck 7 weeks postoperatively. Revision surgery was performed by placement of a 3.5-mm transcondylar screw. Screw loosening was again seen 7 days later, and another revision was performed with a 4.0-mm transcondylar Webb bolt in addition to a 2.7-mm transcondylar screw. Osseous union across the humeral condyle was confirmed at the last available follow-up 5 weeks later.

Owner-assessed long-term outcome was available for 29 of 45 fractures (26 dogs) by telephone conversation, a median of 18 months (range 12 to 73 months) postoperatively. All contacted owners reported excellent postoperative function with return to unrestricted activity and no observed lameness. Ten of these dogs (12 fractures) were subsequently presented for a long-term follow-up appointment, a median of 18 months (range 12 to 74 months) postoperatively. Mild periarticular thickening of the affected elbow was noted in all cases. All cases had elbow range of motion within −10° to +10° of the contralateral elbow on goniometric measurement, range 103° to 119° on affected legs and 110° to 127° on non-affected legs. On gait analysis (VAS), seven dogs scored 0/10 (no lameness) and three dogs scored 1/10 (subtle lameness). Objective data acquired on a PSW showed only mild maximal force asymmetry (<20%), with both increased and decreased Max force (%BW) noted on affected limbs in the eight cases with unilateral fractures. LOAD scores between 0 and 10 were recorded for all dogs. Results are presented in Table 4.

DISCUSSION

The outcome following locking and hybrid locking fixation of humeral condylar fractures in skeletally immature French bulldogs is comparable with previous studies, where excellent outcomes have been reported in 49.6 to 87% of cases (Morgan *et al.* 2008, Perry *et al.* 2015, Cinti *et al.* 2017, Sanchez Villamil *et al.* 2020). Recent studies have identified the French bulldog as predisposed to humeral condylar fractures, and the French bulldog has been reported to be more likely to have medial- or bicondylar fractures than Spaniel breeds (García *et al.* 2020, San-

Table 4. Cases attending long-term follow-up assessment

Case	Affected leg	Fracture configuration	Months postoperatively	Postoperative complication	Elbow ROM in degrees (affected leg/non-affected leg/difference)	% Bodyweight distribution (affected/non-affected leg)	Symmetry (max force) left/right	VAS	LOAD
1	R	Lateral	73	N/A	110/120/−10	32/37	1.15	1	7
6	L	Lateral	48	N/A	113/120/−7	32/35	0.91	0	4
9	L	Medial	41	N/A	118/127/−9	34/29	1.19	1	3
18	R	Lateral	26	N/A	108/110/−2	35/28	0.80	0	0
23	R	Lateral	19	N/A	113/116/−3	34/32	0.96	1	10
28	R*	Lateral	18	Minor	115/116/−1	32/32	0.98	0	4
29	L*	Medial	17	N/A	116/115/+1	32/32	0.98	0	4
31	R*	Lateral	14	N/A	103/113/−10	37/30	0.82	0	2
32	L*	Lateral	14	Major	113/103/+10	30/37	0.82	0	2
36	L	Lateral	13	Major	115/110/+5	36/39	0.91	0	3
37	L	Lateral	11	N/A	117/118/−1	33/31	1.06	0	5
40	L	Lateral	10	N/A	119/118/+1	28/32	0.88	0	2

ROM Range of motion, VAS Visual analogue score, LOAD Liverpool Osteoarthritis in Dogs
*Cases with bilateral fractures

chez Villamil *et al*. 2020, Smith *et al*. 2020). The distribution of fracture configuration in our study was different, revealing a higher incidence of lateral condylar fractures (76.1%) (Sanchez Villamil *et al*. 2020, Smith *et al*. 2020). Females were also more frequently affected than males, which has not previously been reported (Perry *et al*. 2015, Sanchez Villamil *et al*. 2020, Smith *et al*. 2020). Further investigations are needed to clarify if skeletally immature female French bulldogs are at a higher risk of condylar fracture.

HIF is characterised by a fissure in the mid-sagittal plane of the humeral condyle after the expected fusion of the medial and lateral ossification centres of the humeral condyle at 2 to 3 months of age (Hare 1961, Meutstege 1989, Marcellin-Little *et al*. 1994, Moores & Moores 2017). We found radiographic evidence of a contralateral HIF at the time of fracture in six of 41 (15%) of our dogs and two of these dogs subsequently developed contralateral condylar fractures within 7 days of the original surgery. A further two dogs presented with bilateral simultaneous fractures, raising high suspicion of underlying HIF. This number may be an underestimation of the true number of HIF as CT imaging, which is the preferred diagnostic tool for HIF, was not performed (Carrera *et al*. 2008). Several cases of bilateral humeral condylar fractures in French bulldogs, simultaneous or within 3 weeks of initial presentation, was also previously reported (Smith *et al*. 2020). We, therefore, suspect that delay or failure of union of the humeral condyle can play a role in this disease process in French bulldogs, as described for spaniels with IOHC (Marcellin-Little *et al*. 1994, Moores *et al*. 2012). Chondrodystrophic breeds have also been suspected to be at risk of humeral condylar fracture due to the geometry of their limbs, with eccentrically positioned capitulum and a relatively small lateral epicondylar crest (Butterworth & Innes 2001, Smith *et al*. 2020). This may contribute to the development of HIF/IOHC in this breed; further investigation is needed to confirm this hypothesis. All condyles appeared to reach clinical union in contrast to what is expected for cases with underlying HIF/IOHC-pathology. It is unclear if this is due to the performed fixation, underestimation of persistent HIF due to the lack of CT imaging or if HIF/IOHC in bulldogs is different from the disease process described in Spaniel breeds.

A high number (3/7) of the cases with postoperative intracondylar steps and/or gaps were bicondylar fractures, and two of these cases also had a previously confirmed HIF at the time of contralateral fracture repair. It is unclear if the presence of an HIF or the increased technical challenge of reducing a bicondylar fracture contributed to the postoperative step and/or gap formation. Nevertheless, none of these cases developed postoperative complications, and good (n=3) or excellent (n=4) outcome was reported.

Recent publications favour epicondylar bone plates, rather than K-wire fixation, in combination with a transcondylar screw for medial and lateral humeral condylar fracture repair in dogs (Perry *et al*. 2015, Sanchez Villamil *et al*. 2020). Bilateral locking plate fixation combined with a transcondylar screw has been advocated to treat bicondylar fractures (Ness 2009, Moffatt *et al*. 2019, García *et al*. 2020). The populations of dogs in these reports are, however, very heterogeneous and limited information is provided about the impact of fixation method in skeletally immature dogs. Only one previous study has evaluated fixation of humeral condylar fractures in skeletally immature dogs (Cinti *et al*. 2017). In this study, stabilisation of the condyle was performed with a combination of transcondylar- and anti-rotational K-wires, and complications requiring surgical intervention were encountered in 23% of the cases. Our results compare favourably, where 91.1% of cases reached radiographic union without further surgical intervention and reduction of the condyle was not lost in any of the cases where complications were encountered. It remains unclear if the relatively low complication rate in our cases is the result of using a transcondylar screw, epicondylar plate or a combination of both, and a prospective randomised study is needed to establish the preferred stabilisation technique for these fractures. The advantages of using a locking plate system, such as increased screw pull-out strength (Large *et al*. 2008, Scrimgeour *et al*. 2017, Moffatt *et al*. 2019), may also have contributed to the absence of catastrophic mechanical failures in our cases.

The long-term follow-up after a median of 18 months postoperatively revealed excellent function, both assessed by the owners, surgeon and on objective analysis, which corresponds well with what previously reported following humeral condylar fracture management in the juvenile patient (Cinti *et al*. 2017). We can, however, only speculate on the degree of postoperative osteoarthritis as long-term radiographic follow-up was not performed, and longer follow-up time would be beneficial to better assess the long-term function.

Transcondylar screw loosening occurred in four cases, three of which required a revision surgery. This was despite all cases having plate fixation and was an unexpected complication. Potential causes include insufficient stability, infection, over/under tightening of the screw and thermal injury during placement. Whilst all cases occurred in lateral condylar fractures, there were no risk factors identified and the underlying cause remains unclear. None of the transcondylar screws fractured despite only being a mean of 36% of the diameter of the humeral condylar isthmus. This contrasts with previous recommendations for HIF treatment, where a large as possible transcondylar screw is recommended (Butterworth & Innes 2001).

Surgical site infection was only confirmed in one of our cases (2.2%). This compares favourably to infection rates previously reported following surgical stabilisation of humeral condylar fractures (6 to 14%) (Morgan *et al*. 2008, Perry *et al*. 2015, García *et al*. 2020). This is also lower than previously reported (5.2 to 7.1%) for clean orthopaedic procedures (Whittem *et al*. 1999, Turk *et al*. 2015). One can argue that surgical site infection could be present in the cases with loosening/backing out of the transcondylar screw; however, no macroscopic signs of infection were seen, no positive cultures were obtained and all cases reached clinical union following revision surgery.

The degree of relative limb shortening due to early symmetrical physeal closure, or angular limb deformity due to asymmetric closure, is dependent on the amount of residual growth potential and this has been utilised with hemiepiphysiodesis and

transphyseal bridging to correct angular limb deformity in growing animals (Carlson *et al*. 2012, Olsen *et al*. 2016). Despite all cases having implants crossing the distal humeral physis, abnormal development of the humeral condyle was not noted at the short-term radiographic follow-up and no negative clinical consequences were found on long-term follow-up. Long-term radiographic follow-up was not performed in clinically sound animals due to ethical reasons, including the risk of peri-anaesthetic complications in brachycephalic dogs (Gruenheid *et al*. 2018), and is a limiting factor to this study.

The distal humeral physis reportedly contributes only to approximately 20% of humeral length and closes around 6 months of age (Hare 1961, Manley *et al*. 1990). This can explain the findings in a previous report, where no shortening of the humeral diaphysis or humeral deformity were found following penetration of the distal humeral physis by the transcondylar screw in skeletally immature patients with lateral condylar fractures (Lefebvre *et al*. 2008). The absence of obvious condylar deformity evident in our case series despite the relatively young age range (3 to 6 months) is also interesting and can be a result of the small contribution of humeral length by the distal physis or that functional physeal closure occurs at an early age in this breed. Relative humeral length could not be assessed in our study as follow-up images of the contralateral limb were not available, and systematic evaluation of humeral mechanical axis was unfortunately not possible due to inconsistent radiographic projections on follow-up images. These results must therefore be interpreted with care and should not be extrapolated to fracture repair in other anatomic locations or other breeds where physeal closure may occur later.

This study is limited by retrospective nature, and the lack of standardisation of construct type, including plate size, screw numbers and mode, material and type of the transcondylar screw, are potential sources of error. Systematic radiographic evaluation of both affected and non-affected limbs for evaluation of humeral length and assessment of mechanical axis would also have provided valuable data for the assessment of potential postoperative deformity development. The lack of control groups, treated with a transcondylar screw and epicondylar K-wire fixation in open and/or minimal invasive fashion, also limits the conclusions that can be drawn from this study. Objective long-term follow-up was only attended by 24% of the operated cases and lack of long-term radiographic follow-up precluded systematic evaluation of humeral development; this was, however, beyond the scope of this study. CT imaging of contralateral limbs at the time of surgery could also potentially have revealed a higher number of humeral condylar fissures.

In conclusion, our hypothesis was confirmed and the results from this study suggest that fracture fixation involving implants crossing the distal humeral physis is a safe treatment option in skeletally immature French bulldogs and can lead to excellent short- and long-term outcomes.

Acknowledgements

The authors thank Michael Farrell, Jan Janovec, Igancio Calvo, Russel Yeadon, Christopher Jordan, James Guthrie, Susan Murphy, Padraig Egan, Jayson Tuan and the staff at Fitzpatrick Referrals for their contribution to the treatment and care for the cases in this study.

Conflict of interest

None of the authors of this article has a financial or personal relationship with other people or organisations that could inappropriately influence or bias the content of the paper.

References

Bardet, J. F., Hohn, R. B. & Rudy, R. I. (1983) Fractures of the humerus in dogs and cats, a retrospective study of 130 cases. *Veterinary Surgery* **12**, 73-77

Butterworth, S. J. & Innes, J. F. (2001) Incomplete humeral condylar fractures in the dog. *Journal of Small Animal Practice* **42**, 394-398

Carlson, E. R., Bramlage, L. R., Stewart, A. A., *et al*. (2012) Complications after two transphyseal bridging techniques for treatment of angular limb deformities of the distal radius in 568 thoroughbred yearlings. *Equine Veterinary Journal* **44**, 416-419

Carrera, I., Hammond, G. J. & Sullivan, M. (2008) Computed tomographic features of incomplete ossification of the canine humeral condyle. *Veterinary Surgery* **37**, 226-231

Cinti, F., Pisani, G., Vezzoni, L., *et al*. (2017) Kirschner wire fixation of Salter-Harris type IV fracture of the lateral aspect of the humeral condyle in growing dogs. A retrospective study of 35 fractures. *Veterinary and Comparative Orthopaedics and Traumatology* **30**, 62-68

Cook, J. L., Tomlinson, J. L. & Reed, A. L. (1999) Fluoroscopically guided closed reduction and internal fixation of fractures of the lateral portion of the humeral condyle: prospective clinical study of the technique and results in ten dogs. *Veterinary Surgery* **28**, 315-321

Denny, H. R. (1983) Condylar fractures of the humerus in the dog; a review of 133 cases. *Journal of Small Animal Practice* **24**, 185-197

Fox, S. M., Bray, J. C., Guerin, S. R., *et al*. (1995) Antebrachial deformities in the dog: treatment with external fixation. *Journal of Small Animal Practice* **36**, 315-320

Franklin, C., Herrtage, M., Harris, K. P., *et al*. (2021) Prevalence of humeral intracondylar fissures in asymptomatic brachycephalic breed dogs. Pre-BSAVA Virtual Spring Meeting, March 23-24, 2021

García, J., Yeadon, R. & Solano, M. A. (2020) Bilateral locking compression plate and transcondylar screw fixation for stabilization of canine bicondylar humeral fractures. *Veterinary Surgery* **49**, 1183-1194

Gruenheid, M., Aarnes, T. K., McLoughlin, M. A., *et al*. (2018) Risk of anesthesia-related complications in brachycephalic dogs. *Journal of the American Veterinary Medical Association* **253**, 301-306

Hammer, R. R., Hammerby, S. & Lindholm, B. (1985) Accuracy of radiologic assessment of tibial shaft fracture union in humans. *Clinical Orthopaedics and Related Research* **199**, 233-238

Hare, W. C. (1961) The ages at which the centers of ossification appear roentgenographically in the limb bones of the dog. *American Journal of Veterinary Research* **22**, 825-835

Johnson, K. A. (2014) The forelimb. In: Piermattei's Atlas of Surgical Approaches to the Bones and Joints of the Dog and Cat. 5th edn. Elsevier, St. Louis, MO, USA. pp 198-215

Large, T. M., Kellam, J. F., Bosse, M. J., *et al*. (2008) Locked plating of supracondylar periprosthetic femur fractures. *The Journal of Arthroplasty* **23**(6 Suppl 1), 115-120

Lefebvre, J. B., Robertson, T. R., Baines, S. J., *et al*. (2008) Assessment of humeral length in dogs after repair of Salter-Harris type IV fracture of the lateral part of the humeral condyle. *Veterinary Surgery* **37**, 545-551

Manley, P. A., Henry, W. B. & Wilson, J. W. (1990) Disease of the epiphysis. In: Canine Orthopedics. 2nd edn. Ed W. G. Whittick. Philadelphia, PA, USA, Lea & Febringer. p 597

Marcellin-Little, D. J., DeYoung, D. J., Ferris, K. K., *et al*. (1994) Incomplete ossification of the humeral condyle in spaniels. *Veterinary Surgery* **23**, 475-487

Meutstege, F. J. (1989) Incomplete condylar fracture in the canine humerus as a cause of obscure elbow lameness. 16th Annual Conference of the Veterinary Orthopaedic Society, Park City, Utah. p 11

Moffatt, F., Kulendra, E. & Meeson, R. L. (2019) Repair of Y-T humeral condyle fractures with locking compression plate fixation. *Veterinary and Comparative Orthopaedics and Traumatology* **32**, 401-407

Moores, A. P. & Moores, A. L. (2017) The natural history of humeral intracondylar fissure: an observational study of 30 dogs. *Journal of Small Animal Practice* **58**, 337-341

Moores, A. P., Agthe, P. & Schaafsma, I. A. (2012) Prevalence of incomplete ossification of the humeral condyle and other abnormalities of the elbow in English Springer Spaniels. *Veterinary and Comparative Orthopaedics and Traumatology* **25**, 211-216

Morgan, O. D., Reetz, J. A., Brown, D. C., *et al*. (2008) Complication rate, outcome, and risk factors associated with surgical repair of fractures of the lateral aspect

of the humeral condyle in dogs. *Veterinary and Comparative Orthopaedics and Traumatology* **21**, 400-405
Ness, M. G. (2009) Repair of Y-T humeral fractures in the dog using paired 'String of Pearls' locking plates. *Veterinary and Comparative Orthopaedics and Traumatology* **22**, 492-497
Olsen, A. M., Vezzoni, L., Ferretti, A., *et al*. (2016) Hemiepiphysiodesis for the correction of proximal tibial valgus in growing dogs. *Veterinary and Comparative Orthopaedics and Traumatology* **29**, 330-337
Perry, K. L., Bruce, M., Woods, S., *et al*. (2015) Effect of fixation method on postoperative complication rates after surgical stabilization of lateral humeral condylar fractures in dogs. *Veterinary Surgery* **44**, 246-255
Prieur, W. D. (1989) Management of growth plate injuries in puppies and kittens. *Journal of Small Animal Practice* **30**, 631-638
Rørvik, A. M. (1993) Risk factors for humeral condylar fractures in the dog: a retrospective study. *Journal of Small Animal Practice* **34**, 277-282
Sanchez Villamil, C., Phillips, A. S. J., Pegram, C. L., *et al*. (2020) Impact of breed on canine humeral condylar fracture configuration, surgical management, and outcome. *Veterinary Surgery* **49**, 639-647
Scrimgeour, A. B., Craig, A. & Witte, P. G. (2017) Locking T-plate repair of ilial fractures in cats and small dogs. *Veterinary and Comparative Orthopaedics and Traumatology* **30**, 453-460
Smith, M. A. J., Jenkins, G., Dean, B. L., *et al*. (2020) Effect of breed as a risk factor for humeral condylar fracture in skeletally immature dogs. *Journal of Small Animal Practice* **61**, 374-380
Turk, R., Singh, A. & Weese, J. S. (2015) Prospective surgical site infection surveillance in dogs. *Veterinary Surgery* **44**, 2-8
Whittem, T. L., Johnson, A. L., Smith, C. W., *et al*. (1999) Effect of perioperative prophylactic antimicrobial treatment in dogs undergoing elective orthopedic surgery. *Journal of the American Veterinary Medical Association* **215**, 212-216