BSAVA
JSAP JOURNAL OF SMALL ANIMAL PRACTICE

ORIGINAL ARTICLE

Outcome of surgical treatment of perineal hernia in cats: 36 cases (2013-2019)

M. W. L. Hubers[1,*], J. J. W. G. Vink*, H. N. Brissot†, B. E. Sjollema* and N. J. van Klaveren*

*Surgery department Medisch Centrum voor Dieren, 1014, Amsterdam, Netherlands
†Azurvet, 06700, Saint-Laurent-du-Var, France

[1]Corresponding author email: mikehubers123@hotmail.com

Objectives: To report the clinical presentation, complications, and long-term outcomes of cats treated for perineal hernia with modified internal obturator muscle transposition.

Methods: The medical records of cats surgically treated for perineal hernia between 2013 and 2019 were reviewed and an owner questionnaire was conducted to determine long-term outcome.

Results: Thirty-six cats were included in the study: 34 had bilateral and two unilateral hernias. Of these 36, 24 (67%) were male neutered with a median age of 10 (range: 1 to 18) years. The complication rate was low, however, one cat experienced a major postoperative complication: rectal prolapse requiring revision surgery 48 hours postsurgery. Short-term outcomes were available for 32 of 36 (89%) cats. Of the 32, 23 were examined 6 weeks postoperatively, and a telephonic consultation was performed for an additional nine of 32. Of the 23 cats examined directly, none had recurrence. Overall 12 of 32 experienced short-term postoperative tenesmus which resolved in nine of 12 (75%). Long-term outcomes were available for 31 of 36 cats (86%), with a median of 18.5 (6 to 89) months follow-up. A good outcome was achieved in 23 of 31 (74%) whereas three of 31 (10%) had fair outcomes and five of 31 (16%) had a poor outcome. Of the five cats with a poor outcome, two required subtotal colectomy to manage clinical signs related to megacolon, two were euthanised following a return of clinical signs, and one developed unilateral recurrence.

Clinical Significance: Perineal hernia should be considered in cats presenting with tenesmus or recurrent obstipation. Surgical treatment of perineal hernias in cats can result in good owner-assessed long-term outcome.

Journal of Small Animal Practice (2022) **63**, 776–783
DOI: 10.1111/jsap.13534

Accepted: 14 June 2022; Published online: 15 July 2022

INTRODUCTION

Perineal hernia occurs when separation or weakness of the pelvic diaphragm muscles and fascia allows caudal displacement of the pelvic or abdominal organs, or lateral deviation of the rectum into the ischiorectal fossa. Clinical signs include tenesmus, discomfort, constipation and ultimately obstipation (Van Sluijs & Sjollema 1989, Welches *et al.* 1992, Brissot *et al.* 2004, Shaughnessy & Monnet 2015, Bernardé *et al.* 2018). This condition is well-described in older entire male dogs, but is sparsely described in cats (Welches *et al.* 1992, Risselada *et al.* 2003, Galanty 2005, Vnuk *et al.* 2005; Pratschke & Martin 2014). The pathogenesis in dogs has not been fully elucidated but is believed to result from muscular atrophy, neurogenic atrophy, hormonal influence and tenesmus secondary to prostatic disease or chronic constipation (Sjollema *et al.* 1993, Mann *et al.* 1995, Brissot *et al.* 2004, Merchav *et al.* 2005, Niebauer *et al.* 2005, Shaughnessy & Monnet 2015). In contrast to dogs, prostatic

Results of this study have been presented at the ECVS 2021 Small Animal Resident Forum.

disease in cats is rare. Perineal hernia is rarely reported in female dogs (Niles & Williams 1999, Galanty *et al*. 2007), but Welches *et al*. (1992) reported that 25% of the affected cats were female and all but one female were neutered before admission, suggesting a possible species difference in sex predisposition. Perineal urethrostomy appeared to be an important risk factor for the development of perineal hernia in 10 of 40 cats, with the authors suggesting that extensive dorsal dissection could disrupt the fascial connections between the external anal sphincter and the coccygeal muscles (Welches *et al*. 1992). Idiopathic megacolon, perineal masses, anal sac disease, colitis, chronic enteropathy and trauma may also predispose cats to develop perineal hernias (Welches *et al*. 1992, Washabau & Holt 1999, Galanty 2005, Vnuk *et al*. 2005, Pratschke & Martin 2014). Welches *et al*. (1992) classified 50% of their patients with idiopathic perineal hernias.

Internal obturator muscle transposition (IOMT), or a modification of this technique, is the preferred surgical method in dogs with perineal hernia. The results are good to excellent, with 87% to 93% of patients remaining free of long-term clinical signs (Brissot *et al*. 2004, Bernardé *et al*. 2018, Cinti *et al*. 2021); however recurrence rates of up to 27% have been reported (Shaughnessy & Monnet 2015).

There is no clear consensus regarding the treatment of cats with perineal hernias. Welches *et al*. (1992) reported a 73% success rate in 15 of 40 cats that underwent surgical management of perineal hernia. However, only 60% of these cases were treated with IOMT. The medical management of cats with perineal hernia in the same study was unsatisfactory, with treatment success achieved in five of 32 cats. Subtotal colectomy is recommended before perineal herniorrhaphy in cases of megacolon and concurrent perineal hernia, as this often resolves the clinical signs of constipation (Washabau & Holt 1999).

This study aimed to describe the clinical presentation, long-term (>6 months) outcomes, and complications in a case series of cats surgically treated with modified IOMT (mIOMT) for perineal hernia.

MATERIALS AND METHODS

Study design and inclusion criteria

The easyVET (VetZ GmbH) database of one referral hospital was searched for "hernia perinealis" cases from January 2013 to December 2019. Only cats that were surgically treated with mIOMT for perineal hernia, according to the treatment protocol described below, were included. Data recorded included signalment, physical examination findings, clinical history, preoperative bloodwork and urine analysis when available, ultrasound and endoscopic findings when available, concurrent pathologies that might be related to perineal hernia, surgical complications and owner-assessed outcome for each patient. Thorough anamnesis was conducted which included the duration of clinical signs, description of the faeces (size, consistency), behaviour on the litter tray (non-productive straining) and any present comorbidities. The diagnosis of perineal hernia was based on digital rectal examination. Cats that were medically managed for perineal hernia or those not admitted to the surgical department for mIOMT were excluded from this study. Patients who presented with megacolon and concurrent perineal hernia first underwent a subtotal colectomy. These patients were included only if they required perineal herniorrhaphy to manage persistent clinical signs after subtotal colectomy. When abdominal radiographs were available for patients, the colon was assessed for the diagnosis of megacolon or distended colon using the reference range provided by Trevail *et al*. (2011). Patients with a ratio of maximum colon diameter to the length of L5 of more than 1.48 were considered to have megacolon and underwent a subtotal colectomy. Patients with a ratio between 1.28 and 1.48 were considered to have a distended colon and were included in the surgical group, as the first treatment was perineal herniorrhaphy.

Treatment protocol

All cats had a repeat rectal examination under general anaesthesia preceding surgery to confirm the diagnosis.

The anaesthesia and analgesia protocols were similar for all cats. After intravenous premedication with methadone (0.3 mg/kg; Comfortan; Dechra) and midazolam (0.2 mg/kg; Midazolam; Actavis), general anaesthesia was induced with propofol (Propofol; Fresenius Kabi) and maintained with isoflurane (Isoflo; ASTFarma) in oxygen. A fentanyl CRI (2–5 µg/kg/minute; Fentanyl; Bipharma) alongside Ringer's lactate at 5 mL/kg/hour was provided during surgery in patients with no evidence of cardiac disease. The patients were mechanically ventilated using intermittent positive pressure ventilation and anaesthesia was monitored using electrocardiogram, pulse oximetry and capnography.

All cats received prophylactic cefuroxime (22 mg/kg; Zinacef; GlaxoSmithKline), intravenously 30 minutes before skin incision. Bilateral perineal herniorrhaphy was performed during a single anaesthesia episode. Perineal herniorrhaphy was performed using mIOMT. The modification is based on the technique originally described by Van Sluijs & Sjollema (1989) and developed by one of the authors (B.E.S). Cats were placed in sternal recumbency in the reverse Trendelenburg position. The perineal region was clipped from the tail base to the distal femur, the rectum was digitally emptied, the anal sacs were evacuated, an anal purse-string suture was applied, and the tail was secured cranially. A curvilinear skin incision was carried out in the perineal region, from the base of the tail to the level of the ischiatic table (Fig 1). Following skin incision, the subcutaneous tissues and ischiorectal fat were dissected from the external anal sphincter and internal obturator muscles. The pudendal nerve and the accompanying vessels were identified and preserved. The origin of the internal obturator muscle was sharply incised along the ischiatic arch. The obturator muscle was elevated from the ischiatic table using a Freer periosteal elevator and the tendon of the internal obturator muscle was completely transected to facilitate elevation of the internal obturator muscle. A horizontal mattress suture of double-armed polypropylene 3/0 (Optilene; Braun) was placed: first one end of the double-armed

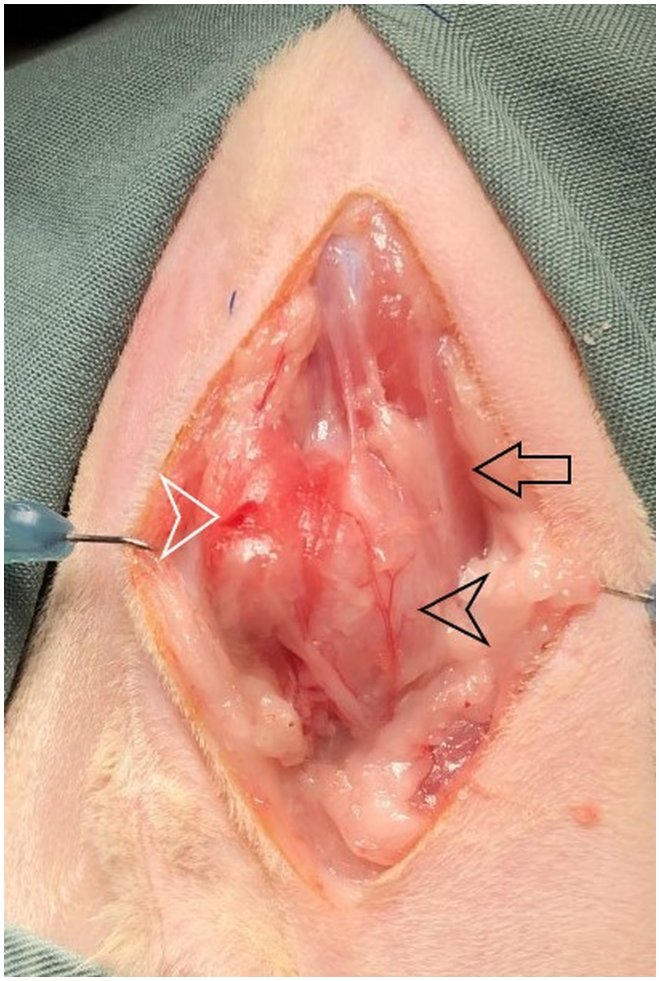

FIG 1. Intraoperative view of a right sided perineal hernia after incision of the skin and subcutaneous fat. The rectal wall (black arrowhead) is visible between the external anal sphincter muscle (white arrow head) and the coccygeal muscle (black arrow) consistent with atrophy of the levator ani muscle and a confirmation of the diagnosis of perineal hernia

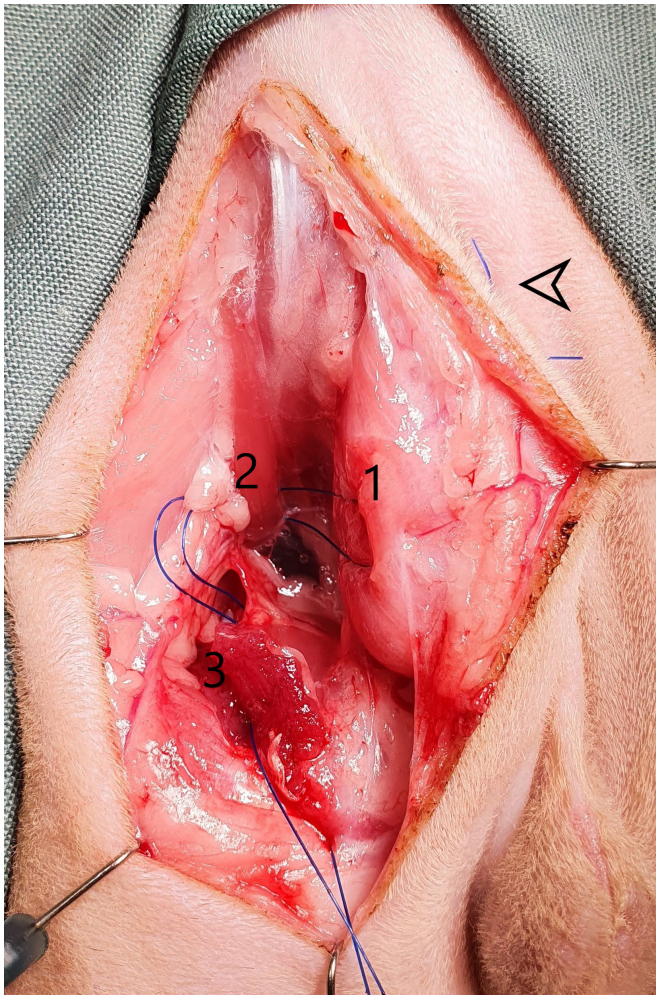

FIG 2. Intraoperative view of a left-sided perineal hernia, application of the mattress suture with double-armed polypropylene from caudal to cranial through the middle of the external anal sphincter muscle (1), the base of the coccygeal muscle from medial to lateral (2) and the tendon of the internal obturator muscle from dorsal to ventral (3). This sequence is repeated to create a mattress suture with the double-armed polypropylene. The anal purse string is visible (black arrowhead)

suture was placed through the external anal sphincter muscle from caudal to cranial, the coccygeal muscle from medial to lateral, and the tendon of the internal obturator muscle from dorsal to ventral. This suture sequence was repeated with the other end of the double-armed polypropylene 3/0 5-mm dorsal from the first suture line (Fig 2). In this manner, a mattress suture was created and the two ends of the double armed suture were tied at the ventral aspect of the internal obturator muscle tendon, elevating the internal obturator muscle (Fig 3). Two simple continuous suture lines were created with the two remaining suture ends. The coccygeal muscle was sutured to the external anal sphincter muscle dorsally, and the internal obturator muscle was sutured to the external anal sphincter muscle ventrally (Fig 4). The suture bites were placed approximately 5 mm apart. Subcutaneous tissues and skin were closed routinely. All cats wore an Elizabethan collar for 10–14 days after surgery to prevent interference with the surgical wound. All surgeries were performed by a Royal Dutch Veterinary Association specialist surgeon, an ECVS diplomate or a resident under direct supervision.

Follow-up

Postoperative surgical complications were classified as described by Cinti *et al.* (2021). Minor complications were defined as complications that did not require additional surgical treatment to resolve, and major defined as those that required additional surgical treatment to resolve either the complications or an associated morbidity. Short-term outcomes were obtained at a recheck appointment 6 weeks postoperatively. Physical and rectal examinations were performed at this appointment. A telephonic update was obtained at the same time with owners who did not admit their cat for a recheck appointment. Cats were excluded from the short-term outcome evaluation if a 6-week follow-up was unavailable.

A standardised telephone interview, adapted from Brissot *et al.* (2004), was conducted with the owners to determine the long-term owner-assessed outcomes (> 6 months) (Appendix S1). Patients were excluded from the long-term outcome if a follow-up of at least 6 months was unavailable.

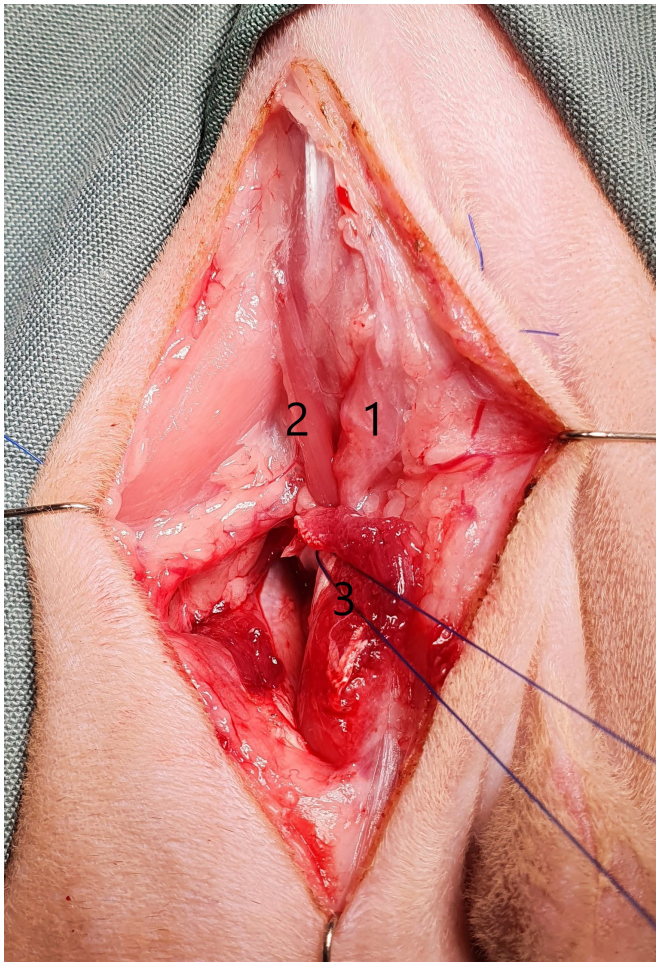

FIG 3. Intraoperative view of a left-sided perineal defect. The free ends of the mattress suture are tied at the ventral side of the tendon of the internal obturator muscle, which causes an elevation of the internal obturator muscle and partial closure of the hernia. External anal sphincter muscle (1), coccygeal muscle (2), internal obturator muscle (3)

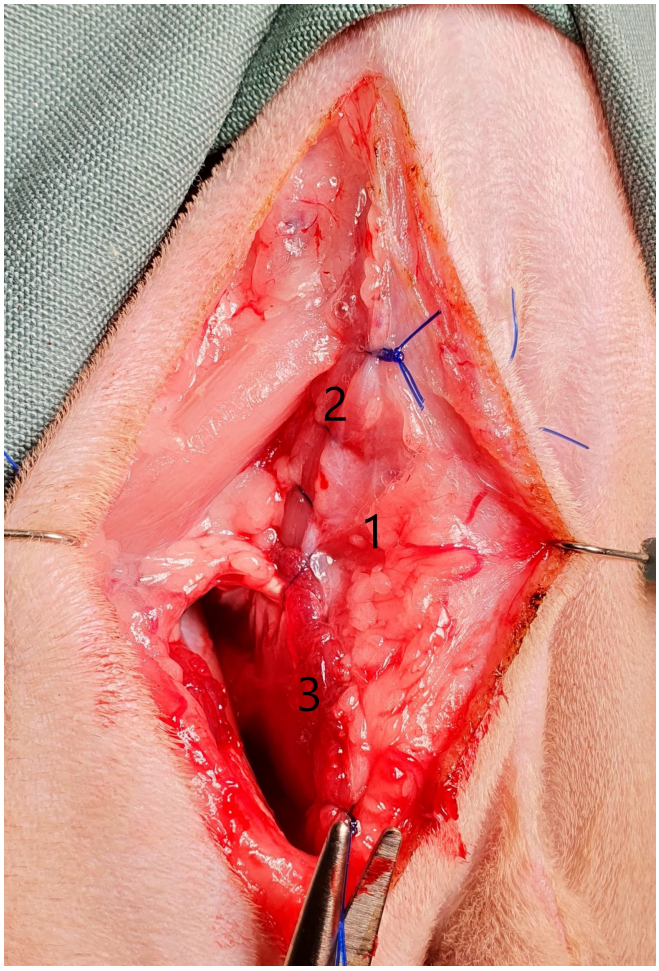

FIG 4. Intraoperative view of a completed left-sided perineal herniorrhaphy. With the two remaining suture ends, the external anal sphincter muscle (1) is sutured to the coccygeal muscle (2) dorsally and the elevated internal obturator muscle (3) is sutured to the external anal sphincter ventrally resulting in complete closure of the perineal defect. The ventral knot of the continuous suture pattern is being cut

Surgical outcomes were based on the outcome classification of Brissot *et al.* (2004). Perineal herniorrhaphy was defined as achieving a good outcome when the patient did not experience long-term clinical signs and no additional surgery was required after perineal herniorrhaphy. A fair outcome was defined when patients experienced long-term intermittent clinical signs without recurrence of perineal hernia or patients requiring long-term prokinetics. A poor outcome was defined as additional surgery required to manage persistent clinical signs, recurrence was diagnosed, or when the outcome resulted in the patient's death.

Data analysis

Continuous variables such as age, weight, duration of clinical signs, surgical time, and follow-up times were assessed for normality using the commercial software R (R version 3.4.4. and RStudio 1.1.463). Numerical variables are expressed as n and % for count variables, as mean ±standard deviation and range for variables with normal distribution, and as median, interquartile range (IQR), and range for non-normally distributed numeric variables. Normality was assumed when the histogram showed symmetry and the Shapiro–Wilk test was not significant.

RESULTS

In total, 86 cats were seen with a presumptive diagnosis of perineal hernia during the study period: 36 of 86 met the inclusion criteria and 50 of 86 were excluded. A total of 38 of 50 cats were excluded because the provisional diagnosis of perineal hernia could not be confirmed. Three of 50 cats were managed medically and were therefore excluded. Twelve of 86 cats presented with megacolon and concurrent perineal hernia. Subtotal colectomy resolved the clinical signs in nine of 12 such that perineal herniorrhaphy was not required meaning these patients were excluded.

Signalment

Thirty-six cats were surgically treated with mIOMT for perineal hernia. The breeds included were Domestic shorthair cats (n=21, 58%), Maine Coon (n=5, 14%), Siamese (n=4, 11%), Sphynx (n=2, 6%) and one each of Pixie-Bob, British shorthair, Abyssinian, and Norwegian Forest cat. The median age at the time of

surgery was 10.0 (IQR: 7.5 to 14.0; range: 1 to 18) years. There were 24 males and 12 females, and all cats were neutered before admission. The median body weight was 5.0 (IQR: 4.4 to 5.8; range: 2.95 to 10) kg.

Patient presentation

Bilateral perineal hernia was diagnosed by digital rectal examination in 34 of 36 cats and unilateral hernia in 2 of 36 cats (one left- and one right-sided). Urinary bladder entrapment in the perineal hernia was present in two female cats with bilateral perineal hernia, and neither exhibited stranguria or dysuria.

A possible aetiology for perineal hernia was determined in five of 36 cats. One cat had a tail pull injury with no evidence of pelvic fractures. At presentation, decreased anal tone was present with megacolon and concurrent bilateral perineal hernia. The cat still showed tenesmus after subtotal colectomy and underwent mIOMT with an uneventful recovery. One cat was treated with a unilateral subcutaneous ureteral bypass (SUB) because of a ureterolith. The cat developed sterile cystitis, with repetitive negative urinary cultures. The cat had never experienced constipation or tenesmus before SUB placement and was diagnosed with perineal hernia 2 months after SUB placement. Three cats had previously undergone subtotal colectomy for megacolon treatment. At the time of subtotal colectomy bilateral perineal hernias were present in these patients. The cats still exhibited tenesmus when defaecating, prompting perineal hernia repair 2 weeks, 4 weeks and 8 months after subtotal colectomy. The median duration of clinical signs before surgery, such as tenesmus or recurrent obstipation, were recorded for 28 of 36 cats and was 8 (IQR: 3.5 to 30.0; range: 1 to 72) months.

Diagnostics

Preoperative abdominal radiographs were available for 19 of 36 cats; 13 of 19 (68%) cats had a distended colon, and zero of 19 were diagnosed with preoperative megacolon.

Serum biochemistry results were available for 16 of 36 cats; two cats had elevated alanine aminotransferase levels and elevated total protein was present in one cat. Creatinine levels were available for 24 of 36 cats; five of 24 cats had elevated creatinine levels (measured range 79 to 277 µmol/L). Thyroxine (T4) levels were obtained for 14 of 36 cats. All T4 levels were within normal limits.

Abdominal ultrasound was performed in 14 cats, which was combined with cardiac ultrasound in six patients. Chronic enteropathy was suspected in three cats based on abdominal ultrasound. Subsequent histology of endoscopic biopsies revealed mild lymphoplasmacytic enteritis in one cat and no abnormalities in the other two cats. Hypertrophic cardiomyopathy without left atrial enlargement was diagnosed in one cat.

Urinalysis and culture were available for seven of 36 cats. In these cases, the urinalysis results were unremarkable.

Surgical treatment and aftercare

In total, 70 mIOMTs were performed in 36 cats: 34 bilateral and two unilateral repairs. Two cats presented with retroflexion of the urinary bladder. In both cats, the urinary bladder could be repositioned in the abdominal cavity after perineal cystocentesis. One cat underwent cystopexy before herniorrhaphy and cystopexy was not performed in the second cat at the discretion of the primary surgeon. Surgical time for cats undergoing bilateral perineal hernia repair was documented in 33 of 36 cases, with a mean of 57 (range 41 to 90) min. None of the cats required any additional surgical technique other than mIOMT for perineal hernia repair.

A 10-day course of meloxicam (0.05 mg/kg; Novacam; AST-Farma) or robenacoxib (2 mg/kg; Onsior; Novartis) was administered to 31 of 36 cats at the discretion of the primary surgeon. A fentanyl patch (4 µg/kg/hour) was applied to five of 36 cats; these patients presented with creatinine levels above the reference range. No postoperative antibiotics were administered to any cat. All cats received a stool softener, paraffin or lactulose, at the discretion of the primary surgeon after surgery, which was tapered down 10 to 14 days postoperatively.

Short-term outcomes (≤6 weeks postoperatively)

Short-term outcomes were obtained for 32 of 36 cats, three cats were lost to follow-up and one cat died 1 week after surgery due to unknown causes. A total of 23 of 32 cats were admitted for re-examination, while for nine of 32, a telephone consultation was performed 6 weeks postoperatively. A major complication occurred in one cat that had a rectal prolapse 2 days postoperatively requiring incisional colopexy. The cat had an uneventful recovery and a good long-term outcome. No recurrence of perineal hernia was present on digital rectal examination of the 23 cats (46 mIOMTs) that presented for a recheck appointment 6 weeks postoperatively.

None of the cats experienced wound-related complications, faecal or urinary incontinence, or stranguria. Postoperative tenesmus was present in 12 of 32 cats (37%), which was scored by owners as moderate in five of 12 and mild in seven of 12 cats. Tenesmus resolved spontaneously in nine of 12 cats, but in the other three of 12 megacolon was diagnosed at the recheck appointment based on abdominal radiographs and persistent clinical signs. The three cats that developed megacolon were diagnosed with a distended colon on preoperative abdominal radiographs (range: 1.33 to 1.38). Of the 12 cats with postoperative tenesmus, eight had a distended colon on preoperative abdominal radiography.

Long-term outcomes (>6 months postoperatively)

Long-term follow-up data was available for 31 of 36 cats (86%). One cat died 3 months after surgery from congestive heart failure and was therefore excluded from long-term follow-up. A total of 20 of 31 cats were alive and 11 of 31 were deceased at the time of the telephone follow-up. The median follow-up of the cats that were still alive at the time of the telephone interview was 18.5 (IQR: 13.5 to 41; range: 6 to 89) months. The surgical outcome in 23 of 31 (74%) cats was considered good, with no long-term clinical signs, whereas three of 31 (10%) cats achieved a fair outcome because these patients showed intermittent clinical signs or required daily prokinetics (n=2) to manage the clinical signs associated with megacolon. The surgical outcome of five of 31

(16%) patients was considered poor as two of five required subsequent subtotal colectomy to manage persistent clinical signs, one of five had a right-sided ventral recurrence diagnosed 3 months postoperatively, and two of five cats were euthanised following recurrence of clinical signs at 12 and 36 months after surgery.

The other, nine of 11 cats died of causes unrelated to perineal hernia at a median age of 15 (IQR: 11.5 to 17.5; range: 6.5 to 19) years. The cause of death was specified in two of nine cats; a road traffic accident and euthanasia due to lymphoma. The cause of death in the other seven of nine cats was not specified.

Megacolon was diagnosed in four of 31 cats at 6 weeks (n=3) and 9 months (n=1) postoperatively; two of four were considered to have a fair outcome because of acceptable outcomes with medical treatment consisting of prokinetics and stool softeners. The other two of four cats were classed as having a poor outcome because subtotal colectomy at 6 weeks and 44 months after perineal herniorrhaphy led to complete resolution of previously intractable clinical signs.

Of the cats with preoperative distended colon, nine of 13 recovered a normal long-term defaecation pattern and four of 13 did not. Megacolon was diagnosed in three of these cats. In the other cat no cause for the ongoing tenesmus was identified on abdominal radiography and digital rectal examination.

The median duration of clinical signs before surgery was 7.0 (range: 1 to 72) months for cats with a good outcome, whereas the group of cats with fair or poor outcomes had a median duration of clinical signs of 30.0 (range: 8 to 42) months.

Daily medical management was required for 10 of 31 cats (32%) which consisted of stool softeners in six of 10 cats, and stool softeners in addition to a prokinetic in four of 10 cats with evidence of megacolon. Medication was tapered and discontinued in two cats that underwent a subtotal colectomy after perineal herniorrhaphy. Of the cats that received daily stool softeners, five of 10 had a good outcome without clinical signs according to the owners.

All owners of cats with a known long-term outcome (31 of 36) would have the same surgery performed in their cats and would recommend surgery to owners of cats that show clinical signs related to perineal hernia.

DISCUSSION

Successful resolution of clinical signs related to perineal hernia was achieved by mIOMT in 74% of cases. This is comparable to that in the case series of Welches *et al.* (1992) who reported a 73% success rate. Of the 15 cats that underwent perineal herniorrhaphy in their study, partial success was achieved in one which was medically managed for megacolon. They diagnosed failure of the repair in three cases (20%), which is substantially higher than in our series, with only one recurrence in 31 cats (3%). Pratschke & Martin (2014) reported intermittent long-term clinical signs in two out of three cats in their case series. This could be related to a difference in clinical presentation, as all cats in their case series were diagnosed with an underlying enteropathy. In our study, for five of eight cats with a fair or poor outcome, a presumptive cause for this outcome could be determined. This included megacolon in four of eight cases and unilateral recurrence in one of eight. Subtotal colectomy was performed in two of four cats which resulted in complete resolution of clinical signs. The other two of four cats with megacolon were managed medically at the owners' request, and the owner of the cat with a unilateral recurrence declined revision surgery. These cats could have potentially had better clinical outcomes if additional surgical treatments were pursued. In the remaining three of eight cats with fair or poor outcomes no clear cause for the intermittent clinical signs could be determined during digital rectal examination and abdominal radiography. The occurrence of intractable intermittent tenesmus in 10% of our study population is comparable to that described in dogs (Brissot *et al.* 2004, Bernardé *et al.* 2018, Cinti *et al.* 2021) who reported postoperative tenesmus with no clear underlying cause in 7% to 13% of their patients.

In accordance with the study by Welches *et al.* (1992), the vast majority of the patients in the current study presented with bilateral perineal hernias (94%). This finding is in contrast to what has previously been reported for perineal hernia in dogs, with 38% to 54% of the patients having bilateral hernias (Sjollema & van Sluijs 1989, Hosgood *et al.* 1995, Shaughnessy & Monnet 2015, Cinti *et al.* 2021). In a recent study however, Bernardé *et al.* (2018) reported that all dogs in their study with apparent unilateral perineal hernia displayed evidence of contralateral (subclinical) perineal hernia, suggesting that perineal hernia in dogs should also be considered a bilateral disease.

The majority of patients in the present study (67%) were male which is comparable to the results of Welches *et al.* (1992), who reported that 75% of their study population was male. In contrast with dogs, 33% of our study population were female and all patients were previously neutered. Compared to female cats, female dogs are rarely affected by perineal hernia, and male dogs that present with perineal hernia are generally not neutered or recently neutered before admission for perineal hernia (Hosgood *et al.* 1995, Brissot *et al.* 2004, Shaughnessy & Monnet 2015, Bernardé *et al.* 2018, Cinti *et al.* 2021). As such, perineal hernia in cats appears to have a different aetiology than that in dogs and can occur secondary to a primary condition that causes straining and secondary weakening of the pelvic diaphragm, subsequently resulting in perineal hernia (Welches *et al.* 1992, Washabau & Holt 1999, White 2002, Risselada *et al.* 2003, Galanty 2005, Vnuk *et al.* 2005, Pratschke & Martin 2014).

A potential aetiology for perineal hernia was determined in five of 36 (14%) cats in our study and could be related to megacolon, tail pull injury, and placement of a SUB which caused sterile cystitis. In the remaining 31 of 36 (86%) cats, no clear underlying cause for the development of perineal hernia was diagnosed. Welches *et al.* (1992) identified a potential primary condition that might have contributed to the development of perineal hernias in 20 of 40 cases. Perineal urethrostomy was the potential aetiology in 10 of 40 cases. None of the patients in our study underwent urethrostomy before perineal hernia repair. It could also be hypothesised that not the perineal urethrostomy itself but the chronic urinary straining caused by lower urinary

tract diseases could be the underlying aetiology for perineal hernia in these patients. Welches *et al.* (1992) proposed that disruption of the fascial planes between the external anal sphincter and coccygeal muscles during the surgical approach to perineal urethrostomy may cause perineal hernia. This should be avoided through careful tissue handling and adherence to the recommended surgical technique.

Pratschke & Martin (2014) suggested that preoperative rectal prolapse and chronic enteropathy could be important risk factors for developing perineal hernia. Two of three cats in their case series had preoperative rectal prolapse. Intestinal biopsies obtained during laparotomy revealed chronic enteropathy in all cases, and faecal cultures were positive for known intestinal pathogens in two cats. In our study, abdominal ultrasound was performed in 40% of cases, endoscopy in 10% and faecal culture in none of the patients. Due to the retrospective nature of the study, a consistent, systematic medical work-up was not provided for all cats, which means that underlying conditions such as chronic enteropathies and/or intestinal pathogens could have been underdiagnosed which might have led to suboptimal outcomes. Results of these additional diagnostic test would have been particularly valuable in the subpopulation of cats without a clear cause for the fair or poor outcome. In future studies, it would be interesting to perform a systematic medical work-up in feline patients with perineal hernia to exclude underlying diseases. Ideally, the medical workup would consist of complete blood analysis including cobalamin, faecal culture, parasitic screening, urinalysis and culture, abdominal ultrasound and intestinal biopsies if an abdominal procedure is planned. This could potentially lead to better clinical outcomes when the underlying conditions are appropriately diagnosed and treated.

Preoperative abdominal radiographs were available for 19 of 36 (53%) cats. In the other cats, it was not deemed necessary at the time of diagnosis, as there was no evidence of a distended colon on abdominal palpation. This could represent a limitation of our study because abdominal palpation is subjective and could be misleading in cats that had recent enemas. However, the four patients who were eventually diagnosed with megacolon after perineal herniorrhaphy had preoperative abdominal radiographs which did not reveal measurements that were consistent with megacolon. Nine of the 13 patients with a preoperative distended colon recovered a normal defaecation pattern after mIOMT, whereas three of 13 were eventually diagnosed with megacolon during the follow-up period. For the remaining cat, no cause for the persistent clinical signs was determined by abdominal radiography and digital rectal examination. Cats with a distended colon due to obstipation caused by perineal hernia could potentially benefit from subtotal colectomy before perineal hernia repair, as this could resolve the clinical signs of constipation. However, in our population, this would have implied unnecessary subtotal colectomy for 10 of 13 patients. It is the authors' opinion that in these cases, subtotal colectomy should be avoided, as this does not treat the suspected primary condition and could result in additional patient morbidity. This is also illustrated by the three cats that presented with ongoing clinical signs after subtotal colectomy to manage megacolon. In these cases, clinical signs resolved when bilateral mIOMT was performed.

The differentiation between perineal hernia with secondary obstipation and megacolon with concurrent perineal hernia should be made based on the anamnesis, clinical examination and medical imaging (Pratschke, 2005). This might be difficult because the clinical complaints could appear very similar. Furthermore the cut-off value for megacolon provided by Trevail *et al.* (2011) had a reported sensitivity of 77% and a specificity of 85%. For that reason, the authors suspect that there might be a cross-over in cases with perineal hernia and early concurrent megacolon and patients with perineal hernia and secondary obstipation. This might explain why three cats that did not meet the cut-off value for megacolon on preoperative abdominal radiographs were diagnosed with megacolon 6 weeks after perineal herniorrhaphy.

The median recorded time of clinical signs associated with perineal hernia before surgery was 8 months, with several cats having complaints for up to 72 months. These values are comparable to those reported by Welches *et al.* (1992). Cats in our study that had a fair or poor outcome had a fourfold median duration of clinical signs related to perineal hernia before surgery, compared to cats with good outcomes (median 30.0 and 7.0 months, respectively). It could be suggested that an early diagnosis and surgical treatment of cats with perineal hernia could lead to better outcomes. The prolonged time preceding surgery increases the time of secondary obstipation. This could lead to irreversible neuromuscular damage to the colon. Pathologic dilation has been hypothesised in feline patients with obstipation secondary to pelvic fracture malunion (Matthiesen *et al.* 1991, Washabau & Holt 1999, Colopy-Poulsen *et al.* 2005, DeGroot *et al.* 2016). From these conclusions, perineal hernia could not only be a consequence of megacolon, as previously suggested (Welches *et al.* 1992, Washabau & Holt 1999), but could also potentially contribute to the development of megacolon, as suggested by White (2002).

Tenesmus was observed in 12 of 32 cats in the direct postoperative period, of which eight of 12 cats had a distended colon on the preoperative radiographs. For this reason, we recommend digital removal of dried, hard faeces from the rectum and distal colon before perineal hernia repair to facilitate easier defaecation in these patients in the direct postoperative period. The authors do not recommend a perioperative enema for this purpose, as it may increase the risk of contamination of the surgical site with faecal matter.

The authors suggest that a thorough rectal examination should be performed in cats presenting with constipation and tenesmus. Anal sac disease and perineal or rectal masses that could present as an underlying cause of perineal hernia would be identified. We suspect that digital rectal examination is infrequently used in cats, as illustrated in the study by Benjamin & Drobatz (2020). In this study, 189 cats diagnosed with constipation were reviewed, and none of these cats were diagnosed with perineal hernia; interestingly, the results of digital rectal examinations were not mentioned. In agreement with Pratschke & Martin (2014), we suspect perineal hernia in cats to be underdiagnosed as most cats in our study had regular visits to the referring veterinarian for enemas or digital emptying of the rectum without identification of perineal hernia.

The surgical technique described here differs from that originally described by Van Sluijs & Sjollema (1989). A potential disadvantage of using a continuous suture pattern over an interrupted suture pattern could be failure of the suture line, which risks recurrence. However, only one of 70 mIOMTs was diagnosed with recurrence, suggesting that suture failure is unlikely. Our findings reveal that the described technique is effective and can be safely performed for bilateral one-stage perineal hernia repair.

The authors acknowledge several limitations of this study. The sample size was small, and long-term follow-up of at least 6 months was only available in 86% of the cases. The long-term outcomes of the cats in our study were based on subjective evaluations by owners which may make this assessment less reliable. Due to its retrospective nature, the standardisation of data could not be controlled.

In conclusion, cats with clinical signs attributable to perineal hernia can have a good prognosis after surgery, with 74% of patients free of clinical signs after mIOMT, according to owner assessment. The described technique has been shown to be effective, with only one recurrence. In some cases, it is difficult to differentiate feline patients with constipation secondary to perineal hernia from those patients with perineal hernia and early concurrent megacolon. Because of this, owners should be informed that intermittent postoperative tenesmus could persist which might require future surgical or medical intervention. Perineal hernia should be included in the differential diagnosis of cats presenting with constipation and tenesmus, and digital rectal examinations should be performed in these patients.

Acknowledgement

The authors would like to thank E. den Hertog, DVM, MSc (Hertog Veterinary Research Support, Amersfoort, The Netherlands, edh@boshert.nl) for his assistance with the statistical analysis.

Author contributions

Mike Hubers: Conceptualization (lead); data curation (lead); methodology (equal); writing – original draft (lead); writing – review and editing (lead). **Joris Vink:** Conceptualization (supporting); data curation (supporting); writing – original draft (supporting); writing – review and editing (equal). **Herve Brissot:** Methodology (supporting); supervision (equal); writing – review and editing (equal). **Bart Sjollema:** Conceptualization (equal); methodology (equal); supervision (equal); writing – review and editing (equal). **Nicolien van Klaveren:** Conceptualization (equal); methodology (equal); supervision (equal); writing – review and editing (equal).

Conflict of interest

None of the authors of this article has a financial or personal relationship with other people or organisations that could inappropriately influence or bias the content of the paper.

References

Benjamin, S. E. & Drobatz, K. J. (2020) Retrospective evaluation of risk factors and treatment outcome predictors in cats presenting to the emergency room for constipation. *Journal of Feline Medicine and Surgery* **22**, 153-160

Bernardé, A., Rochereau, P., Matres-Lorenzo, L., *et al*. (2018) Surgical findings and clinical outcome after bilateral repair of apparently unilateral perineal hernias in dogs. *Journal of Small Animal Practice* **59**, 734-741

Brissot, H. N., Dupré, G. P. & Bouvy, B. M. (2004) Use of laparotomy in a staged approach for resolution of bilateral or complicated perineal hernia in 41 dogs. *Veterinary Surgery* **33**, 412-421

Cinti, F., Rossanese, M. & Pisani, G. (2021) A novel technique to incorporate the sacrotuberous ligament in perineal herniorrhaphy in 47 dogs. *Veterinary Surgery* **50**, 1023-1031

Colopy-Poulsen, S. A., Danova, N. A., Hardie, R. J., *et al*. (2005) Managing feline obstipation secondary to pelvic fracture. *Compendium* **27**, 662-670

DeGroot, W., Gibson, T. W., Reynolds, D., *et al*. (2016) Internal hemipelvectomy for treatment of obstipation secondary to pelvic malunion in 3 cats. *The Canadian Veterinary Journal* **57**, 955-960

Galanty, M. (2005) Perineal hernia in 3 cats. *Polish Journal of Veterinary Sciences* **8**, 165-168

Galanty, M., Mastalerz, T. & Turek, B. (2007) Dorsal perineal hernia in a bitch. *Medycyna Weterynaryjna* **63**, 919-921

Hosgood, G., Hedlund, C. S., Pechman, R. D., *et al*. (1995) Perineal herniorrhaphy: perioperative data from 100 dogs. *Journal of the American Animal Hospital Association* **31**, 331-342

Mann, F. A., Nonneman, D. J., Pope, E. R., *et al*. (1995) Androgen receptors in the pelvic diaphragm muscles of dogs with and without perineal hernia. *American Journal of Veterinary Research* **56**, 134-139

Matthiesen, D. T., Scavelli, T. D. & Whitney, W. O. (1991) Subtotal colectomy for the treatment of obstipation secondary to pelvic fracture malunion in cats. *Veterinary Surgery* **20**, 113-117

Merchav, R., Feuermann, Y., Shamay, A., *et al*. (2005) Expression of relaxin receptor LRG7, canine relaxin, and relaxin-like factor in the pelvic diaphragm musculature of dogs with and without perineal hernia. *Veterinary Surgery* **34**, 476-481

Niebauer, G. W., Shibly, S., Seltenhammer, M., *et al*. (2005) Relaxin of prostatic origin might be linked to perineal hernia formation in dogs. *Annals of the New York Academy of Sciences* **1041**, 415-422

Niles, J. D. & Williams, J. M. (1999) Perineal hernia with bladder retroflexion in a female cocker spaniel. *Journal of Small Animal Practice* **40**, 92-94

Pratschke, K. (2005) Surgical diseases of the colon and rectum in small animals. *In Practice* **27**, 354-362

Pratschke, K. & Martin, L. (2014) Bilateral perineal hernia in three cats: case studies. *Veterinary Times* **18**, 10-13

Risselada, M., Kramer, M., Van de Velde, B., *et al*. (2003) Retroflexion of the urinary bladder associated with a perineal hernia in a female cat. *Journal of Small Animal Practice* **44**, 508-510

Shaughnessy, M. & Monnet, E. (2015) Internal obturator muscle transposition for treatment of perineal hernia in dogs: 34 cases (1998–2012). *Journal of the American Veterinary Medical Association* **246**, 321-326

Sjollema, B. E. & Van Sluijs, F. J. (1989) Perineal hernia repair in the dog by transposition of the internal obturator muscle, part II: complications and results in 100 patients. *Veterinary Quarterly* **11**, 18-23

Sjollema, B. E., Venker-van Haagen, A. J., van Sluijs, F. J., *et al*. (1993) Electromyography of the pelvic diaphragm and anal sphincter in dogs with perineal hernia. *American Journal of Veterinary Research* **54**, 185-190

Trevail, T., Gunn-Moore, D., Carrera, I., *et al*. (2011) Radiographic diameter of the colon in normal and constipated cats and in cats with megacolon. *Veterinary Radiology & Ultrasound* **52**, 516-520

Van Sluijs, F. J. & Sjollema, B. E. (1989) Perineal hernia repair in the dog by transposition of the internal obturator muscle, part I: surgical technique. *Veterinary Quarterly* **11**, 12-17

Vnuk, D., Babić, T., Stejskal, M., *et al*. (2005) Application of a semitendinosus muscle flap in the treatment of perineal hernia in a cat. *Veterinary Record* **156**, 182-183

Washabau, R. J. & Holt, D. (1999) Pathogenesis, diagnosis, and therapy of feline idiopathic megacolon. *Veterinary Clinics of North America: Small Animal Practice* **29**, 589-603

Welches, C. D., Scavelli, T. D., Aronsohn, M. G., *et al*. (1992) Perineal hernia in the cat: a retrospective study of 40 cases. *Journal of the American Animal Hospital Association* **28**, 431-438

White, R. N. (2002) Surgical management of constipation. *Journal of Feline Medicine and Surgery* **4**, 129-138

Supporting Information

The following supporting information is available for this article:

Appendix S1. Supporting Information.