Received: 5 April 2021 | Revised: 26 September 2021 | Accepted: 29 October 2021

DOI: 10.1111/vsu.13747

SHORT CASE SERIES

WILEY

Modified prepubic urethrostomy with body wall tunneling: Description of technique and long-term outcome in eight male cats

Luca Bresciani DVM, MRCVS, PgC(sas), Resident in Small Animal Surgery[1] | **Andrea Mosca DVM, MRCVS, Oncologist**[2] | **Stefano Romussi DVM, PhD**[3]

[1]Bristol Veterinary School, University of Bristol, Bristol, UK

[2]Langford Vets, University of Bristol, Bristol, UK

[3]Department of Veterinary Medicine, University of Milan, Milan, Italy

Correspondence
Luca Bresciani, Langford Vets, University of Bristol, BS40 5DU Bristol, UK.
Email: luca.bresciani20@gmail.com

Abstract

Objective: To describe the procedure, complications, and long-term outcome of cats that underwent a modified prepubic urethrostomy (mPPU) technique for the management of proximal urethral obstructions.

Animals: Eight male cats.

Study Design: Short case series.

Methods: Medical records were reviewed for signalment, diagnostic investigation, details of the surgical procedure, and complications of cats that underwent mPPU.

Results: mPPU was well tolerated by all patients, and no intraoperative complications were reported. The duration of follow-up ranged from 13 to 84 months (median 19 months). Early postoperative skin scalding around the stoma associated with mild urinary incontinence during recumbency occurred and was self-limiting in all patients. Two cats required surgical revision at 5 and 6 months, respectively, due to a progressive weight gain and accumulation of abdominal fat around the stoma, causing a partial stomal obstruction. Resolution of clinical signs was reported in both patients.

Conclusions: mPPU was easy to perform and offered favorable outcomes in this cohort of cats.

1 | INTRODUCTION

Urethral obstruction, reported in 18% to 58% of cats, has been attributed to Feline Lower Urinary Tract Disease (FLUTD), urethral plugs, urolithiasis, granulomatous masses, neoplasia, and laceration or rupture of the urethra from accidental or iatrogenic trauma.[1]

Urethral obstruction can often be managed medically; however, recurrence rates have been reported in 30% to 40% of cats. In those cases, surgery becomes the treatment of choice.

Uropathies affecting the penile urethra may be surgically managed with perineal urethrostomy (PU). However, obstruction or rupture cranial to the bulbourethral glands might not be amenable to this technique. Prepubic (PPU), transpelvic (TPU), and subpubic (SPU) are alternative urethrostomy techniques that have been reported for the management of those uropathies.[2–7]

Prepubic urethrostomy was first reported in cats in 1955 by McCully for the management of recurrent urethral obstruction.[4] Transection of the urethra was reported the farthest distal from the bladder neck and exteriorizing the resected portion through a midline abdominal incision. Numerous modifications have been published describing the relocation of the stoma to a paramedian position and spatulating the urethra to widen

the stoma. Unfortunately, existing studies only included small case numbers; long-term outcome data are lacking.[3–8] Reported complications include urinary incontinence and peristomal dermatitis, most likely associated with the excessive shortening of the urethra and the consequential loss of anatomic structures that provide a natural outflow resistance within the urethra.[2,8,9]

Proper maintenance of urinary continence depends on an intricate interplay of neural signaling and muscle activity. While the neural signal should not be influenced by the PPU, muscular activity is largely affected. The urine exit from the urinary bladder through the urethra is partially controlled by the urethral sphincter, composed of internal (IUS) and external urethral sphincter (EUS) muscles. The EUS is present in the prostatic and postprostatic urethra, a portion of which is resected with PPU. Consequently, the bladder pressure in the storage phase of micturition, can become greater than the outflow resistance provided by the IUS, leading to urine leakage.[2,10,11]

Theoretically, urinary continence in these patients may be restored by increasing the resistance to urine flow. This theory is perhaps an oversimplification of the problem, but nearly all the surgical procedures developed to restore urinary continence are designed on this principle.[12] We developed our technique based on this concept, and with a similar tunneling as is commonly used to reduce ureteral reflux in ureteroneocystostomy. While in ureteroneocystostomy the outflow resistance is provided by a physiological change of the bladder muscle, similarly, in our study, this is provided by the rectus abdominis muscle.[13]

The purposes of this study are to describe a modification of the PPU technique (mPPU) with tunneling of the urethra through the abdominal wall for the management of proximal urethral obstructions in cats and to evaluate postoperative outcome and complications. To the authors' knowledge, this has not been reported prior in cats.

We hypothesize that tunneling the distal urethra through the rectus abdominis muscle prior to urethral-dermal anastomosis would increase the urethral outflow resistance and reduce the occurrence of postoperative urinary incontinence.

2 | MATERIALS AND METHODS

Medical records from the Veterinary Hospital of the University of Milan were retrospectively evaluated to identify feline patients treated with mPPU between March 2005 and October 2016. Cases were included if they had complete records and a minimum follow-up of 12 months.

2.1 | Diagnostic procedures

Physical examination, complete hematology, serum biochemistry, urinalysis, and urine culture were performed in all patients. Before surgery, a standardized urological diagnostic investigation was performed in all cases and included abdominal ultrasonography, abdominal radiography, and positive contrast retrograde urethrography with a water-soluble contrast medium (Omnipaque; GE Healthcare, USA). Each cat was sedated with methadone 0.2 mg/kg (Comfortan; Dechra Veterinary Products Ltd, UK) and medetomidine 2.5 μg/kg (Domitor; Vetoquinol, UK) intravenously (IV) for the preoperative urological diagnostic investigation. Positive contrast retrograde urethrography was performed by placing a tomcat catheter of appropriate size into the distal penile urethra. A dose of 3 to 5 mL/kg of dilute contrast was injected, and a radiograph was taken during the delivery of the contrast.

When a urethral stricture was suspected but could not be visualized, antegrade cystourethroscopy using a rigid, 30°, 1.9-mm scope (Karl Storz, Netherlands) via caudal celiotomy and cystostomy was performed at the time of surgery.

2.2 | Surgical technique

Cats sedated for presurgical investigation and deemed suitable for mPPU were then induced with propofol (PropoFlo; Abbot; at 5 mg/kg IV) to effect and maintained on isoflurane (IsoFluorane; Pirmal Critica Care). Perioperative antibiotic therapy with clavulanate-potentiated amoxicillin (Augmentin; Pfizer Ltd, UK) 20 mg/kg IV was administered to all patients and repeated every 90 min. The caudal abdomen was approached via standard caudal midline celiotomy. The bladder was identified, and stay sutures using 3–0 Polydioxanone (PDS II; Ethicon Ltd, UK) were placed on the lateral aspects of the bladder to aid in stabilization and exposure. When necessary, the bladder was emptied via cystocentesis. Anterograde catheterization of the urethra with an adequate-sized urinary catheter was performed through a stab incision on the ventral wall of the bladder. The postprostatic urethra was exposed, and dissection extended into the pelvic canal until the diseased urethra was encountered. Placement of a urinary catheter facilitated identifying the distal urethra within the periurethral fat during dissection and aided an accurate localization of the stricture. Care was taken to preserve blood supply and innervation of the bladder and proximal urethra (Figure 1).

As the urethra was elevated, the urinary catheter was retracted a few millimeters. An encircling ligature of 3–0

Polydioxanone was placed around the most distally exposed portion of the healthy urethra and transected just cranially to the ligature. The distal urethra and the ligature were left in situ. The catheter was re-advanced to facilitate manipulation of the isolated stump, and stay sutures were placed on the periurethral tissue around the free end of the proximally resected urethra (Figure 2). A tunnel was then created through the mid-body of the rectus abdominis muscle in a position intended to avoid any kinking or excessive urethral tension following urethrostomy. Curved mosquito forceps were used to carefully and bluntly create a short oblique tunnel within the rectus abdominis muscle fibers following a dorsoventral and craniocaudal trajectory using the same surgical technique described in the ureteroneocystostomy technique (Figure 3).[14]

A stab incision was made in the skin at the corresponding outer point of the muscular tunnel. Stay sutures were used to facilitate the urethral passage through the newly created muscular tunnel and skin incision (Figure 4). The traumatized urethral end was spatulated, and a stoma was created by suturing the urethral mucosa to the surrounding skin. Correct and tension-free apposition was assessed placing four simple interrupted sutures of 4–0 polydioxanone at 90° quadrants. More sutures were then placed between each of the quadrants if the position and tension were deemed adequate (Figure 5). After removal of the urinary catheter, the bladder wall was closed in a simple continuous

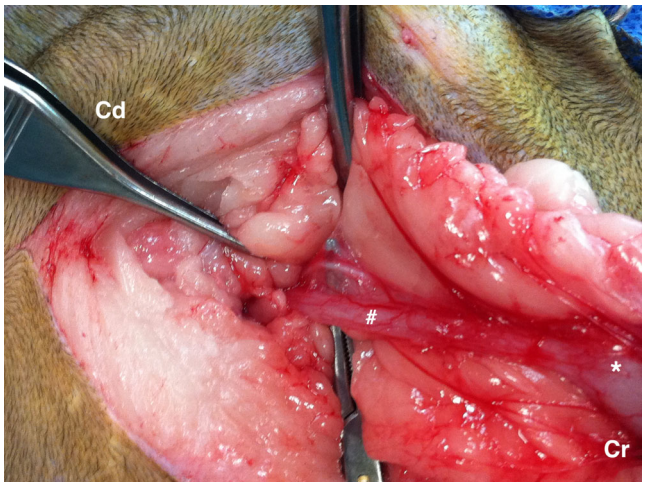

FIGURE 1 Isolation and elevation of the urethra

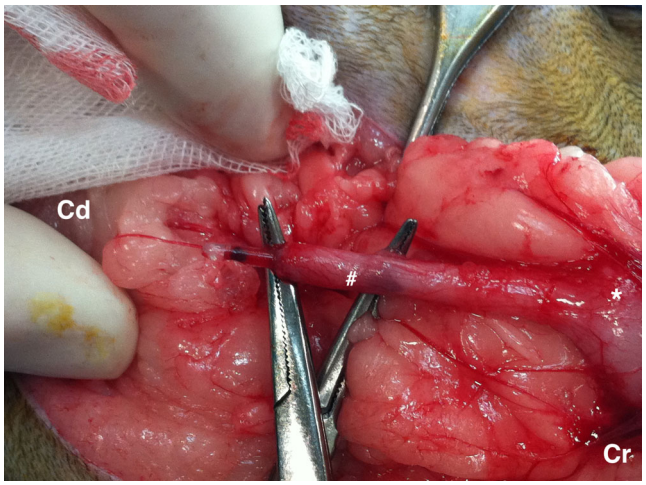

FIGURE 2 Transection of the urethra and advancement of the urinary catheter

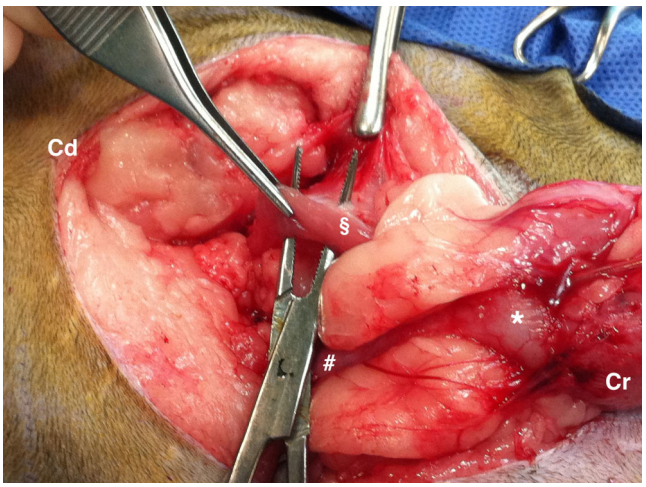

FIGURE 3 Creation of the tunnel through the mid-body of the rectus abdominis muscle. § Rectus abdominis muscle, * Urinary bladder, # urethra

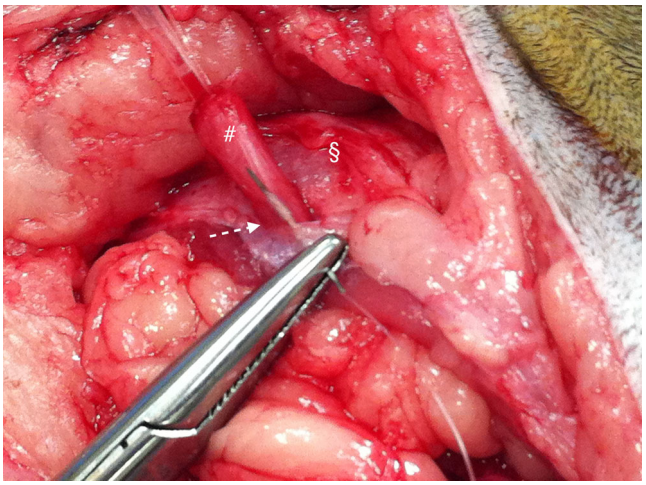

FIGURE 4 Passage of the transected urethra through the muscular tunnel. § Rectus abdominis muscle, # urethra. The white arrow indicates the muscular tunnel

fashion with 3–0 polydioxanone and leak-tested, followed by routine closure of the abdomen (Figure 6).

2.3 | Postoperative care

During the postoperative period in hospital, methadone 0.2 mg/kg IV was administered every 4 h for the first 12 h, followed by buprenorphine 0.02 mg/kg IV every 6 to 8 h (Vetergesic; Ceva Animal Health Ltd. UK) based on regular pain score checks.

An Elizabethan collar was placed before full anesthetic recovery to prevent self-trauma. Urine production and bladder size were monitored during hospitalization by ultrasound and palpation. To avoid the risk of self-trauma and to reduce the risk for stricture formation, no indwelling urinary catheter was used postoperatively.[2] Cats were hospitalized until voluntary urination had been present for at least 24 h. Discharge medications were continued based on the specific needs of the patient. Recommendations for the management of FLUTD were made for all cats that had suffered from this syndrome before presentation.

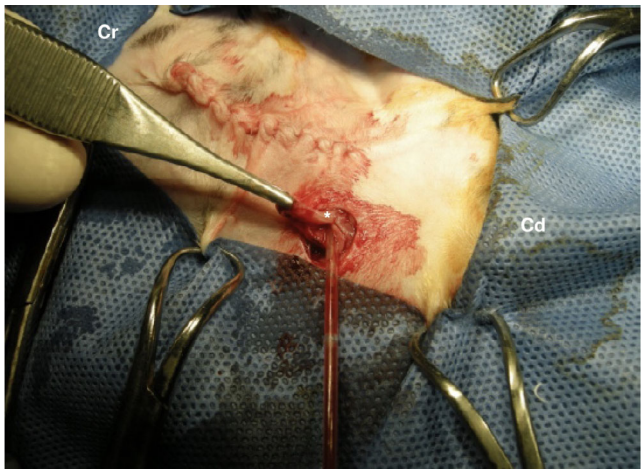

FIGURE 5 Spatulation of the urethra and creation of the stoma

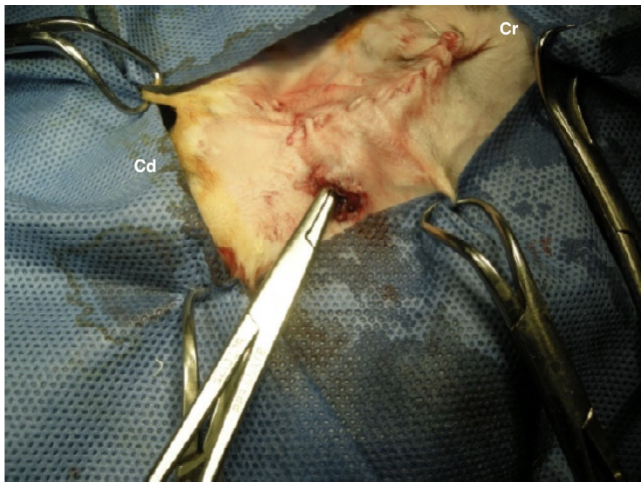

FIGURE 6 Evaluation of patency of the newly created stoma

2.4 | Follow-up

Standard recommended follow-up consisted of clinical examination 1, 2, and 4 weeks after surgery at the referring hospital. A phone survey was performed 12 months after surgery and designed to gather the following information: level of satisfaction with the surgical outcome and quality of life for the cat; recurrent signs of FLUTD including hematuria, stranguria, or periuria, and dermatitis at the surgical area; and the presence of urinary continence. The owners were also asked whether they had visited a veterinarian due to presumed recurrence of the initial problem. In those cases, the referring general practitioner was contacted, and the results of the exams performed were recorded.

3 | RESULTS

3.1 | Signalment

Eight castrated male cats, with a median age of 2.7 years (range, 6 months to 7 years), were included in the study. Seven were domestic shorthair cats, and one was a Maine Coon. No cats were excluded from the study.

3.2 | Indication for surgery

Seven cats presented with a history of recurrent urethral obstruction despite previous PU surgery performed by a general practitioner, and one presented with a suspected traumatic urethral stricture secondary to a suspected bite wound. Positive contrast retrograde urethrography was performed in all cats. For five of these cats, the level and the extent of the stricture/damage was revealed on positive contrast urethrography; two cats required intraoperative normograde urethroscopy to determine the location of the stricture.

3.3 | Surgical technique

The mPPU was performed by the same surgeon in all cases. Localization of the prepubic urethra and preservation of the

TABLE 1 Clinical Data collected on 8 Cats Undergoing mPPU

Case	Breed	Age (months)	Sex	Weight at presentation	BCS	Problem	Previous PU	Early complications	Late complications	Weight at revision	Follow-up (months)	Outcome
1	DSH	36	MN	3.3	3/5	Stenosis	Yes	Dermatitis, incontinence	Hematuria, dysuria		84	Excellent
2	DSH	6	MN	3.0	2/5	Stenosis	Yes	Dermatitis, incontinence	Stoma revision	4.8	32	Excellent
3	DSH	11	MN	5.0	4/5	Stenosis	Yes	Dermatitis, incontinence	—		32	Excellent
4	DSH	48	MN	4.5	2/5	Stenosis	Yes	Dermatitis, incontinence	Hematuria, dysuria		23	Excellent
5	DSH	12	MN	5.0	4/5	Stenosis	Yes	Dermatitis, incontinence	Stoma revision	6.5	13	Excellent
6	DSH	60	MN	5.5	3/5	Stenosis	Yes	Dermatitis, incontinence	—		13	Excellent
7	DSH	9	MN	2.1	2/5	Perineal Wound	No	Dermatitis, incontinence	—		15	Excellent
8	Maine Coon	84	MN	7.2	4	Stenosis	Yes	Dermatitis, incontinence	—		14	Excellent

Abbreviations: BCS, body condition score; DSH, domestic short hair; MN, male, neutered.

neurovascular component were easily performed in all patients. In all cases, the urethral length allowed the creation of the muscular tunnel and the prepubic stoma without excessive urethral tension and kinking.

The procedure was well tolerated by all patients, and no intraoperative complications were documented. Urinary retention or dysuria was not reported in the perioperative period. All cats urinated voluntarily within 24 h of surgery and remained hospitalized for at least 24 h for analgesia and monitoring purposes.

All cats were discharged with a course of oral meloxicam (Metacam; Boehringer Ingelheim Ltd, UK) 0.05 mg/kg for 7 days once daily. Urinary tract infection was confirmed by positive bacterial culture and sensitivity analysis in three cases. A 7-day course of potentiated amoxicillin and clavulanic acid (Synulox; Pfizer Ltd, UK) 20 mg/kg orally for 7 days twice daily was prescribed in those cases per culture results.

3.4 | Follow-up

The follow-up period ranged from 13 to 84 months, with a mean duration of follow-up of 28 months. All cats were reexamined 7 days after surgery and were found to have patent urethral stomas with no evidence of stricture. Self-limiting skin urine scalding around the stoma, associated with mild urinary incontinence during the recumbent phase, was present in all the patients. The peristomal dermatitis was managed with the application of Vaseline over the affected area around the stoma. No treatment was prescribed for incontinence.

At 2-week follow-up (range 12 to 16 days; mean 15 days), skin sutures were removed. In all cases, the stoma was patent, and peristomal dermatitis and urinary incontinence had resolved. At 4-week follow-up (range 29 to 35 days; mean 31 days), no complications were noted on patient examination or reported by the owners.

Following these initial three rechecks at the hospital, all cats were followed by a phone questionnaire and, when available, clinical notes from the referring veterinarian for at least 12 months after the surgical procedure were collected. All patients were alive at the end of the follow-up period.

3.5 | Outcomes

During the first 12 months following surgery, three cats (3/8) were reported to have one, two, and three episodes of hematuria and dysuria, respectively. These episodes were managed successfully by the referring general practitioner by means of dietary management in two cases and medications (antibiotics and nonsteroidal anti-inflammatory drugs) in one case. Detailed information about these cases was not available and not reported in the clinical history.

Two patients (2/8) were represented due to recurrence of persistent dysuria and pollakiuria and eventually required surgical revision at 5 and 6 months after surgery. Clinical examination identified a substantial weight gain from 3 to 4.8 kg and 5 to 6.5 kg, respectively (Table 1). The weight gain translated to increased caudal abdominal fatty skin folds that enfolded and obstructed the urethrostomy site. Peristomal and skin fold dermatitis and urine scalding were also present. Complete hematology, serum biochemistry, and urine analysis and culture were performed with no remarkable abnormalities.

Surgical excision of the skin fold around the stoma was performed; an adequate-sized urinary catheter allowed identification of the stoma. The excess skin was removed to avoid tension around the stoma. A dietary correction was also discussed at discharge (Table 1).

4 | DISCUSSION

The major indications to perform PPU encountered in our study were like those previously described.[9,15] In seven cases (7/8), mPPU was used to revise complications associated with a previous PU and in one case (1/8) to resolve urethral stenosis following presumptive traumatic catheterization. In all cases, preoperative diagnostics localized the urethral damage at the level of the ischial arch, proximal to the previously performed PU or bulbourethral glands, necessitating urethrostomy cranial to the pubis. Prepubic urethrostomy is indicated for permanent relief of recurrent or nonresolvable urethral obstruction affecting the urethra proximal to the bulbourethral glands. Potential causes of urethral obstruction or trauma include urethral strictures, urethral neoplasia, and iatrogenic urethral disruption through inappropriate urethral catheterization, among others.[3–5,8,9]

Proxima urethral lesions in cats have also been associated with inappropriate catheterization techniques, anesthetic plans, and or equipment to restore urethral patency (e.g., cat urinary catheter).[15,16] We suspect that seven cats in this study might have been catheterized multiple times, and the repeated catheterization might have exacerbated urethral inflammation, trauma, and led to subsequent stricture. Recurrent obstruction following PU in cats should be presumed to be at the level of the PU stoma, as this population of cats demonstrates. Contrast urethrography is a valuable tool to evaluate the entire urethral preoperatively.

McCully initially described the PPU technique in 1955, and several modifications have been published over

the past 60 years.[4] Spatulating the free end of the urethra to reduce the risk of strictures at the stoma site, as proposed by Mendham, improved the diameter and altered its position from medial to lateral to the midline.[3]

The creation of the muscular tunnel within the rectus abdominis muscle, as reported here, is a further modification of this latter technique. Modified PPU was well tolerated by all patients and allowed for straightforward creation of a patent stoma yielding voluntary urination within 24 h of surgery. Clinical signs associated with urethral obstruction were resolved in all cats following mPPU.

In this cohort of cats undergoing mPPU, eight experienced postoperative and self-limiting peristomal urine scalding and urinary incontinence. Two cats (2/8) experienced recurrent hematuria and dysuria, and two (2/8) required surgical revision due to stoma obstruction. Peristomal dermatitis and urinary incontinence were documented in all cats at the time of the first check-up, 7 days after discharge. Peristomal dermatitis is commonly reported in the early phase of any type of urethrostomy,[8,9] and it is usually associated with urinary incontinence following urethrostomy. Resolution of peristomal dermatitis may be seen once the cat adopts an altered urination posture and urinary incontinence resolves. In our study, peristomal dermatitis resolved with the resolution of the urinary incontinence. Local application of Vaseline was recommended to all patients to protect the skin around the stoma until resolution of urinary incontinence.

For all cats, urinary incontinence was described by the owners as intermittent when recumbent and was not reported while standing or walking phase. Temporary urinary incontinence is occasionally seen after all types of urethrostomies for reasons that are not fully understood.[2] It has historically been attributed to excessive dissection in the vicinity of the pelvic plexus and pudendal nerve and/or acute postoperative inflammatory process affecting the bladder and the perineum.[2,8] In this cohort, urinary incontinence and peristomal dermatitis were resolved entirely at the second recheck without further medical or surgical intervention.

Recurrent episodes of dysuria and hematuria occurred in three cats postoperatively. Dysuria and hematuria may represent a reoccurrence of the original disease (FLUTD) that led to surgical intervention in the first instance, as it is well known that no surgical technique will resolve underlying FLUTD.[17] Alternatively, the shortened urethra and the wider stoma might have predisposed the cat to the development of urinary infections (UTIs). Also, this point could not be investigated since the cats were seen by the referring general practitioner and no investigation was performed.

Two cats experienced a major complication that required surgical intervention 5 and 6 months after mPPU, respectively. Both cats were presented with dysuria, pollakiuria, peristomal dermatitis, and a substantial weight gain. The clinical signs appeared to be caused by fatty skin folds that enfolded over the urethrostomy site and impaired normal urine flow.

This complication was reported in a previous study where pendulous skin folds became contaminated with urine and created intertriginous dermatitis, predisposing the cats to recurrent UTIs.[7] Both cats underwent surgical revision consisting of the removal of the excess skin folds around the stoma. At the time of surgery, the stoma appeared patent and did not require revision.

Five cats in our cohort required additional care due to complications that could have been avoided with a targeted and strict diet. It is therefore essential to implement and discuss with the owners the importance of correct dietary management. Urinary continence is primarily maintained by the constant tone of EUS and IUS muscles. PPU requires a more extensive resection of the urethra compared to other urethrostomies, removing a substantial of the EUS and increasing the risk of postoperative urinary incontinence.[10]

By tunneling the free end of the urethra within the fibers of the rectus abdominis muscle, we attempted to improve muscle tone lost by the resection of the distal EUS. Contraction of the rectus abdominus muscle increases during standing as part of the abdominal pressaction to support the abdominal wall and viscera.

In our study, the compression provided by the contraction of the rectus abdominis muscle fibers seemed enough to avoid urine leaking and appeared to be easily overcome by the detrusor muscle, allowing voluntary urination.

At the last check, all patients were reported to have full urinary continence during recumbency and standing. Urine was passed freely through the urethral meatus with no evidence of urine outflow obstruction. The owners reported being completely satisfied with the outcome of the procedure and the quality of life of their pets.

Limitations of this study include the small number of patients included, lack of a control group, and its retrospective nature. The hypothesis that urethral tunneling would increase urethral intraluminal pressure was not objectively evaluated and required further investigation, potentially by urethral pressure profilometry.

5 | CONCLUSION

The ease of execution and the promising long-term outcomes following mPPU as reported in this cohort may

encourage surgeons to consider this technique in cats with proximal urethral obstruction that cannot be relieved otherwise.

CONFLICT OF INTEREST

The authors declare no conflicts of interest.

AUTHOR CONTRIBUTIONS

Luca Bresciani and Andrea Mosca: Acquired, analyzed, and interpreted the data, wrote and corrected the different versions. Romussi Stefano: Designed the study, corrected, and approved the final version.

ORCID

Luca Bresciani https://orcid.org/0000-0002-7199-7114
Andrea Mosca https://orcid.org/0000-0001-5891-1710
Stefano Romussi https://orcid.org/0000-0002-0283-2770

REFERENCES

1. Nye AK, Luther JK. Feline perineal urethrostomy: a review of past and present literature. *Top Companion Anim Med*. 2018; 33(3):77-82.
2. Ladlow JF. Urethra. In: Langley-Hobbs SJ, Demetriou JL, Ladlow JF, eds. *Feline Soft Tissue and General Surgery*. Saunders/Elsevier; 2014:433-446.
3. Mendham JH. A description and evaluation of antepubic urethrostomy in the male cat. *J Small Anim Pract*. 1970;11(11): 709-721.
4. McCully RM. Antepubic urethrostomy for the relief of recurrent urethral obstruction in the male cat. *J Am Vet Med Assoc*. 1955;126(936):173-179.
5. Emms SG. Antepubic urethrostomy in a cat. *Aust Vet J*. 1987; 64(12):384-385.
6. McLaren I. Prepubic urethrostomy involving transplantation of the prepuce in the cat. *Vet Rec*. 1988;122(15):363.
7. Bradley RL. Prepubic urethrostomy. An acceptable urinary diversion technique. *Probl Vet Med*. 1989;1(1):120-127.
8. Baines SJ, Rennie S, White RSA. Prepubic urethrostomy: a long-term study in 16 cats. *Vet Surg*. 2001;30(2):107-113.
9. Seneviratne M, Stamenova P, Lee K. Comparison of surgical indications and short- and long-term complications in 56 cats undergoing perineal, transpelvic or prepubic urethrostomy. *J Feline Med Surg*. 2020;23:477-486.
10. Cullen WC, Fletcher TF, Bradley WF. Morphometry of the male feline pelvic urethra. *J Urol*. 1983;129(1):186-189.
11. Wang B, Bhadra N, Grill WM. Functional anatomy of the male feline urethra: morphological and physiological correlations. *J Urol*. 1999;161(2):654-659.
12. Cuddy LC, McAlinden AB. Urethra. In: Johnston SA, Tobias MK, eds. *Veterinary Surgery: Small Animal Expert Consult*. 2nd ed. Saunders/Elsevier; 2017:2234-2253.
13. Glenn JF, Anderson EE. Distal tunnel ureteral reimplantation. *J Urol*. 1967;97(4):623-626.
14. Fielding IM, Sutton AP, Newman HR. Ureteroneocystostomy: the mucosal trough technique. *J Urol*. 1970;103(6):740-745.
15. Sousa-Filho RP, Nunes-Pinheiro DC, Sampaio KO, da Silva EC, Cavalcanti GA, da Cunha MGMM. Clinical outcomes of 28 cats 12–24 months after urethrostomy. *J Feline Med Surg*. 2020;22(10):890-897.
16. Corgozinho KB, de Souza HJM, Pereira AN, et al. Catheter-induced urethral trauma in cats with urethral obstruction. *J Feline Med Surg*. 2007;9(6):481-486.
17. Joseph WB, Delmar RF, David JP, Cari AO, Jeanne AB, Scott AB. Pathophysiology of urethral obstruction. *Vet Clin North Am Small Anim Pract*. 1996;26(2):255-264.

How to cite this article: Bresciani L, Mosca A, Romussi S. Modified prepubic urethrostomy with body wall tunneling: Description of technique and long-term outcome in eight male cats. *Veterinary Surgery*. 2022;51(2):353-360. doi:10.1111/vsu.13747