Received: 24 April 2020 | Revised: 13 October 2021 | Accepted: 14 January 2022

DOI: 10.1111/vsu.13778

ORIGINAL ARTICLE - CLINICAL

WILEY

Comparison of immediate and short-term outcomes of cricoarytenoid and thyroarytenoid lateralization in dogs with idiopathic laryngeal paralysis

Dario Drudi DVM[1] | **Marta L. P. Lisi DVM, PhD**[1] | **Paolo Sommaruga DVM**[1] | **Lavinia E. Chiti DVM**[2] | **Federico Massari DVM, DECVS**[1]

[1]Clinica Veterinaria Nervianese, Milan, Italy

[2]Dipartimento di Medicina Veterinaria, Università degli Studi di Milano, Milan, Italy

Correspondence
Dario Drudi, Clinica Veterinaria Nervianese, Via Giulio Cesare Lampugnani 3, 20014 Nerviano, Milan, Italy.
Email: dario.drudi92@gmail.com

Abstract

Objective: To compare the immediate and short-term outcomes of thyroarytenoid lateralization (TAL) and cricoarytenoid lateralization (CAL) for the treatment of canine laryngeal paralysis in dogs.

Study design: A prospective, clinical trial.

Animals: Fourteen client-owned dogs referred to our hospital because of bilateral laryngeal paralysis.

Methods: Dogs with confirmed laryngeal paralysis were randomly assigned to the CAL or TAL group. Video images of the rima glottidis obtained preoperatively, immediately postoperatively (t0), and 15 days postoperatively (t1) were digitized. The rima glottidis area was measured using image-analysis software. An increase in the rima glottidis area was expressed as a percentage of the preoperative area.

Results: The rima glottidis area increased by a mean of 152% at t0 and 127% at t1 for the TAL group and 205% at t0 and 199% at t1 for the CAL group compared with preoperative values. The increase in the rima glottidis area differed ($P < .05$) between the 2 groups at all postoperative time points. A reduction of the area occurred at t1 in both groups. There was no difference between t0 and t1 ($P > .05$) in the CAL group but there was a large difference ($P < .05$) in the TAL group.

Conclusion: Cricoarytenoid lateralization and TAL were both effective for surgical abduction of the arytenoid cartilage. Although a reduction ($P < .05$) in the rima glottidis area occurred in the TAL group at t1, we observed no associated clinical signs.

Clinical significance: Cricoarytenoid lateralization and TAL result in good short-term outcomes in dogs with laryngeal paralysis.

1 | INTRODUCTION

Acquired laryngeal paralysis is a complex multifactorial disease resulting in atrophy of the cricoarytenoideus dorsalis muscle and failure of the arytenoid cartilages to abduct during inspiration.[1,2] This disorder usually affects large-breed dogs, such as Labrador retrievers, Irish setters, Newfoundland dogs, and golden retrievers.[3–6]

Common clinical signs include dyspnea, inspiratory stridor, exercise intolerance, and dysphonia.[2,3] Laryngeal paralysis was thought to be caused by damage to the branches of the recurrent laryngeal nerve. However, it was recently shown to be part of a generalized neuromuscular disorder, and geriatric onset laryngeal paralysis polyneuropathy (GOLPP) was suggested as a more accurate term.[7] A tentative diagnosis of GOLPP is made when other causes, such as trauma, immune-mediated disease,[7] and congenital laryngeal paralysis, are ruled out.Branches of the recurrent laryngeal nerve are affected, including the pararecurrent laryngeal nerves, which innervate the cervical and cranial thoracic esophagus and trachea.[8] Esophageal dysfunction, including megaesophagus, is a frequent finding in dogs with laryngeal paralysis and is a risk factor for aspiration pneumonia.[4,7,9,10] Hypothyroidism is also commonly associated with laryngeal paralysis, although treatment of the endocrine problem does not resolve laryngeal paralysis.[2,11]Surgical techniques to treat laryngeal paralysis in dogs include the following: unilateral arytenoid cartilage lateralization, bilateral arytenoid lateralization,[11,12] castellated laryngofissure,[13,14] partial laryngectomy,[15] and laryngeal reinnervation.[16] Cricoarytenoid lateralization (CAL) is the procedure most commonly used, while thyroarytenoid lateralization (TAL) is less common.[17] Other techniques have been described but more studies are needed to validate their usefulness.[18–20] Surgical treatment aims to increase the rima glottidis area just enough to improve airflow without increasing the risk of aspiration pneumonia. The efficacy of these techniques was reported in live anesthetized dogs with laryngeal paralysis and in canine cadavers.[21–24] A larger increase ($P < .05$) in the rima glottidis area was seen in dogs that underwent CAL compared with TAL.[24] Although the medium- and long-term clinical outcomes of these surgical techniques have been described, as far as the authors are aware, studies describing endoscopic imaging of the glottis and the relative increase in the rima glottidis area during the immediate and short-term postoperative period are lacking. We feel that the results of the 2 surgical techniques differ in the immediate and short-term postoperative period, and surgeons should be aware of the differences when choosing between the methods.Our goal was to investigate and compare the relative increase in the rima glottidis area after CAL and TAL and the subsequent decrease in the medium-term postoperative (15 days) period in anesthetized dogs with bilateral laryngeal paralysis.

2 | MATERIALS AND METHODS

Fourteen dogs referred because of bilateral laryngeal paralysis were included in the study. The owners were informed of the study protocol and signed a consent form.Criteria for inclusion in the study were: > 8 years of age, > 20 kg body weight, complete history, and normal results of physical and neurologic examinations, serum biochemistry analysis including serum thyroxine (T4), and thyroid-stimulating hormone (TSH) concentrations, and thoracic radiography.[23]Laryngeal endoscopy was carried out after sedation of the dogs to confirm bilateral laryngeal paralysis. The rima glottidis area was measured preoperatively, immediately postoperatively (t0), and 15 days postoperatively (t1) in both groups, and the results were compared. The relative increase in the rima glottidis area measured at t0 and t1 were expressed as percentages of the area measured preoperatively.Dogs were assigned randomly to either CAL or TAL treatment using a software program (SPSS 24, IBM 161. Corp., Armonk, New York). All of the operations were performed by the same board-certified surgeon. The surgical time was not recorded.All dogs were premedicated with 0.2 mg/kg of butorphanol and 2 mcg/kg of dexmedetomidine administered IV.[25] Doxapram was not used to assess laryngeal function, although its use is widely described.[26–29] Anesthesia was induced with slow administration of 2-4 mg/kg of propofol administered IV to effect to assess laryngeal function.The larynx was observed and imaged with the dogs positioned in sternal recumbency and lightly anesthetized as evidenced by an intact gag reflex. Failure to abduct the arytenoid cartilages and vocal folds on inspiration, as determined by endoscopy, was considered diagnostic for laryngeal paralysis. An HD Storz rigid 30° (Karl Storz Veterinary Endoscopy, Goleta, California) video endoscope was used to record images of the larynx and rima glottidis before and after surgery with the tip of the endoscope placed at the caudal border of the soft palate to allow repeated endoscopic evaluation at a defined distance from the larynx. The larynx and the epiglottis were not manipulated to visualize the rima glottidis area.After the laryngeal assessment, propofol was administered to effect, the dogs wereintubated, and anesthesia was maintained using isoflurane or sevoflurane based on the preference of the anesthesiologist. All dogs received 22 mg/kg of cefazolin administered IV after induction of general anesthesia. The surgical approach was through an incision made in the left lateral cervical region ventral to the jugular vein at its bifurcation into the maxillary and linguofacial veins. The platysma muscle and subcutaneous tissues were incised to expose the left wing of the thyroid cartilage. The thyropharyngeus muscle was dissected longitudinally, and the cricothyroid articulation was left intact.A stay suture (USP 2-0 polydioxanone) was applied to the dorsal midsection of the thyroid cartilage to abduct it laterally. The muscular process of the arytenoid cartilage was then exposed, allowing the cricoarytenoideus dorsalis muscle to be identified and transected. This muscle was used as a

reference point for the identification of its insertion into the muscular process of the cricoid cartilage, and the cricoarytenoid articulation was partially disarticulated with a small periosteal elevator as described by Greenberg et al. in order to preserve the cranial aspect of the joint capsule.[30] The suture prosthesis consisted of 3.5 metric (USP 0) monofilament polypropylene, which was placed using a taper-point needle in all cases. In dogs undergoing TAL, the needle was passed in a lateromedial direction through the caudodorsal border of the thyroid cartilage and tied to the muscular process of the arytenoid cartilage in a horizontal suture pattern, tightening the suture until resistance was felt. In dogs undergoing CAL, the needle was passed in a caudocranial and mediolateral direction through the caudal edge of the cricoid cartilage. The needle exited a few millimeters caudal to the cranial border to the cranial border OF THE CRYCOID CARTILAGE and was then passed through the muscular process of the arytenoid cartilage and tied until resistance dictated by the remaining joint capsule was felt.The thyropharyngeal muscle was sutured in position, and the platysma muscle, subcutaneous tissues, and skin were closed routinely. The larynx was then re-examined after extubation during recovery from anesthesia, when gag reflex was present, using the same video endoscope and the same distance as described previously. The images were stored for further analysis. The dogs were hospitalized for 4 to 7 h and discharged the same day provided no complications occurred. After extubation, the heart and respiratory rates and the rectal temperature were monitored every 15 min for the first hour, every 30 min for the second hour, and immediately before discharge. Dogs were placed in a quiet cage, separated from other patients, and the clinic staff was prepared to sedate and re-evaluate the rima glottidis in dogs with severe dyspnea. All dogs received 12.5 mg/kg of amoxicillin-clavulanic acid orally, every 12 h, for 5 days in the postoperative period. Buprenorphine (15 μg/kg IV) was administered every 12 h until the time of discharge. Meloxicam (0.1 mg/kg) was administered orally for 4 days postoperatively. Owners were instructed to feed only wet food and immediately contact the clinic if the dog was coughing or had respiratory distress. All dogs underwent a thorough evaluation by the surgeon or the resident surgeon 15 days postoperatively. The clinical examination included measurement of rectal temperature and heart and respiratory rates and auscultation of the heart and lungs.The dogs were anesthetized using the same anesthetic protocol used for the diagnosis. The endoscopic images obtained were saved for the analysis of the rima glottidis area using Scion Image analysis software (Meyer Instruments Inc, Langham Creek, Houston, Texas) (Figures 1 and 2).

2.1 | STATISTICAL ANALYSIS

Normal distribution of all data from the 2 groups was confirmed using the Kolmogorov-Smirnov test, and paired *t*-tests were used to compare the anatomic and physiologic variables measured before and after surgery and 15 days postoperatively. Differences were considered significant at $P < .05$. The data were analyzed using statistical software (SPSS 24).

3 | RESULTS

The mean age at the time of referral was 11.3 years (range, 9-13 years), and there were 7 Labrador retrievers, 3 mixed-breed dogs, 1 Golden retriever, 1 American Staffordshire terrier, 1 Epagneul Breton, and 1 Australian

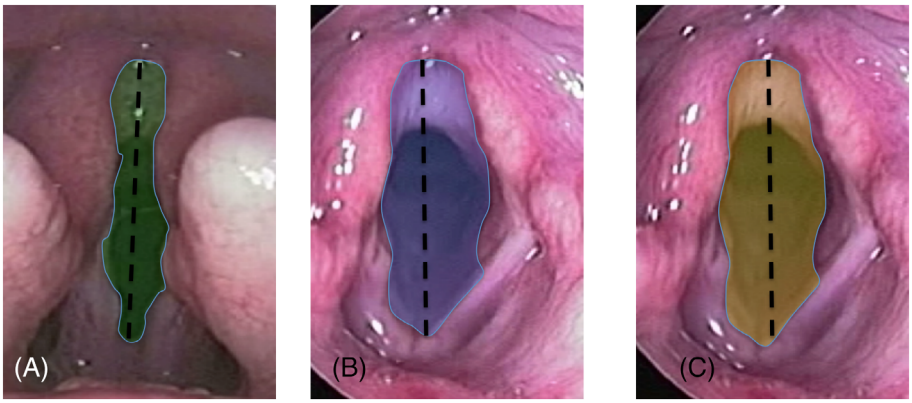

FIGURE 1 Video-endoscopic images showing the preoperative rima glottidis area (A) compared with the area immediately postoperatively (t0, B) and 15 days postoperatively (t1, C) in a dog that underwent cricoarytenoid lateralization. The figures show how the rima glottidis area was measured in all dogs. The dotted line is the dorsoventral measurement that was used as the unmodified measurement at different time points in all images. The green, blue, and yellow areas were used to calculate changes in the area at t0 and t1 in all dogs

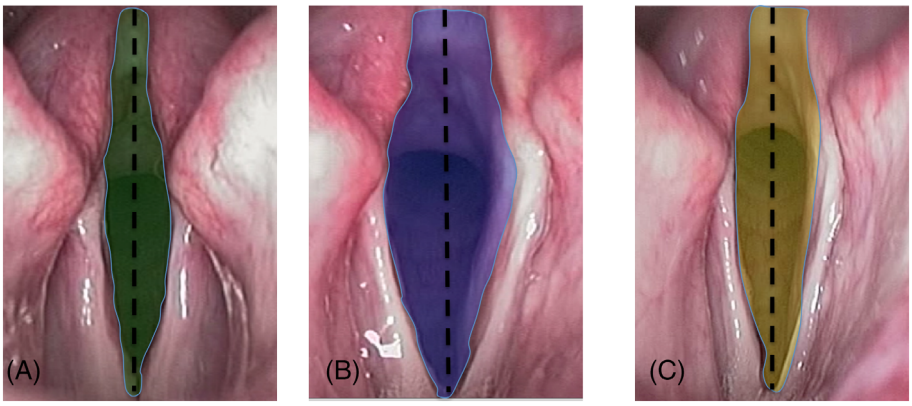

FIGURE 2 Video-endoscopic images showing the preoperative rima glottidis area (A) compared with the area immediately postoperatively (t0, B) and 15 days postoperatively (t1, C) in a dog that underwent thyroarytenoid lateralization. The figures show how the rima glottidis area was measured in all dogs. The dotted line is the dorsoventral measurement that was used as the unmodified measurement at different time points in all images. The green, blue, and yellow areas were used to calculate changes in the area at t0 and t1 in all dogs

TABLE 1 Signalment and increase in the rima glottidis area at t0 and t1 in dogs that underwent TAL or CAL

Dog	Sex	Weight	Technique used	Breed	Age (years)	Pre-Op to Post-Op T0 (% increase)	Pre-Op to Post-Op T1 (% increase)
1	M	23	CAL	Epagneul Breton	13	180	181
2	M	27	CAL	Mixed breed	11	211	198
3	FN	35	CAL	Golden retriever	9	248	240
4	FN	37	CAL	Labrador retriever	12	219	222
5	FN	34	CAL	Labrador retriever	13	183	169
6	MC	29	CAL	Australian Shepherd	10	193	192
7	MC	29	CAL	Labrador retriever	9	204	196
8	FN	40	TAL	Mixed breed	12	153	132
9	FN	38	TAL	Labrador retriever	11,5	128	117
10	M	26	TAL	Mixed breed	11	147	133
11	M	41	TAL	Labrador retriever	12	139	100
12	FN	30	TAL	Labrador retriever	13	164	136
13	MC	38	TAL	Labrador retriever	12	146	112
14	FN	29	TAL	American Staffordshire	11	185	162

shepherd dog. Seven dogs were female (all spayed), and 7 were male (3 neutered). The mean weight ± standard deviation of the dogs was 33.3 ± 5.8 kg (range, 23-41 kg). All dogs were referred because of inspiratory stridor and suspected bilateral laryngeal paralysis (Table 1) and had a history of exercise intolerance and a decreased quality of life, and some had episodes of acute dyspnea. A total of 57% of cases had changes in phonation. Serum concentrations of T4 and TSH were normal, and thoracic radiography and neurologic examination revealed no abnormalities. In all dogs, endoscopic evaluation of the larynx showed bilateral paralysis of the arytenoid cartilages and no laryngeal collapse. The increases in the rima glottidis area in the CAL group were 180 to 248% (mean ± SD, 205 ± 26% at t0 and 169 to 240% (mean ± SD, 200 ± 26%) at t1. In the TAL group, the increases were 128 to 185% (mean ± SD, 152 ± 18%) at t0 and 100 to 162% (mean ± SD, 127 ± 20%) at t1. The decrease from t0 to t1 was a mean of 5% in the CAL group and 25% in the TAL group. The results of the 2 groups differed at both time points ($P < .05$). Furthermore, in the CAL group, the areas measured at t0 and t1 differed from the preoperative area ($P = .002$ and $P = .002$, respectively), but the areas at t0 and t1 did not differ ($P = .064$). In the TAL group, the preoperative area differed from the area measured at t0 ($P = .014$). The areas at t0 and t1 differed

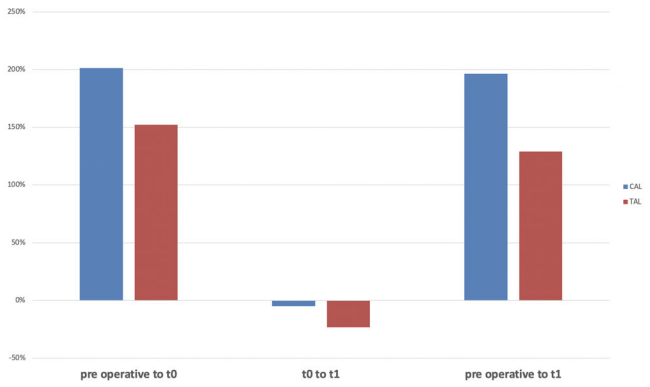

FIGURE 3 Relative increases (preoperatively to t0 and preoperatively to t1) and decreases (t0 to t1) in the rima glottidis area in dogs that underwent TAL (red) or CAL (blue)

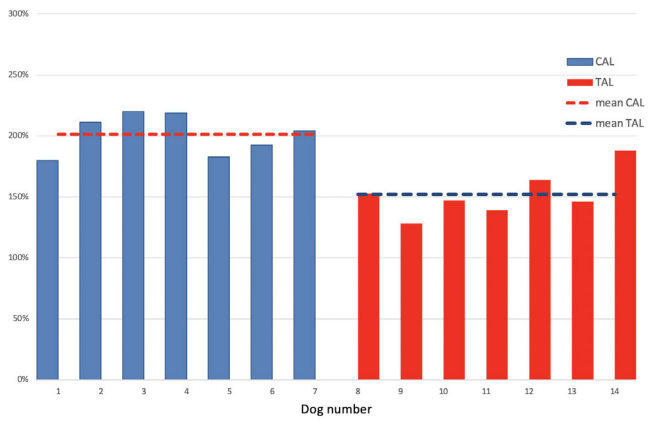

FIGURE 4 Relative increases (preoperatively to t0) in the rima glottidis area in dogs that underwent TAL (red) or CAL (blue)

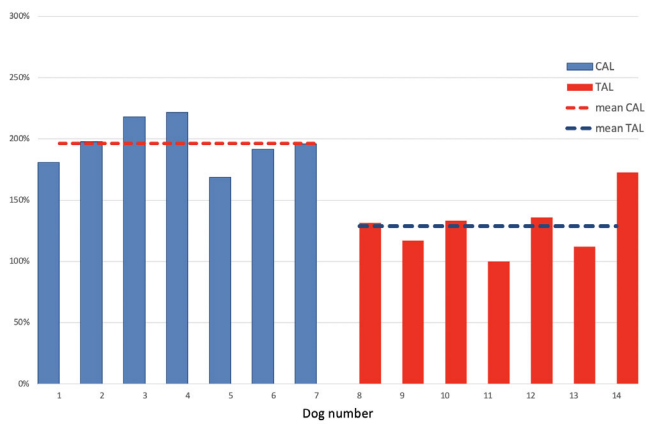

FIGURE 5 Relative increases (preoperatively to t1) in the rima glottidis area in dogs that underwent TAL (red) or CAL (blue)

($P = .04$), and the preoperative and t1 areas did not differ ($P = .072$) (Figures 3-5).No postoperative complications occurred, and all dogs were discharged from the clinic on the day of the procedure. The dogs underwent a thorough evaluation by the surgeon who operated or the attending surgical resident 15 days postoperatively. The clinical examination included measurement of rectal temperature and the heart and respiratory rates, and pulmonary auscultation. No dog showed evidence of inspiratory stridor, and the owners reported a reduction in respiratory noise and an increase in exercise tolerance. Thoracic radiography was not conducted postoperatively because the physical examination revealed no signs to support a diagnosis of aspiration pneumonia or megaesophagus. Breathing did not differ clinically between the TAL and CAL groups.

4 | DISCUSSION

Signalment, history, and the results of physical examination and laboratory testing were diagnostic of idiopathic laryngeal paralysis in all dogs.[3,5,6,8,17] Thyroid function tests and neurologic and radiographic examinations were unremarkable and in agreement with the findings of other studies.[1,8,10] A male predilection for this disorder has been reported but was not found in the present study.[2,5,17] Of the large and giant breed dogs, the Labrador retriever was the most commonly affected breed and represented 50% of our population.A reduction in the rima glottidis area ($P < .05$) occurred at t1 in the TAL group and there was a smaller decrease ($P > .05$) in the CAL group. However, this finding was not associated with clinical signs in either group. The reduction in the rima glottidis area seen at t1 may have been attributable to the anatomic conformation of the larynx and healing of the cartilage. Changes in the anatomic position, conformation, and stability of the cricoid cartilage did not occur from t0 to t1 in the CAL group ($P > .05$).However, the strong decrease in the rima glottidis area from t0 to t1 in the TAL group ($P < .05$) was likely associated with abduction of the thyroid cartilage to access the cricoarytenoideus dorsalis muscle and the cricoarytenoid articulation during surgery. Fixation of the thyropharyngeus muscle in its normal anatomic position allowed adduction of the thyroid cartilage to its physiologic position near the cricoid cartilage. This movement may have resulted in the relaxation of the tension suture between the thyroid cartilage and the muscular process of the arytenoid cartilage, thereby decreasing the rima glottidis area. In the authors' experience, limiting the decrease in the rima glottidis area by exerting more tension on the suture during TAL should be feasible, but the amount of tension required, and the subsequent results are beyond the scope of this study.In agreement with other studies, both techniques resulted in a notable increase in the rima glottidis area immediately

after surgery.[1,24,30,31] Although the increase in the rima glottidis area was small in the TAL group at t1 ($P > .05$), there were no postoperative abnormalities in any of the dogs, which confirmed that surgery was successful in the stabilization of the arytenoid cartilage.All owners reported decreased respiratory noise and increased exercise tolerance at t1, and the clinical examination showed that all dogs were in good condition. There were no apparent differences between the 2 procedures concerning the clinical outcome and exercise tolerance. This suggests that, although CAL resulted in a larger increase in the rima glottidis area ($P < .05$), it provided no short- or medium-term advantage over TAL.Some studies have suggested that CAL may increase the risk of aspiration pneumonia because the epiglottis does not cover the entire rima glottidis.[8,10,32–34] None of our cases developed signs indicating aspiration pneumonia or other complications in the 15-day postoperative period. A study to determine whether complications occur in the long-term would be beneficial.Limitations of the study included the small number of dogs in each group. There were also no data on the long-term outcome of CAL and TAL in dogs with laryngeal paralysis, and functional testing to rule out megaesophagus was not done. Finally, clinical improvement was evaluated subjectively after surgery rather than using a standardized questionnaire.Both CAL and TAL resulted in good clinical outcomes in dogs with laryngeal paralysis.[35] Both techniques led to the resolution of clinical signs, although CAL yielded a larger ($P < .05$) increase in the rima glottidis area. A study to determine whether changes in the rima glottidis area and associated complications occur in the long term is desirable.

ACKNOWLEDGMENTS

Author Contributions: Drudi D, DVM: Wrote the paper, performed the measurements, analyzed and interpreted the data, drafted the manuscript, and read and approved the final manuscript. Lisi MLP, DVM, PhD: Performed anesthesia, read and approved the final manuscript. Sommaruga P, DVM: Performed anesthesia, read and approved the final manuscript. Chiti LE, DVM: Collected the data, drafted the manuscript, and read and approved the final manuscript. Massari F, DVM, DECVS: Designed the study, performed the surgery, performed the endoscopies, read and approved the final manuscript.

The authors thank Prof. Ignazio Drudi, Full Professor of Statistics, Department of Statistical Sciences "Paolo Fortunati," University of Bologna, Bologna, Italy for statistical advisory and support in data analysis.

CONFLICT OF INTEREST

The authors declare no conflicts of interest related to this report.

ORCID

Dario Drudi https://orcid.org/0000-0002-1421-3635
Lavinia E. Chiti https://orcid.org/0000-0003-2658-5660

REFERENCES

1. Gauthier CM, Monnet E. In vitro evaluation of anatomic landmarks for the placement of suture to achieve effective arytenoid cartilage abduction by means of unilateral cricoarytenoid lateralization in dogs. *Am J Vet Res*. 2014;75:602-606.
2. White RAS. Arytenoid lateralization:an assessment of technique, complications and long-term results in 62 dogs with laryngeal paralysis. *Vet Surg*. 1989;18:72.
3. MacPhail C. Laryngeal disease in dogs and cats. *Vet Clin North Am Small Anim Pract*. 2014;44:19-31.
4. MacPhail CM, Monnet E. Outcome of and postoperative complications in dogs undergoing surgical treatment of laryngeal paralysis: 140 cases (1985–1998). *J Am Vet Med Assoc*. 2001;218:1949-1956.
5. Snelling SR, Edwards GA. A retrospective study of unilateral arytenoid lateralisation in the treatment of laryngeal paralysis in 100 dogs (1992–2000). *Aust Vet J*. 2003;81:464-468.
6. Bookbinder LC, Flanders J, Bookbinder PF, Harvey HJ, Barry JS, Cheetham J. Idiopathic canine laryngeal paralysis as one sign of a diffuse polyneuropathy: an observational study of 90 cases (2007-2013). *Vet Surg*. 2016;45:320-260.
7. Stanley BJ, Hauptman JG, Fritz MC, et al. Esophageal dysfunction in dogs with idiopathic laryngeal paralysis: a controlled cohort study. *Vet Surg*. 2010;39:139-149.
8. Ogden J, Ovbey D, Saile K. Effects of preoperative cisapride on postoperative aspiration pneumonia in dogs with laryngeal paralysis. *J Small Anim Pract*. 2019;60(183–190):328-190.
9. Tart KM, Babski DM, Lee JA. Potential risks, prognostic indicators, and diagnostic and treatment modalities affecting survival in dogs with presumptive aspiration pneumonia: 125 cases (2005-2008). *J Vet Emerg Crit Care*. 2010;20:319-329.
10. Ovbey DH, Wilson DV, Bednarski RM, et al. Prevalence and risk factors for canine post-anesthetic aspiration pneumonia (1999-2009): a multi- center study. *Vet Anaesth Analg*. 2014;40(127–136):337-136.
11. Rosin E, Greenwood K. Bilateral arytenoid cartilage lateralization for laryngeal paralysis in the dog. *J Am Vet Med Assoc*. 1982;180(515–518):340.
12. Demetriou JL, Kirby BM. The effect of 2 modifications of unilateral arytenoid lateralization on rima glottidis area in dogs. *Vet Surg*. 2003;32:62-68.
13. Gourley IM, Paul H, Gregory C. Castellated laryngofissure and vocal fold resection for the treatment of laryngeal paralysis in the dog. *J Am Vet Med Assoc*. 1983;182:1084-1086.
14. Smith MM, Gourley IM, Kurpershoek CJ, et al. Evaluation of a modified castellated laryngofissure for alleviation of upper airway obstruction in dogs with laryngeal paralysis. *J Am Vet Med Assoc*. 1986;188(1279–1283):352.
15. Harvey CE, O'Brien JA. Treatment of laryngeal paralysis in dogs by partial laryngectomy. *J Am Anim Hosp Assoc*. 1982;18(551–556):355.
16. Greenfield CL, Walshaw R, Kumar K, Lowrie CT, Derksen FJ. Neuromuscular pedicle graft for restoration of arytenoid abductor function in dogs with experimentally induced laryngeal hemiplegia. *Am J Vet Res*. 1988;49:1360-1366.

17. Monnet E. Surgical treatment of laryngeal paralysis. *Vet Clin of North Am: Small an Pract*. 2016;46:709-717.
18. Sample SJ, Hardie RJ, Stein J, Webb J. Evaluation of Translaryngeal percutaneous arytenoid lateralization (TPAL) in dogs with experimentally created laryngeal paralysis. *Res Vet Sci*. 2018;117(239–245):365-245.
19. Paniello RC, Brookes S, Bhatt NK, Bijangi-Vishehsaraei K, Zhang H, Halum S. Improved adductor function after canine recurrent laryngeal nerve injury and repair using muscle progenitor cells. *Laryngoscope*. 2018;128(7):E241-E246.
20. Liu H, Pu Y, Xu Y, et al. Olfactory ensheathing cells promote physiological repair of injured recurrent laryngeal nerves and functional recovery of glottises in dogs. *Mol Cell Biochem*. 2018; 446:115-125.
21. Harvey CE. Partial laryngectomy in the dog. II. Immediate increase in glottis area obtained compared with other laryngeal procedures. *Vet Surg*. 1983;12:197-201.
22. Lozier S, Pope E. Effects of arytenoid abduction and modified castellated laryngofissure on the rima glottidis in canine cadavers. *Vet Surg*. 1992;21:195-200.
23. Lussier B, Flanders JA, Erb HN. The effect of unilateral lateralization on rima glottidis area in canine cadaver larynges. *Vet Surg*. 1996;25:121-126.
24. Griffiths LG, Sullivan M, Reid SWJ. A comparison of the effects of unilateral thyroarytenoid lateralization versus cricoarytenoid laryngoplasty in the area of the rima glottidis and clinical outcome in dogs with laryngeal paralysis. *Vet Surg*. 2001;30:359-365.
25. DeGroot WD, Tobias KM, Browning DC, Zhu X. Examination of laryngeal function of healthy dogs by using sedation protocols with dexmedetomidine. *Vet Surg*. 2020;49:124-130.
26. Labuscagne S, Zeiler GE, Dzikiti BT. Effects of chemical and mechanical stimulation on laryngeal motion during alfaxalone, thiopentone or propofol anaesthesia in healthy dogs. *Vet Anaesth Analg*. 2019;46(4):435-442.
27. Sakai DM, Martin-Flores M, Jones AK, Hayes GM, McConkey MJ, Cheetham J. Laryngeal mask airway and transient hypercapnic hyperpnea for video-endoscopic assessment of unilateral laryngeal paralysis in dogs. *Vet Surg*. 2018;47(4):543-548.
28. Radkey DI, Hardie RJ, Smith LJ. Comparison of the effects of alfaxalone and propofol with acepromazine, butorphanol and/-or doxapram on laryngeal motion and quality of examination in dogs. *Vet Anaesth Analg*. 2018;45(3):241-249.
29. Smalle TM, Hartman MJ, Bester L, Buck RK, Fosgate GT, Zeiler GE. Effects of thiopentone, propofol and alfaxalone on laryngeal motion during oral laryngoscopy in healthy dogs. *Vet Anaesth Analg*. 2017;44(3):427-434.
30. Greenberg MJ, Bureau S, Monnet E. Effects of suture tension during unilateral cricoarytenoid lateralization on canine laryngeal resistance in vitro. *Vet Surg*. 2007;36:526-532.
31. Bureau S, Monnet E. Effects of suture tension and surgical approach during unilateral arytenoid lateralization on the rima glottidis in the canine larynx. *Vet Surg*. 2002;31:589-595.
32. Perez Lopez P, Barnes DC, Nelissen P, Demetriou J. Outcome of two variations of a surgical technique performed for canine unilateral arytenoid lateralisation. *Vet Rec*. 2019; 185(9):1-8.
33. MacPhail CM. Laryngeal disease in dogs and cats: an update. *Vet Clin North Am Small Anim Pract*. 2020;50(2):295-310.
34. Wilson D, Monnet E. Risk factors for the development of aspiration pneumonia after unilateral arytenoid lateralization in dogs with laryngeal paralysis: 232 cases (1987–2012). *J Am Vet Med Ass*. 2016;248(2):188-194.
35. Sample SJ, Stilin A, Binversie EE, Baker LA, Hardie RJ. Late-onset laryngeal paralysis: owner perception of quality of life and cause of death. *Vet Med Sci*. 2020;00:1-8.

How to cite this article: Drudi D, Lisi MLP, Sommaruga P, Chiti LE, Massari F. Comparison of immediate and short-term outcomes of cricoarytenoid and thyroarytenoid lateralization in dogs with idiopathic laryngeal paralysis. *Veterinary Surgery*. 2022;51(3):482-488. doi:10.1111/vsu.13778