

*Move***FORWARD** >>>

Continuing Education for
Your Unique Journey

Whether learning a new procedure or keeping your techniques current, Movora Education is here to help you keep moving forward.

**100+ Workshops Annually**

From simple Fracture Repair to complex Total Joint Replacement.

**State-of-the-Art Training Facilities**

Continue your education at well-equipped Movora Education Centers and partner venues.

**Online Courses for All Skill Levels**

Learn wherever you are at your own pace.

**SCAN HERE****REGISTRATION OPEN**

Find your pathway online
at education.movora.com

**KYON**

CASE REPORT

Sternohyoideus-sternothyroideus muscle flap to reconstruct oronasal fistulas due to maxillary cancer in four dogs

Brittany J. Ciepluch DVM, MS, DACVS-SA¹ | Bernard Séguin DVM, MS, DACV^{2,3} | Deanna Worley DVM, DA, CVS-SA^{2,3}

¹Department of Small Animal Clinical Sciences, Animal Cancer Care and Research Center, Virginia Polytechnic Institute and State University, Roanoke, Virginia, USA

²Department of Clinical Sciences, Colorado State University, Fort Collins, Colorado, USA

³Flint Animal Cancer Center, Colorado State University, Fort Collins, Colorado, USA

Correspondence

Brittany J. Ciepluch, Department of Small Animal Clinical Sciences, Animal Cancer Care and Research Center, Virginia Polytechnic Institute and State University, 4 Riverside Circle, Roanoke, VA 24016, USA.

Email: ciepluch@vt.edu

Abstract

Objective: To describe the repair of oronasal fistulas in dogs treated for maxillary cancer, with a novel sternohyoideus-sternothyroideus muscle flap, and to report the outcome.

Animals: Client-owned dogs ($n = 4$) with oronasal fistulas related to cancer.

Study design: Short case series.

Methods: Maxillary defects were caused by tissue destruction by the tumor and tumor response to radiation therapy in two cases and a complication of caudal maxillectomy in two cases, one of which had neoadjuvant radiation therapy. All tumors were >4 cm at the level of the maxilla. Flaps were harvested by transecting the ipsilateral sternothyroideus and sternohyoideus muscles from their origin at the manubrium and costal cartilage. The muscles were rotated around the base of the cranial thyroid artery and tunneled subcutaneously in the neck and through an incision in the caudodorsal aspect of the oral cavity. The muscle flap was sutured to the edges of the oronasal fistula.

Results: The flap reached as far rostral as the level of the first premolar without tension. All dogs had clinical signs that improved postoperatively. All dogs had partial dehiscence of the flap.

Conclusion: This flap was associated with a high rate of complications; however, all flaps were used in challenging cases. Clinical signs related to oronasal fistula were improved in all dogs in this case series.

1 | INTRODUCTION

Oronasal fistulas are a potential complication following caudal maxillectomy and radiation therapy (RT) for a tumor that causes lysis of the hard palate and erosion of the oral mucosa in dogs.^{1,2} Oronasal fistulas can cause nasopharyngitis, halitosis, chronic infection, nasal regurgitation and a diminished quality of life.³

Case data from dog 1 was presented as a podium presentation at National Veterinary Conference on October 16-18 2019, Moscow, Russia, and at the ACVS Surgical Summit on October 6-9, 2017; Seattle, Washington

This is an open access article under the terms of the [Creative Commons Attribution-NonCommercial-NoDerivs](https://creativecommons.org/licenses/by-nc-nd/4.0/) License, which permits use and distribution in any medium, provided the original work is properly cited, the use is non-commercial and no modifications or adaptations are made.

© 2022 The Authors. *Veterinary Surgery* published by Wiley Periodicals LLC on behalf of American College of Veterinary Surgeons.

Although the exact role of surgery with RT for treatment of maxillary tumors has not yet been clearly defined, a combination approach has been reported, with the goal of improving local disease control.^{1,4–6} Complications were identified in 71% of dogs that received RT on oral mucosal flaps.⁷ Local healing is negatively affected by irradiation, partially due to changes in blood supply, fibroplasia, and collagen production.⁸ Oronasal fistula repair can be associated with a high rate of complications due to many factors such as tension, defect size, local tissue health including poor vascular supply, motion, and self-trauma.^{5,7}

Options for reconstructive techniques to address oronasal fistulas include use of local tissue, distant tissue, or an implant. Reconstructive techniques using local tissues, such as the angularis oris flap, are not feasible in some cases due to tumor involvement of the tissues, the tumor margin, the surgical approach or size of the RT field. Reconstructive techniques employing distant tissue have been described in the post-tumor treatment of oronasal fistulae, though, there are limitations to each of these

techniques. Microvascular transfer requires special training and equipment.⁹ The staged mandibular lip flap required two procedures.¹⁰ Furthermore, the mandibular lip might not maintain its normal blood supply in some dogs with maxillary tumors. A free auricular cartilage autograft was used for repair of a small (5 mm x 3 mm) mid-palatal defect. The bony rim of the defect was used as the graft recipient bed.¹¹ This type of recipient bed is not often present post-caudal maxillectomy. The temporalis muscle flap was used to cover a small (16 mm x 14 mm) maxillary defect in a dog with severe trismus, ventral orbitectomy and globe exenteration.¹² This flap has not been used in a dog with normal jaw motion or a globe. Reconstructive techniques that use an implant require a bony rim to retain the implants, which is often not present post-caudal maxillectomy.^{13,14} Because of the challenges with reconstruction of oronasal fistulae following cancer treatment, alternative approaches should be considered. Here, we describe a technique that uses the sternohyoideus and sternothyroideus muscles in a rotational flap to repair large oronasal fistulas.

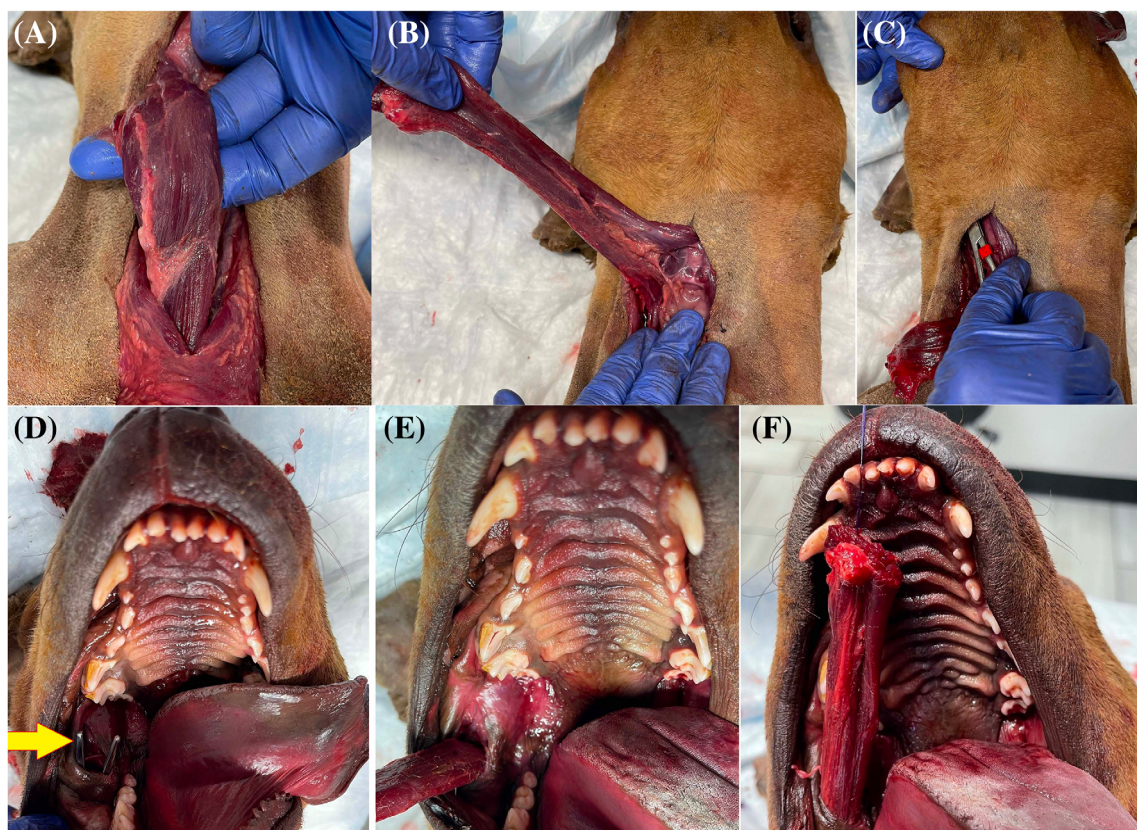


FIGURE 1 Photographs from a cadaver dog. Rostral is towards the top and caudal is towards the bottom of the image. (A) The sternohyoideus and sternothyroideus have been isolated on the right side. (B) After transecting the origin of the muscles, they have been pulled cranially and laterally to show their respective insertion on the hyoid apparatus and thyroid cartilage. (C) Using a Carmalt forceps, a tunnel was created starting close to their insertion. (D) The opening of the tunnel is made in the buccal cavity, lateral to the ramus of the mandible. The yellow arrow points to the tips of the Carmalt forceps entering the buccal cavity. Unlike the clinical cases, a cheilotomy was not performed in the cadaver. (E and F) The muscular graft has been pulled through the tunnel to bring the muscles in the oral cavity.

2 | MATERIALS AND METHODS

2.1 | Surgical technique

With the dog in dorsal recumbency, a cervical ventral midline incision was made through skin and subcutaneous tissues from cranial to the larynx to the manubrium. The sternohyoideus and sternothyroideus muscles, ipsilateral to the oronasal fistula, were isolated (Figure 1A) and transected at their origin on the manubrium and first costal cartilage. The muscles were reflected cranially towards the neck in one group maintaining their insertions on the hyoid apparatus and thyroid cartilage (Figure 1B). A subcutaneous tunnel was made using Carmalt forceps starting at the cranial edge of the skin incision towards the oral cavity (Figure 1C), coursing laterally to the vertical ramus of the mandible. The Carmalt forceps were gently opened to enlarge the tunnel to fit the muscle. A cheilotomy was made at the commissure to the caudal end of the vestibule of the oral cavity. An incision was made over the Carmalt forceps to form a connection from the subcutaneous tunnel into the dorso-caudal oral cavity (Figure 1D and Figure 2). The muscle group was rotated on the cranial vascular pedicle at the level of the hyoid bone and thyroid cartilage. A stay suture was placed in the muscle group then was pulled through the subcutaneous-to-intraoral tunnel to repair the fistula (Figure 1E,F and Figure 2B). The recipient bed was prepared by debridement of unhealthy bone and soft tissues. The muscles were sutured to the palate in two

layers including one layer secured into predrilled palatal bone tunnels using 3-0 polydioxanone or polyglyconate in a simple interrupted pattern and then apposed to the mucosa using the same suture type in a simple interrupted pattern. The muscle flap was also sutured to the soft palate and the buccal mucosa where indicated using 3-0 polydioxanone or polyglyconate in a simple interrupted pattern. The cheilotomy and neck incisions were closed routinely in two layers. All flaps were reinforced by additional soft tissues including the sternocephalicus (dog 1), a buccal mucosal flap (dog 2), a labial mucosal flap (dog 3) and an angularis oris mucosal flap (dog 4). Severity of complications was reported as mild, moderate or severe based on The Accordion Severity Classification of Postoperative Complications: Contracted Classification (Table S1).¹⁵ The time frame of complications were defined as short term if the complication was diagnosed within 14 days of surgery and long term if it was diagnosed after 14 days of surgery.¹⁵

Dog 1 presented for evaluation of a maxillary squamous cell carcinoma after neoadjuvant RT. Maxillectomy with ventral orbitectomy and buccal mucosal flap were performed 37 days after completion of RT. Dehiscence was diagnosed 6 days after surgery, and was addressed with collagen mesh. Nine days later, dehiscence was again diagnosed and sternothyroideus-sternohyoideus flap was pursued. (Figure 3).

Dog 2 presented for evaluation of a maxillary fibrosarcoma. Stereotactic RT (SRT) was performed. The dog presented for progressive halitosis and the external mass was noticeably larger 75 days after SRT. Due to a diagnosis of

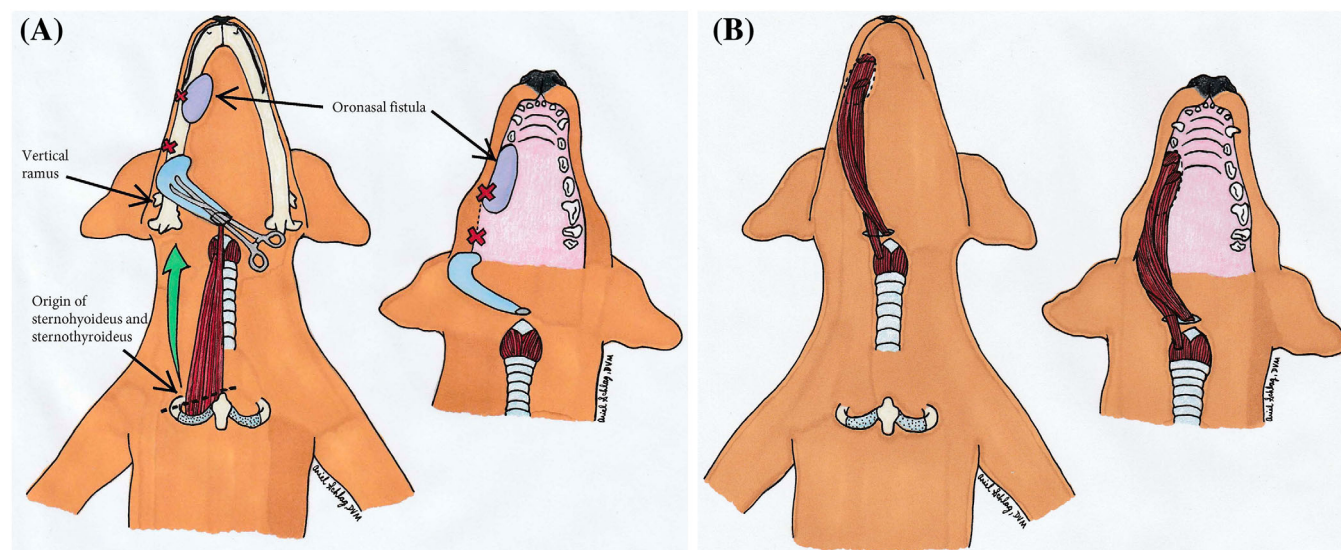


FIGURE 2 (A) Sternohyoideus-sternothyroideus muscle flap illustration – donor tissue harvesting. A subcutaneous tunnel (blue) was made using Carmalt forceps starting at the cranial edge of the skin incision towards the oral cavity, coursing rostrally, lateral to the vertical ramus of the mandible and entering the oral cavity dorsally. The cheilotomy (depicted between the red X marks) facilitated this step. The illustration on the right (B) depicts the same step with the mandible and muscle flap removed.

aspiration pneumonia, sternohyoideus-sternothyroideus flap was delayed until 153 days after the completion of SRT.

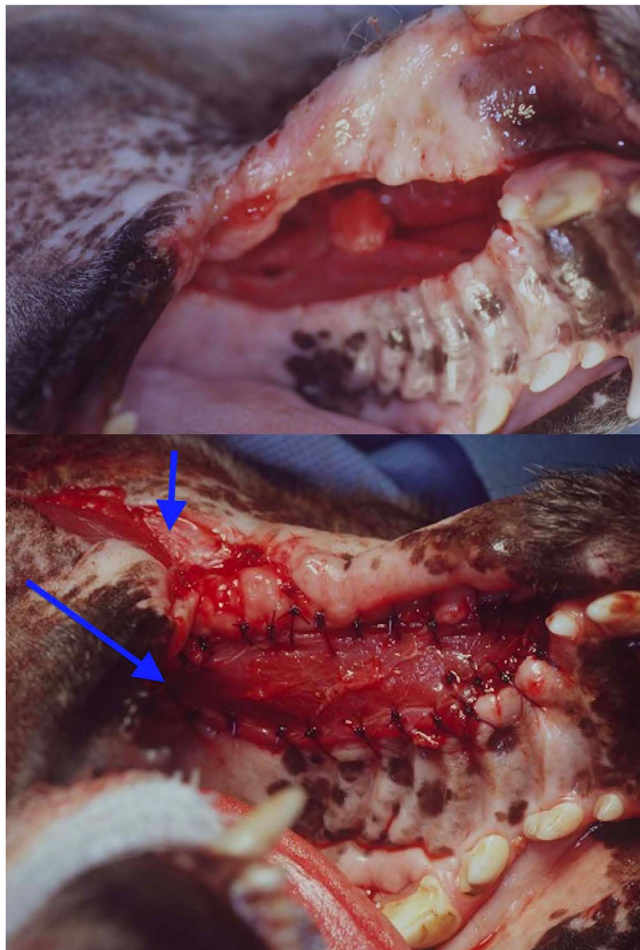


FIGURE 3 Pre- and intraoperative appearance of dog 1. Preoperatively (top), there was a large oronasal fistula after RT and two surgeries. The fistula was reconstructed with a sternohyoideus, sternothyroideus, sternocephalicus flap (bottom). The chilotomy (short arrow) and intraoral opening of the tunnel (long arrow) are highlighted.

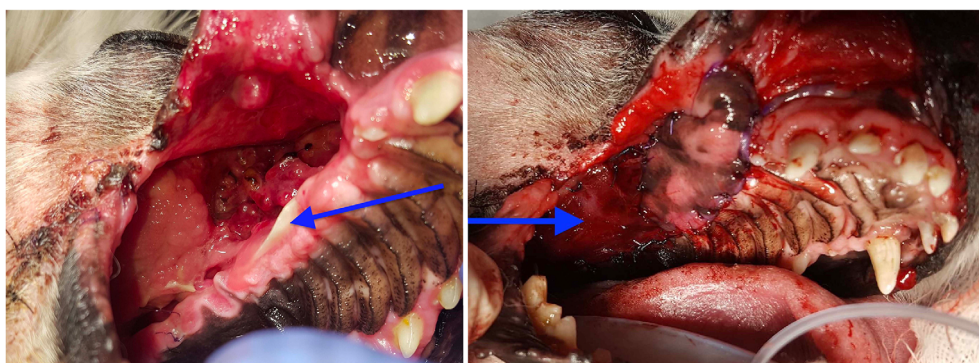

FIGURE 4 Pre- and intraoperative appearance of dog 3. Preoperatively (left), there was a large oronasal fistula caused by previous surgery. The labial mucosa is inflamed and the palatal bone is exposed (arrow). Intraoperatively (right), the flap covers the entire oronasal fistula. The exposed part of the muscle flap can be seen caudally (arrow). The rostral end of the muscle flap is covered by a labial mucosal flap.

Dog 3 presented for evaluation of a maxillary fibrosarcoma causing oral pain and dysphagia. A right caudal maxillectomy and partial orbitectomy were performed. Two days postoperatively, the dog began reverse sneezing. Oral examination revealed 4 cm of dehiscence along the hard palate mucosa at the level of 109 extending caudally. A sternohyoideus-sternothyroideus muscle flap was performed. (Figure 4).

Dog 4 presented with an osteosarcoma of the right caudal maxilla and zygomatic arch. Treatment included: 65.4 mCi of Samarium IV 122 days prior to presentation, RT 61 days prior to presentation, two doses of carboplatin (300 mg/m² IV) up to 19 days prior to presentation and surgery to address bone exposure 21 days prior to presentation which involved extraction of teeth 105–110 and a local buccal mucosal flap. Dehiscence of this flap was diagnosed at presentation. CT showed the expansile mass and multiple oronasal fistulas within the mass, centered at the level of the fourth maxillary premolar. Debridement of necrotic bone and sternohyoideus-sternothyroideus flap were performed. A vital pulpectomy of 409 was performed to protect the flap from self-trauma.

3 | RESULTS

Clinical data are presented in Table 1. Due to the retrospective nature of this case series, the three-dimensional defect size for each case was not reported because of missing information in each medical record. The CT reports and CT images were used to determine that the tumor size was at least 4 cm at the level of the maxilla in each case.

Dog 1 experienced mild epistaxis and swelling around the cervical incision immediately post-operatively however, the complications resolved without intervention. Partial dehiscence was noted 34 days postoperatively,

TABLE 1 Case information of four dogs treated with sternohyoideus-sternothyroideus flap

Case no.	1	2	3	4
Signalment	8 year, NM terrier mix	11 year, NM Golden Retriever	13 year, FS Eskimo	5 year, NM mix
Tumor and resulting defect location	Right maxilla, ventral orbit, affecting teeth 105–110	Right caudal maxilla extending to midline, extending into the right nasal cavity, affecting teeth 105–107	Right caudal maxilla, zygomatic arch, approaching midline, affecting teeth 108–110	Right caudal maxilla, zygomatic arch, approaching midline, affecting teeth 105–110.
Tumor diagnosis/ TNM stage for oral tumors	Squamous cell carcinoma T3bN0M0	Fibrosarcoma T3bN1bM0	Fibrosarcoma T3bN0M0	Chondroblastic osteosarcoma T3bN0M0
Cause of maxillary defect	Neoadjuvant fractionated RT followed by maxillectomy and ventral orbitectomy – surgical complication	Destruction by tumor and tumor response to RT	Right caudal maxillectomy – surgical complication	Destruction by tumor and tumor response to RT
RT dose prescription	3 Gy x 16 fractions	8 Gy x 5 fractions daily	N/A	Samarium-153-DOTMP 2 mCi/kg IV and 2–3 Gy x 18 fractions for 48 Gy total
Timing of fistula development post-RT	44 days	36 days	N/A	21 days
Timing of flap surgery post-RT	64 days	153 days	N/A	62 days
Flap reinforcing techniques used	Sternocephalicus included in the donor tissue	Buccal mucosal flap, extraction of 410–411 prophylactically to protect the flap from self-trauma	Labial mucosal flap rostrally	Angularis oris mucosal flap, hyperbaric oxygen therapy starting 9 days postoperatively
Clinical signs that improved post-flap	Sneezing, cough, melena	Nasal discharge, epiphora, halitosis, dysphagia	Anorexia, reverse sneezing, serosanguinous discharge from mouth, halitosis	Exposure of necrotic alveolar and maxillary bone in the oral cavity
Short-term complications (within 14 days of surgery)	Mild - epistaxis	Mild - moderate swelling on right maxillary lip and ventral to eye. Mild hemorrhagic to serosanguinous nasal discharge for 1 day. Severe – dehiscence of rostral 2/3 of the flap in 7 days	Severe - dehiscence of two small areas in 5 days.	Moderate –edema/ swelling along buccal incision in 8 days. Slight irritation of the graft where the mandibular molar tooth was contacting the graft in 1 day. Severe - partial dehiscence in 5 days
Long-term complications (after 14 days of surgery)	Severe - subtotal dehiscence in 34 days	None	None	None
Donor site morbidity	Mild, short term - edema and discharge	Moderate, short term – purulent discharge 7 days postoperatively	None	Moderate, short term - dehiscence at proximal donor site, mild swelling, superficial surgical site infection 8 days postoperatively
Subsequent revision surgery post-flap	Six additional fistula repairs	None	One fistula repair	One fistula repair using previous muscle flap

(Continues)

TABLE 1 (Continued)

Case no.	1	2	3	4
Survival time post-diagnosis	Lost to follow-up 2010 days post-diagnosis	392 days	1170 days	532 days
Survival time post-RT	Lost to follow up 1969 days post-RT	339 days	N/A	455 days
Survival time post-flap	Lost to follow up 1905 days post-flap	182 days	1061 days	393 days
Chemotherapy	No	No	No	Carboplatin 300 mg/m ² two doses preflap and three doses post-flap.
Reason for euthanasia	Metastasis from anaplastic sarcoma of the neck, presumed late RT complication	Pain from local disease progression	Acute dyspnea, lethargy, lung nodules and splenic mass, metastatic hemangiosarcoma suspected	Local disease progression, pain, dysphagia, progressive nonambulatory in rear legs

Abbreviations: FS, female spayed; N/A, not applicable; NM, neutered male; RT, radiation therapy; TNM, tumor node metastasis.

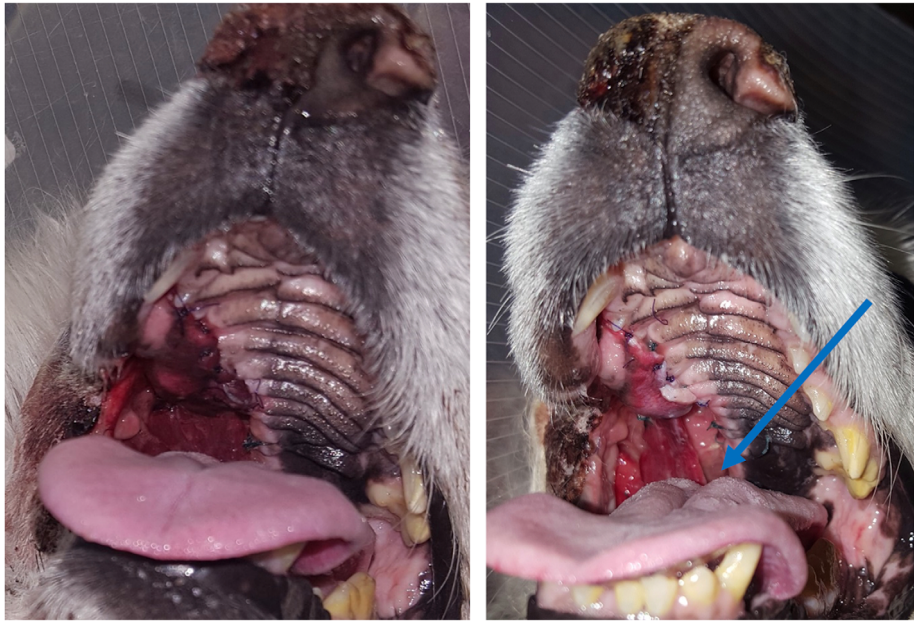


FIGURE 5 Postoperative appearance of dog 3. On day 1 (left), both portions of the reconstruction are intact. On day 2 (right), the caudomedial portion of the muscle flap was dehiscenced (arrow). The portion that is covered by the labial mucosal flap is intact.

causing an 1.5×0.5 cm oronasal fistula in the right maxilla affecting the region of teeth 105–110, which was suspected to be due to contraction at the rostral aspect of the flap. No clinical signs were noted at this time. The muscle graft was still viable and covered with granulation tissue. The dog had no clinical signs 41 days postoperatively. The small oronasal fistula remained static. Four additional surgeries were performed to repair the oronasal fistula including a mucoperiosteal transposition flap of the hard palate and soft palate transposition flap reinforced with polyester mesh, a buccal mucosal flap reinforced with teeth bonding, and two additional buccal mucosal flaps. The oronasal fistula remained; however, it was not associated with clinical signs. CT scans at 706 and

1435 days after the original surgery revealed no tumor regrowth. The dog was fed through an esophagostomy tube for 2 years following the maxillectomy and ate predominately by mouth for the last 2 years of life.

Dog 2 experienced immediate improvement of coughing and sneezing postoperatively. Subtotal dehiscence of the flap was diagnosed by physical examination during a recheck appointment 34 days postoperatively. The cause of the dehiscence was not clear but the flap had retracted from the rostral, mesial and medial edges of the recipient bed and sutures were pulled through tissues. The dog was euthanized 182 days postoperatively for pain at the tumor site.

Two days postoperatively, the oral examination on dog 3 showed that the rostral edge of the flap was healthy

but sutures pulled through the flap. No flap necrosis was noted. (Figure 5) A recheck examination 37 days postoperatively revealed dehiscence of the rostral ½ of the flap. One revision surgery was pursued, entailing a mucoperiosteal transposition flap of the hard palate for the rostral portion of the defect and buccal mucosal flap to repair the remaining caudal portion of the defect. Although the clinical signs resolved in this dog, an approximately 5–10 mm oronasal fistula remained. She was euthanized 1061 days after the flap surgery for reasons unrelated to the fibrosarcoma or the flap.

Eight days postoperatively, dog 4 presented without clinical signs of dehiscence. The rostral portion of the muscle flap was partially dehisced and pale yellow tissues with purulent material were visible on oral examination.

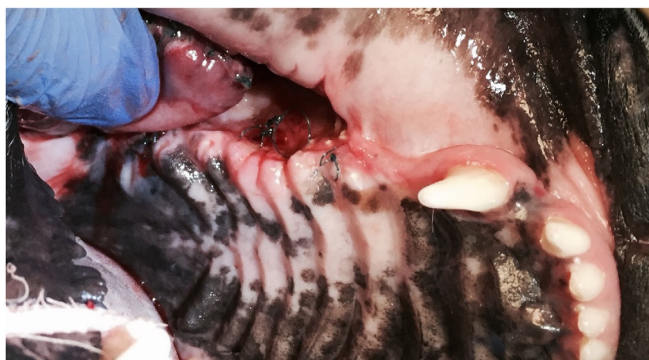


FIGURE 6 Appearance of dog 4 7 days postoperatively. Although there was dehiscence of the rostral half of the flap, there was no gross evidence of flap necrosis. The dehiscent portion of the donor tissue has rounded edges and has retracted from the rostral edge of the recipient bed. The healing portion of the muscle flap is adhered to the caudal margin of the palatine defect.

(Figure 6) The dog received 10 treatments of hyperbaric oxygen therapy and antibiotic therapy based on culture and sensitivity results. After 14 days, a revision surgery was performed which entailed re-suturing the dehiscent muscle flap plus a local buccal mucosal flap. Six days later, there were no clinical signs and the fistula was resolved. This dog was euthanized 393 days after the flap surgery with local disease progression.

4 | DISCUSSION

Here, we report a novel technique for repair of oronasal fistulas using a sternohyoideus-sternothyroideus muscle flap. Closure of recurrent oronasal fistulas in the caudal maxilla is challenging. Exposure is limited, the local tissue is contaminated from the oral and nasal cavities and the tissues are subjected to constant motion. Loss of elasticity and blood supply can be present due to chronic inflammation and dogs with chronic oronasal fistulas may have systemic comorbidities that affect healing.¹ We speculate that sternohyoideus and sternothyroideus muscles are acceptable for oronasal fistula repair because they are robust enough to withstand the normal forces seen in the mouth and are of sufficient length, reaching to the level of the first premolar without tension in these four dogs. In dog 1, the sternocephalicus was included in the donor tissue because of surgeon preference to have more tissue volume and the novel nature of the procedure. The angularis oris flap was not used in cases 1 and 2 because the flap underwent RT prior to surgery, as part of the tumor treatment. The angularis oris flap was not used in dog 3 because she was an Eskimo and her lip anatomy did not allow for a large enough flap to cover

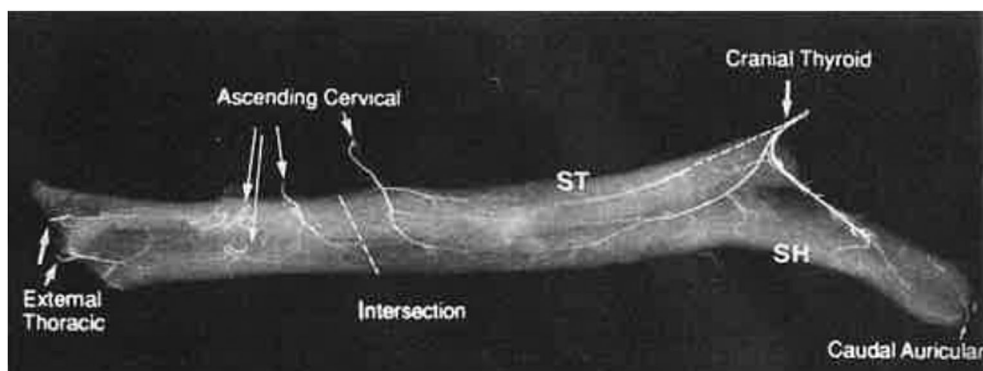


FIGURE 7 Angiogram from a canine cadaver showing the blood supply to the sternohyoideus and sternothyroideus. These muscles are expected to survive solely on the presence of the major pedicle, the cranial thyroid artery (circle) and ascending cervical artery. The caudal half of the muscles are supplied from the minor pedicle via the ascending cervical and/or deltoid branches of the superficial cervical artery. Most commonly, one branch of the ascending cervical artery penetrates dorsocaudal to the tendinous intersection of the muscles. A second branch enters each muscle cranial to the tendon and travels cranially in the muscle bellies. Additionally, a small vessel enters the muscles at the origin, most commonly arising from the external thoracic artery. Image reproduced with permission from Purinton et al.¹⁶

her defect. The angularis oris flap was used as a reinforcing technique in dog 4, but it was determined to not be large enough to cover the entire defect.

The sternohyoideus and sternothyroideus muscles have a type II vascular pattern, with one or more dominant vascular pedicle and minor vascular pedicles. (Figure 7) The muscle group is expected to survive on the presence of the dominant pedicle, comprised of the cranial thyroid and superficial cervical arteries.¹⁶ These muscles have been used to reconstruct the larynx in humans following subtotal laryngectomy¹⁷ and laryngo-tracheostomy¹⁸ and to reconstruct total glossectomies in humans with tongue cancer.¹⁹ In dogs, a similar muscle flap has been used experimentally to reinforce a tracheal end-to-end anastomosis²⁰ and to patch esophagotomy sites.²¹

The sternohyoideus-sternothyroideus flap has advantages and disadvantages. It is an axial pattern flap so flap survival is less dependent on recipient tissue's ability to supply nutrients. Special equipment was not required for flap creation, unlike with microvascular transfer techniques. Another subjective advantage is that donor tissue has adequate, but not excessive thickness to withstand motion in the mouth and is large enough to cover large defects without tension. Since this flap can be sutured to buccal mucosa, it can be used in an oronasal fistula that is not amenable to an implant. A disadvantage of this flap is that harvest requires more dissection of the donor site compared to local flaps, which may increase donor site morbidity.

All dogs experienced partial dehiscence of the flap. The high dehiscence rate may reflect a lack of understanding of this novel flap, a recipient bed with low healing potential, or a combination of factors. The flaps performed after RT were executed in an unfavorable clinical setting with a known high complication rate.⁷ In spite of partial dehiscence, the flap was considered to have substantially contributed to the rectification of the fistula. Staging the surgery might improve the blood supply and decrease the risk of dehiscence of the flap. The flap provided improved clinical signs for all dogs. To further explore the utility of this flap, this surgery could be performed in dogs with oronasal fistulas with a more favorable healing environment, such as congenital oronasal fistulas.

Based on our experience with these cases, we recommend considering the sternohyoideus-sternothyroideus muscle flap in challenging caudal oronasal fistula cases to attempt to improve quality of life. Further study to optimize flap survival is warranted.

AUTHOR CONTRIBUTIONS

Brittany J. Ciepluch: Acquisition of data, drafting work, final approval of work. Bernard Séguin: Conception of work, revising work, final approval of work. Deanna

Worley: Contribution of work, revising work, final approval of work.

ACKNOWLEDGEMENTS

Griffin MA, DVM, DACVS-SA and Kent M, DVM, MAS, DVM, DACVIM, DACVR for retrieving medical records and data from UC Davis. Schlag A, DVM for medical illustrations.

CONFLICT OF INTEREST

This manuscript was not supported by a grant or other financial support. There are no financial or other conflicts of interests of any author on this manuscript.

REFERENCES

1. Frazier SA, Johns SM, Ortega J, Zwingenberger AL. Outcome in dogs with surgically resected oral fibrosarcoma (1997–2008). *Vet Comp Oncol*. 2012;10:33–43.
2. Salisbury SK, Richardson DC, Lantz GC. Partial maxillectomy and premaxillectomy in the treatment of oral neoplasia in the dog and cat. *Vet Surg*. 1986;15:16–26.
3. Wendell NA. Nasal passages, sinus and palate. In: Slatter DH, ed. *Textbook of Small Animal Surgery*. Saunders. 2003:824–837.
4. Selmic LE, Lafferty MH, Kamstock DA, Garner A. Outcome and prognostic factors for osteosarcoma of the maxilla, mandible, or calvarium in dogs: 183 cases (1986–2012). *J Am Vet Med Assoc*. 2014;245:930–938.
5. Wustefeld-Janssens B, Smith L, Wilson-Robles H. Neoadjuvant chemotherapy and radiation therapy in veterinary cancer treatment: a review. *J Small Anim Pract*. 2021;62:237–243.
6. Farcas N, Arzi B, Verstraete FJ. Oral and maxillofacial osteosarcoma in dogs: a review. *Vet Comp Oncol*. 2014;12:169–180.
7. Seguin B, McDonald DE, Kent MS, Walsh PJ. Tolerance of cutaneous or mucosal flaps placed into a radiation therapy field in dogs. *Vet Surg*. 2005;34:214–222.
8. Denham JW, Hauer-Jensen M. The radiotherapeutic injury—a complex ‘wound’. *Radiother Oncol*. 2002;63:129–145.
9. Miller JM, Lanz OI, Degner DA. Rectus abdominis free muscle flap for reconstruction in nine dogs. *Vet Surg*. 2007;36:259–265.
10. Chambers AR, Skinner OT, Reeves LA, Rau MB. Staged mandibular lip flap for closure of a large palatal defect after maxillectomy in a dog. *Vet Surg*. 2021;50:668–676.
11. Soukup JW, Snyder CJ, Gengler WR. Free auricular cartilage autograft for repair of an oronasal fistula in a dog. *J Vet Dent*. 2009;26:86–95.
12. Cavanaugh RP, Farese JP, Bacon NJ, Lurie DM. Oronasal fistula repair utilizing a temporalis muscle flap in a dog with severe trismus. *J Am Anim Hosp Assoc*. 2011;47:447–454.
13. Tibesar RJ, Moore EJ, Bite U. Distraction osteogenesis for cleft palate closure in a canine model. *Arch Facial Plast Surg*. 2005;7:398–404.
14. Kuipers von Lande RG, Worth AJ, Peckitt NS, Cave NJ. Rapid prototype modeling and customized titanium plate fabrication for correction of a persistent hard palate defect in a dog. *J Am Vet Med Assoc*. 2012;240:1316–1322.
15. Follette CM, Giuffrida MA, Balsa IM, Culp W. A systematic review of criteria used to report complications in soft tissue

- and oncologic surgical clinical research studies in dogs and cats. *Vet Surg*. 2020;49:61-69.
16. Purinton PT, Chambers JN, Moore JL. Identification and categorization of the vascular patterns to muscles of the thoracic limb, thorax, and neck of dogs. *Am J Vet Res*. 1992;53:1435-1445.
 17. Dong P, Li X, Wang G, Chen X. Repair with sternohyoid muscle fascia after subtotal laryngectomy. *J Laryngol Otol Suppl*. 2009;31:18-23.
 18. Eshonhodjaev OD, Khudaybergenov SN, Kayumhodjaev AA, Mustafaev AT. Plastic surgery of persistent and extensive defects of the anterior wall of the trachea and neck soft tissues after laryngo-tracheostomy. *Eur Sci Rev*. 2016;52:3-4.
 19. Remmert S, Majocco A, Sommer K, Ahrens KH. A new method of tongue reconstruction with neurovascular infrahyoid muscle-fascia flaps. *Laryngorhinootologie*. 1994;73:198-201.
 20. Pinto MA. Bioprótese Traqueal. *Ciência Rural*. 1992;22:293-298.
 21. ME. Esophagotomy. In: Monnet E, Smeak DD, eds. *Gastrointestinal Surgical Techniques in Small Animals*. John Wiley & Sons, Inc; 2020:98-99.

SUPPORTING INFORMATION

Additional supporting information can be found online in the Supporting Information section at the end of this article.

How to cite this article: Ciepluch BJ, Séguin B, Worley D. Sternohyoideus-sternothyroideus muscle flap to reconstruct oronasal fistulas due to maxillary cancer in four dogs. *Veterinary Surgery*. 2022;1-9. doi:[10.1111/vsu.13923](https://doi.org/10.1111/vsu.13923)