BSAVA
JSAP JOURNAL OF SMALL ANIMAL PRACTICE

CASE REPORT

Transmural migration of a subcutaneous ureteral bypass into the intestine in three cats

J. Boullenger [1,*], F. Lafuma [*], C. Baudin Trehiou[*], L. Blond[*], S. Gibert[*] and N. Kulendra[†,‡]

[*]Centre Hospitalier Vétérinaire Languedocia, 34080 Montpellier, France
[†]North Downs Specialist Referrals, Bletchingley RH1 4QP, UK
[‡]Department of Clinical Science and Services, The Royal Veterinary College, Hatfield, Hertfordshire AL97TA, UK

[1]Corresponding author email: dr.vet.boullenger@gmail.com

Subcutaneous ureteral bypass™ is a device placed in cats with ureteral obstruction. The most common complications include system occlusion, urinary tract infection and sterile cystitis. In this case series, we describe three cats with subcutaneous ureteral bypass devices placed where transmural migration of subcutaneous ureteral bypass catheters into the small intestine resulted in gastrointestinal signs, urinary infection and subcutaneous ureteral bypass occlusion. The system was changed in one case and removed in the other two. In all cases, an intestinal resection and anastomosis was performed. All cats had a good medium-term outcome, and urinary infection persisted in the case for which the subcutaneous ureteral bypass system was changed. Transmural migration of the device should be considered in cats with subcutaneous ureteral bypass presenting with persistent urinary tract infection, gastrointestinal signs or device obstruction, even if imaging studies such as ultrasound or contrast studies do not demonstrate any abnormalities.

Journal of Small Animal Practice (2022) **63**, 792–796
DOI: 10.1111/jsap.13502

Accepted: 28 March 2022; Published online: 14 April 2022

INTRODUCTION

Feline ureteral obstruction is an increasingly diagnosed life-threatening condition. The causes of obstruction include urolithiasis, congenital or acquired ureteral strictures, cellular debris, surgical trauma and neoplasia (Berent *et al.* 2014, Steinhaus *et al.* 2015, Borchert *et al.* 2018, Sapora *et al.* 2019). Considering the poor outcome associated with medical management, early surgical treatment is advocated (Lulich *et al.* 2016, Milligan & Berent 2019). Nevertheless, traditional surgical procedures (ureterotomy, ureteral reimplantation and ureteronephrectomy) are associated with high complication and mortality rates (30 to 38% and 18 to 20% respectively) (Kyles *et al.* 2005, Roberts *et al.* 2011, Berent *et al.* 2014) and this led to the development of interventional procedures such as subcutaneous ureteral bypass™ (SUB™, Norfolk Vet Products) and ureteral stenting. SUB™ placement in cats is preferred to ureteral stenting, with less-reported complications and a better outcome (Berent *et al.* 2014, Kulendra *et al.* 2014, Deroy *et al.* 2017, Berent *et al.* 2018). Implanting a SUB™ is not inconsequential, however, the most frequently associated complications are system occlusion, urinary tract infection (UTI) and sterile cystitis (Deroy *et al.* 2017, Livet *et al.* 2017, Berent *et al.* 2018, Fages *et al.* 2018). Some of them can necessitate the removal or exchange of the system. This series describes three cases of a SUB™ complication, which occurred in three referral centres: a transmural migration of the device catheters into the small intestine.

CASES DESCRIPTION

Case 1

An 8-year-old female domestic shorthair (DSH) was presented to the referring veterinary surgeon with a 2-day history of inappetence, vomiting and weakness. The cat had a bilateral SUB™ device placed 29 months ago after bilateral obstructive ureterolithiasis was diagnosed. Regular follow-up examinations including urinalysis and urine culture, biochemistry, ultrasound examination of the SUB™ and ultrasound-guided flush of the SUB™ with

saline were performed every 3 to 6 months. Several episodes of self-resolving sterile cystitis occurred during the postoperative period. Haematology and biochemistry showed mild leukocytosis and neutrophilia and mild azotaemia (urea=16.6 mmol/L, reference interval (RI): 4.6 to 13.1 mmol/L; creatinine=177 µmol/L, RI: 62 to 177 µmol/L). Urine culture and sensitivity testing from the bladder and the subcutaneous port revealed infection with *Escherichia coli* sensitive only to fluoroquinolones. Abdominal ultrasound showed the proximal part of the right nephrostomy tube and the Dacron cuff were inside the descending duodenum, which was identified as a transmural migration of the device into the intestine (Fig 1). The renal pelvis was not dilated and no sign of intestinal obstruction was seen. At midline laparotomy, the descending duodenum was adherent to the right nephrostomy site. The proximal nephrostomy tube was encapsulated inside the intestine along with the Dacron cuff, entering on the antimesenteric border and emerging 3 cm aborally (Figs 2A,B and 3). A stone was palpable in the ureter. An intestinal resection and anastomosis was performed, and the entire right-sided SUB™ was replaced with a new nephrostomy tube placed through the previous tube path after having flushed the renal pelvis through the original tube. Bilateral adhesions between the ovaries and the nephrostomy sites were also observed, and a bilateral ovariectomy was performed according to the owner's wishes. The following day, the renal parameters returned to normal values (urea=5.2 mmol/L, RI: 5.5 to 12.6 mmol/L; creatinine=126.4 µmol/L, RI: 71 to 212 µmol/L); however, a repeat ultrasound revealed a dilated right renal pelvis (11 mm) and an obstructed nephrostomy tube during an ultrasound-guided flush with saline. A revision surgery involved repositioning of the misplaced pigtail in the renal pelvis. Daily ultrasonographic check-ups with flushes of the subcutaneous valves with 2 ml of 2% tetra-EDTA (T-FloLoc™; Norfolk Vet Products) were performed during hospitalisation. At discharge 5 days postoperatively, the renal parameters returned to normal values (urea=5.3 mmol/L, RI: 5.5 to 12.6 mmol/L; creatinine=119 µmol/L, RI: 71 to 212 µmol/L), and targeted therapy with 2 mg/kg marbofloxacin (Marbocyl; Vetoquinol) orally once a day for a total duration of 2 months was initiated based on initial and subsequent sensitivity profiles.

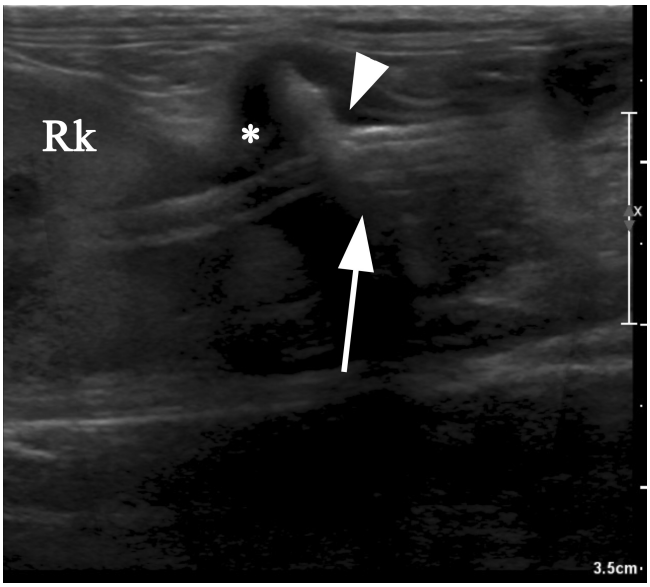

FIG. 1. Ultrasonographic image of the nephrostomy tube of the subcutaneous ureteral bypass that migrated into the duodenal wall. The Dacron cuff (arrow) is visible inside the intestinal lumen (arrowhead). The loss of the intestinal layered structure (asterisk) between the cuff and the right kidney (Rk) is the presumed site of transmural migration. The proximal part of the nephrostomy tube is still in place inside the renal pelvis. The surrounding fat is hyperechoic indicating a concurrent focal peritonitis

Follow-ups were done at 1 and 2 months after surgery and every 2 months thereafter. Each time, a thorough ultrasound evaluation of the whole SUB™, a flush with 2 ml of 2% tetra-EDTA (T-FloLoc™; Norfolk Vet Products), biochemistry, and urinalysis and bacterial culture and sensitivity testing, was performed. There was no further obstruction, and the renal parameters moderately increased (urea=7.2 mmol/L, RI: 5.5 to 12.6 mmol/L; creatinine=171.5 µmol/L, RI: 71 to 212 µmol/L at 9 months). At each recheck and until the last follow-up 9 months after surgery, a persistent bacteriuria with *E. coli* with the same antibiotics susceptibility profile was diagnosed. The cat was asymptomatic despite the presence of erythrocytes and neutrophils with intracytoplasmic bacteria for some; therefore, no further antimicrobial treatment was given.

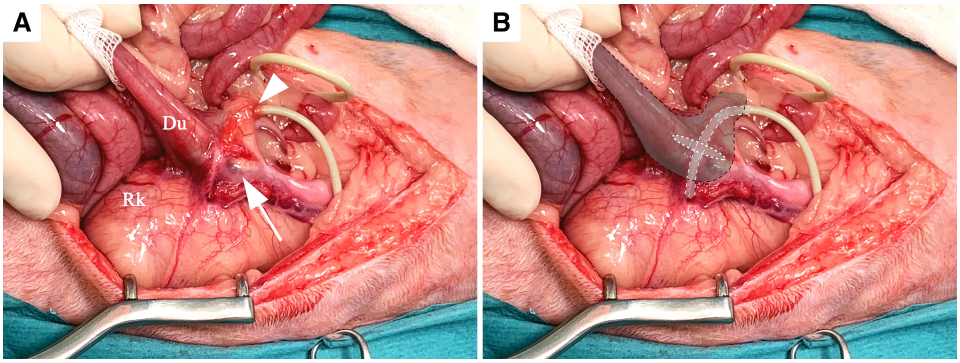

FIG. 2. (A) The descending duodenum (Du) is deformed by the migrated nephrostomy tube (arrowhead). Note that the right ovary and uterine horn (arrow) are adherent to the right kidney (Rk). (B) The nephrostomy tube (white dashlines and light grey) penetrates the antimesenteric border of the duodenum (black dashlines and dark grey) and emerges 3 cm aborally

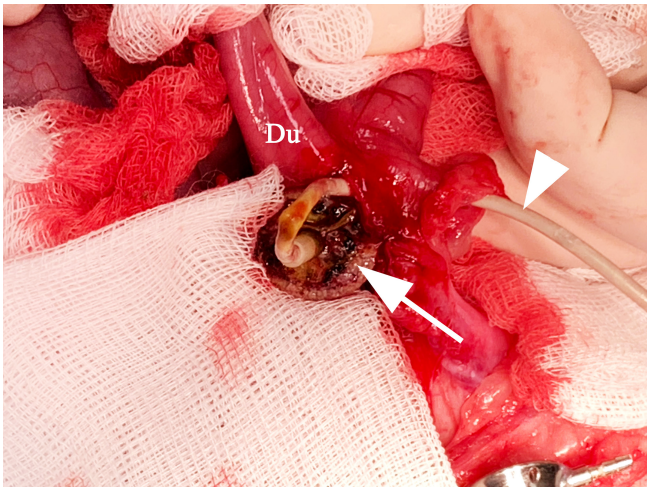

FIG. 3. The duodenum (Du) is opened and reveals the partially digested Dacron cuff (arrow) and the proximal part of the nephrostomy tube. The distal part of the nephrostomy tube (arrowhead) exits from the duodenum aborally

Case 2

A 9-year-old female neutered DSH was presented with fever, lethargy, inappetence and vomiting for 4 days. The cat had chronic kidney disease and a right-sided SUB™ placed 15 months ago after obstructive ureterolithiasis was diagnosed. The postoperative period was uneventful and no UTI was detected. Check-ups were performed every 3 to 6 months and included an ultrasound examination, biochemistry, urinalysis, urine culture and flush of the SUB™. Haematology and biochemistry showed neutrophilia with band cells, monocytosis and moderate azotaemia (creatinine=337 µmol/L, RI: 71 to 212 µmol/L; urea=13.5 mmol/L, RI: 5.7 to 12.9 mmol/L). Abdominal ultrasound revealed a 3-mm dilation of the right renal pelvis and a small amount of abdominal free fluid; aspiration and cytology confirmed a modified transudate (albumin=14 g/L, leukocytes=1250/µL). No abnormality of the right SUB™ was seen, but the flushing was not possible because of blockage. Urine culture from a sample obtained from the port revealed a bacterial infection with *E. coli* sensitive to amoxicillin-clavulanate amongst others. These two elements prompted a surgery.

At laparotomy, an antegrade pyelogram showed that the right ureter was patent, which permitted to remove the obstructed and infected SUB™. Moreover, it was observed that the Dacron cuff of the nephrostomy tube had eroded a hole into the descending duodenum, without any signs of leakage and subsequent septic peritonitis. An intestinal resection and anastomosis was performed.

Postoperatively, the cat became anaemic (haematocrit=11%, RI: 25 to 45%) and a whole blood transfusion was given. At discharge on the 9th day, the creatinine had decreased to 188 µmol/L (RI: 71 to 212 µmol/L) and the haematocrit had increased to 14%. Targeted antibiotic therapy was administered with 20 mg/kg amoxicillin-clavulanate (Synulox; Zoetis) orally twice a day for 14 days. The cat recovered well and no UTI was detected thereafter. The cat was euthanised 1 year later because of a weight loss, lethargy and a severe azotaemia (creatinine=653 µmol/L, RI: 71 to 212 µmol/L; urea >46.4 mmol/L, RI: 5.7 to 12.9 mmol/L); no further investigation was performed.

Case 3

A 7-year-old male neutered Ragdoll was presented 1 week after a 6-week course of enrofloxacin for treatment of a chronic UTI with *E. coli* and *Enterococcus faecalis*. The cat was lethargic for 2 weeks and presented signs of urinary discomfort, haematuria and periuria for 2 days. The cat had a bilateral SUB™ device placed 23 months ago after bilateral ureteral obstruction was diagnosed. Postoperative check-ups were performed at 3 and 5 months and then every year and included SUB™ flush using fluoroscopy, biochemistry, urinalysis and urine culture. Kinking of the left nephrostomy catheter with a patent ipsilateral ureter was detected at 16.5 months. Biochemistry and venous blood gas analysis showed normal creatinine (128 µmol/L, RI: 50 to 140 µmol/L), acidaemia (pH=7.14, RI: 7.3 to 7.4) and a mild hypokalaemia (3.1 mmol/L, RI: 3.6 to 4.6 mmol/L). Urine was sampled from the left port and the same bacteria were cultured. No urine could be collected from the right port and it could not be flushed. As the previous imaging studies (1 month previously) showed that both ureters were patent and a chronic UTI was present, an elective removal of both SUBs™ was decided. The ureters patency was confirmed intraoperatively with an antegrade pyelogram performed using the nephrostomy catheters. The laparotomy revealed extensive adhesions to both kidneys and the bladder, and a loop of jejunum was firmly adherent to both cystostomy tubes adjacent to the bladder. Dissection of the jejunum away from the cystostomy tubes revealed that the cystostomy tubes were penetrating the jejunum at their bladder insertion sites, and there was a fistulous communication between the bladder and the jejunum. Resection and anastomosis of the affected jejunal loop was performed, followed by partial cystectomy around the cystostomy tubes. The remainder of both SUB™ were also removed. The cat was discharged with 20 mg/kg amoxicillin-clavulanate (Kesium; Ceva Animal Health) orally twice a day for 5 weeks and 3 mg/kg pradofloxacin (Veraflox; Elanco) once a day for 5 weeks following urine and cystostomy tubes culture of *E. faecalis* sensitive only to amoxicillin-clavulanate and *E. coli* and *E. faecalis* sensitive only to pradofloxacin respectively. Six weeks after surgery, there was a resolution of the lower urinary tract signs, and the urine culture was negative. Sixty-one months after surgery, the renal parameters increased (creatinine=465 µmol/L, RI: 20 to 177 µmol/L; urea=39 mmol/L, RI: 2.5 to 9.9 mmol/L), and ultrasonography showed left ureteroliths with ipsilateral dilated renal pelvis and ureter and contralateral renal atrophy. The owner declined further investigation and surgery for financial and welfare reasons.

DISCUSSION

This is the second report of intestinal transmural migration of the SUB™ tubes in cats. Two cases have been previously reported by Johnston *et al.* (2021), in which nephrostomy tubes migrated into the duodenum. This complication was an incidental finding

secondary to the investigation and surgical treatment of infected and obstructed SUB™.

Early surgical decompression is advocated when ureteral obstruction occurs in cats (Lulich *et al*. 2016, Milligan & Berent 2019). The SUB™ technique first described by Berent *et al*. (2011) has less morbidity (especially fewer signs of feline lower urinary tract disease and device occlusion) and a better median survival time than ureteral stenting (Berent *et al*. 2014, Kulendra *et al*. 2014, Deroy *et al*. 2017, Berent *et al*. 2018). One study of 134 cats identified occlusion of the SUB™ because of mineralisation (24%) or blood clots (8%) as the most clinically relevant complication (Berent *et al*. 2018). Other complications reported in the literature include single episode UTI (24 to 31%), chronic bacteriuria (8 to 15%), clinical signs of sterile cystitis (6 to 39%), haematuria (11 to 15%), kinking of the device (5 to 25%), leakage (3 to 10%), urethral obstruction (1 to 8%), worsening azotaemia (1%), misplacement of the nephrostomy tube (5%), and death (6 to 15% during the first week after surgery) (Deroy *et al*. 2017, Livet *et al*. 2017, Berent *et al*. 2018, Fages *et al*. 2018, Dirrig *et al*. 2020, Kulendra *et al*. 2021).

In human medicine, transmural migration of an abdominal foreign body is uncommon and most of the reported cases involve retained surgical sponges. Other foreign bodies transmural migrations are reported in the human medical literature such as gastrostomy tube discs (Cahill *et al*. 2004), laparoscopic adjustable gastric band tubes (Hartmann *et al*. 2006) and hiatal hernia repair mesh (Picchio *et al*. 2017). The most frequent site of migration is the digestive tract, but the involvement of the bladder, the lung, and the trachea is also reported (Zantvoord *et al*. 2008). Based on our literature search [PubMed search on July 21, 2021, using keywords (dog), (cat), (foreign body migration), (transmural migration), and (subcutaneous bypass)], two cases of transmural migration of an abdominal foreign body have been reported in dogs (Day *et al*. 2012, Anson *et al*. 2018), and a feline case report was identified (Johnston *et al*. 2021). In both canine cases, a retained surgical sponge migrated into the jejunum and the caecum in 12 and 4 months, respectively, after ovariohysterectomy was performed. In the feline cases, nephrostomy tubes migrated into the duodenum 1.2 and 3 years after SUB™ placement.

Intestinal transmural migration of the nephrostomy or cystostomy tubes should be part of the differential diagnosis of cats with SUB™ presenting whether UTI, gastrointestinal signs or device obstruction. In the article of Johnston *et al*. (2021), the cats had gastrointestinal signs such as vomiting, diarrhoea and hyporexia and hyperthermia, which is similar to cases 1 and 2 of our paper. Case 3 only had signs of UTI. Overall, these clinical signs could have been the premises of a developing septic process or the consequence of the inflammatory response secondary to the tube migration. Surprisingly, no septic peritonitis was seen in our cases as leakage of intestinal content around the tubes could have occurred. Extensive adhesions around the migration sites, especially the greater omentum, and the presumed progressive migration may have prevented leakage into the peritoneal cavity. It is worth noting that no intestinal obstruction was present despite the tubes being into the intestinal lumen.

Imaging diagnostic of a migrating SUB™ device is challenging. In case 1, ultrasound examination resulted in the identification of the nephrostomy tube migration into the intestine, which is similar to both cases described by Johnston *et al*. (2021). On the contrary, ultrasound did not allow the identification of such complications in case 2, similar to the second case of Johnston *et al*. (2021) a few days before diagnosis. Hence, the diagnostic value of ultrasound was limited, more probably because of the adhesions around the migration site and the disturbed anatomy it generated. Other imaging modalities (fluoroscopy and contrast studies) did not identify this complication either; cross-sectional imaging modalities such as CT scan could allow the migration to be identified.

Several hypotheses can be formulated concerning the pathophysiology of the described migrations. The triggering mechanism of the transmural migration may have been a primary foreign body reaction from the SUB™, similarly to what was described in an experimental study about transmural migration of surgical sponges into the intestinal lumen of rats (Wattanasirichaigoon 1996). The author proposed four stages of transmural migration: foreign body reaction, secondary infection, mass formation and remodelling. Another possibility is that the migration was initiated by an infection leading to adhesions and then a secondary foreign body reaction. This mechanism is proposed in human literature for transmural migration of intra-abdominal tubes or meshes. It implies an inflammatory response triggered by ischaemia or a local infection leading to adhesions with surrounding viscera (Zengin *et al*. 2006, Picchio *et al*. 2017). For cases 1 and 2, no UTI was diagnosed at the time of the SUB™ placement and during the follow-ups; subsequently, the cats presented acutely and during the revision surgeries the cuffs were severely contaminated with intestinal content. It is likely that the acute presentation and UTI were secondary to the nephrostomy tubes' migration into the small intestine, leading to their erosion and subsequent bacterial translocation. Thus, we suppose the migration was elicited by the foreign body reaction initiated by the nephrostomy tube. Concerning the third case, a UTI was present for weeks and not responding to the treatment. This may have weakened the cystostomy sites, leading to local inflammation, jejunum adhesion and fistula formation. Moreover, other factors may have contributed to the initial adhesions between the bypass tubes and the intestine. As suggested by Johnston *et al*. (2021), the cyanoacrylate glue used to secure the cuff could have encouraged the development of adhesions. Additionally, the cuff material (Dacron) may have been involved as it is reported that it may lead to intra-abdominal adhesions in humans and animals. No perfect material is however available, and which one is best suited for which surgery is still debatable (Mori *et al*. 1998, Kiudelis *et al*. 2007, Brown & Finch 2010).

That being said, this long-term complication and its potential triggers highlight the necessity of a refined surgical technique for SUB™ implantation. Surgical principles such as Halsted's should not be overlooked as they minimise organs trauma and inflammation. Moreover, it could be worth implementing additional precautions during the surgery to prevent the adhesions, such as protecting the intestine when applying the glue, waiting enough time for the glue to dry, interposing omentum between

the cuffs and the viscera or preventing intestine serosa drying during surgery.

This report describes three cases of transmural migration of a SUB™ into the intestine in cats, which were all managed surgically by changing or removal of the device. As it was associated with UTI, acute onset of gastrointestinal signs and tube obstruction, any of these elements should raise suspicion of this recently described complication. The diagnosis of this condition was difficult in the cases of this present report, but advanced imaging modalities may help. The overall medium-term outcome was good but there was persistent bacteriuria in one cat. Studies with more cases could help better assess which diagnostic tool is the most useful and determine the long-term outcome of this complication.

Conflict of interest

None of the authors of this article has a financial or personal relationship with other people or organisations that could inappropriately influence or bias the content of the paper.

References

Anson, A., Carrillo, J. D., Bayon, A., *et al*. (2018) Imaging diagnosis—computed tomography findings in a dog with spontaneous transmural migration of a textiloma into the cecum. *Veterinary Radiology & Ultrasound* **59**, E28-E31

Berent, A. C., Weisse, C., Bade, H., *et al*. (2011) The use of a subcutaneous ureteral bypass devices for ureteral obstructions in cats – Oral Research Communications of the 21st ECVIM-CA Congress. *Journal of Veterinary Internal Medicine* **25**, 1470-1509

Berent, A. C., Weisse, C. W., Bagley, D. H., *et al*. (2018) Use of a subcutaneous ureteral bypass device for treatment of benign ureteral obstruction in cats: 174 ureters in 134 cats (2009-2015). *Journal of the American Veterinary Medical Association* **253**, 1309-1327

Berent, A. C., Weisse, C. W., Todd, K., *et al*. (2014) Technical and clinical outcomes of ureteral stenting in cats with benign ureteral obstruction: 69 cases (2006-2010). *Journal of the American Veterinary Medical Association* **244**, 559-576

Borchert, C., Berent, A. & Weisse, C. (2018) Subcutaneous ureteral bypass for treatment of bilateral ureteral obstruction in a cat with retroperitoneal paraganglioma. *Journal of the American Veterinary Medical Association* **253**, 1169-1176

Brown, C. & Finch, J. (2010) Which mesh for hernia repair? *Annals of the Royal College of Surgeons of England* **92**, 272-278

Cahill, A. M., Baskin, K. M., Kaye, R. D., *et al*. (2004) Transmural migration of gastrostomy tube retention discs. *Pediatric Radiology* **34**, 143-147

Day, J. L., Pechman, R. D. & Bahr, R. J. (2012) Migration of a retained surgical swab into the jejunum in a dog. *Journal of Small Animal Practice* **53**, 705-708

Deroy, C., Rossetti, D., Ragetly, G., *et al*. (2017) Comparison between double-pigtail ureteral stents and ureteral bypass devices for treatment of ureterolithiasis in cats. *Journal of the American Veterinary Medical Association* **251**, 429-437

Dirrig, H., Lamb, C. R., Kulendra, N., *et al*. (2020) Diagnostic imaging observations in cats treated with the subcutaneous ureteral bypass system. *Journal of Small Animal Practice* **61**, 24-31

Fages, J., Dunn, M., Specchi, S., *et al*. (2018) Ultrasound evaluation of the renal pelvis in cats with ureteral obstruction treated with a subcutaneous ureteral bypass: a retrospective study of 27 cases (2010–2015). *Journal of Feline Medicine and Surgery* **20**, 875-883

Hartmann, J., Scharfenberg, M., Paul, M., *et al*. (2006) Intracolonic penetration of the laparoscopic adjustable gastric banding tube. *Obesity Surgery* **16**, 203-205

Johnston, S. K., Bennett, T. & Miller, A. J. (2021) Intestinal perforation involving the Dacron cuff of nephrostomy tubes following subcutaneous ureteral bypass system implantation for ureteral obstructions in two cats. *JFMS Open Reports* **7**, 20551169211013296

Kiudelis, M., Jonciauskiene, J., Deduchovas, O., *et al*. (2007) Effects of different kinds of meshes on postoperative adhesion formation in the New Zealand white rabbit. *Hernia* **11**, 19-23

Kulendra, N. J., Borgeat, K., Syme, H., *et al*. (2021) Survival and complications in cats treated with subcutaneous ureteral bypass. *Journal of Small Animal Practice* **62**, 4-11

Kulendra, N. J., Syme, H., Benigni, L., *et al*. (2014) Feline double pigtail ureteric stents for management of ureteric obstruction: short- and long-term follow-up of 26 cats. *Journal of Feline Medicine and Surgery* **16**, 985-991

Kyles, A. E., Hardie, E. M., Wooden, B. G., *et al*. (2005) Management and outcome of cats with ureteral calculi: 153 cases (1984-2002). *Journal of the American Veterinary Medical Association* **226**, 937-944

Livet, V., Pillard, P., Goy-Thollot, I., *et al*. (2017) Placement of subcutaneous ureteral bypasses without fluoroscopic guidance in cats with ureteral obstruction: 19 cases (2014-2016). *Journal of Feline Medicine and Surgery* **19**, 1030-1039

Lulich, J. P., Berent, A. C., Adams, L. G., *et al*. (2016) ACVIM small animal consensus recommendations on the treatment and prevention of uroliths in dogs and cats. *Journal of Veterinary Internal Medicine* **30**, 1564-1574

Milligan, M. & Berent, A. C. (2019) Medical and interventional management of upper urinary tract uroliths. *Veterinary Clinics of North America: Small Animal Practice* **49**, 157-174

Mori, N., Takano, K., Miyake, T., *et al*. (1998) A comparison of prosthetic materials used to repair abdominal wall defects. *Pediatric Surgery International* **13**, 487-490

Picchio, M., Muggianu, A., Mancini, F., *et al*. (2017) Complete mesh migration into the small bowel after incisional hernia repair: a case report and literature review. *Acta Chirurgica Belgica* **117**, 118-121

Roberts, S. F., Aronson, L. R. & Brown, D. C. (2011) Postoperative mortality in cats after ureterolithotomy. *Veterinary Surgery* **40**, 438-443

Sapora, J. A., Hardie, R. J. & Evans, N. (2019) Use of a subcutaneous ureteral bypass device for treatment of bilateral proximal ureteral injury in a 9-month-old cat. *JFMS Open Reports* **5**, 2055116919831856

Steinhaus, J., Berent, A. C., Weisse, C., *et al*. (2015) Clinical presentation and outcome of cats with circumcaval ureters associated with a ureteral obstruction. *Journal of Veterinary Internal Medicine* **29**, 63-70

Wattanasirichaigoon, S. (1996) Transmural migration of a retained surgical sponge into the intestinal lumen: an experimental study. *Journal of the Medical Association of Thailand* **79**, 415-422

Zantvoord, Y., van der Weiden, R. M. F. & van Hooff, M. H. A. (2008) Transmural migration of retained surgical sponges: a systematic review. *Obstetrical & Gynecological Survey* **63**, 465-471

Zengin, K., Sen, B., Ozben, V., *et al*. (2006) Detachment of the connecting tube from the port and migration into jejunal wall. *Obesity Surgery* **16**, 206-207