

# Surgical techniques used in the management of intra-arachnoid diverticula in dogs across four referral centres and their immediate outcome

B. JONES <sup>\*</sup>, S. BEHR<sup>†</sup>, T. SHAW<sup>†</sup>, R. CAPPELLO<sup>‡</sup>, N. JEFFERY<sup>§</sup>, F. X. LIEBEL<sup>\*</sup> AND T. HARCOURT-BROWN<sup>\*,1</sup>

<sup>\*</sup>Neurology/Neurosurgery Service, Langford Vets Small Animal Hospital, Bristol BS40 5DU, UK

<sup>†</sup>Neurology/Neurosurgery Service, Willows Veterinary Centre and Referral Services, Solihull, UK

<sup>‡</sup>Neurology/Neurosurgery Service, North Downs Specialist Referrals, Bletchingley RH1 4QP, UK

<sup>§</sup>Department of Small Animal Medicine & Surgery, College of Veterinary Medicine, Texas A&M University, College Station, TX, 77843, USA

<sup>1</sup>Corresponding author email: tom.harcourt-brown@bristol.ac.uk

**OBJECTIVES:** To report the surgical techniques being used to treat single focal spinal intra-arachnoid diverticula in dogs, their complications and immediate postoperative outcomes.

**MATERIALS AND METHODS:** Retrospective multi-centre case series across four referral centres.

**RESULTS:** Fifty-seven dogs were included in the study. The most common type of surgery was durectomy (28 dogs) followed by marsupialisation (11 dogs), durotomy alone (seven dogs), shunt placement (six dogs) and stabilisation (five dogs).

A higher proportion of intra-arachnoid shunt dogs became unable to walk in the immediate postoperative period (24 hours postsurgery) (4/6, 66%) compared to all dogs five of 57, 9% (2/7 durotomy alone, 3/28 durectomy alone). Of the nine dogs with immediate postoperative deterioration, seven had improved, walking without assistance, by 3 to 5 weeks postoperatively.

**CLINICAL SIGNIFICANCE:** This study does not identify an influence of surgical technique on short-term outcome. Dogs with a thoracolumbar intra-arachnoid diverticulum that undergo a shunt placement are likely to deteriorate neurologically in the immediate 24-hour postoperative period but appear to improve by 3 to 5 weeks after surgery. Further work is required to evaluate whether one surgical technique is superior for preventing or reducing long-term relapse.

*Journal of Small Animal Practice* (2022) **63**, 520–525  
DOI: 10.1111/jsap.13486

Accepted: 18 January 2022; Published online: 9 February 2022

## INTRODUCTION

Spinal intra-arachnoid diverticula (IAD) [also known as spinal arachnoid diverticula, subarachnoid diverticula, subarachnoid cysts (Nabors *et al.* 1988, Gnirs *et al.* 2003)] are abnormal dilation of the subarachnoid space, possibly secondary to meningeal adhesions present across the subarachnoid space. They are hypothesised to cause subsequent spinal cord compression and damage leading to progressive neurological dysfunction, such as paresis, spinal ataxia,

urinary and faecal incontinence (Skeen *et al.* 2003, Chen *et al.* 2005, Flegel *et al.* 2013, Bismuth *et al.* 2014, Lowrie *et al.* 2014, Mauler *et al.* 2014). Various aetiologies have been suggested for the formation of the adhesions such as congenital meningeal malformation (Rylander *et al.* 2002, Gnirs *et al.* 2003, Lowrie *et al.* 2014) or acquired meningeal trauma from inflammation, acute trauma or chronic repeated microtrauma at high mobility portions of the spine (Gnirs *et al.* 2003, Oxley & Pink 2011, Fisher *et al.* 2013, Aikawa *et al.* 2019, Driver *et al.* 2019, Lourinho *et al.* 2020).

The appearance of the diverticula on CT myelography and MRI are variable, but typically a “tear drop” dilation of the dorsal subarachnoid space is visible causing dorsal compression of the spinal cord (Rylander *et al.* 2002, Gnirs *et al.* 2003). Dilation of the subarachnoid space is not seen in all cases, some can have a stellate appearance on cross sectional imaging of the spinal cord or a narrowing of the subarachnoid space as a part of constrictive myelopathy (Meren *et al.* 2017, Lourinho *et al.* 2020, Rohdin *et al.* 2020). The latter are thought to have a different pathogenesis and hypothesised to have a worse long-term prognosis due to their high recurrence rate (Meren *et al.* 2017, Driver *et al.* 2019, Lourinho *et al.* 2020, Rohdin *et al.* 2020) and, therefore, could represent a different type of lesion and should be characterised separately from IAD.

Several surgical treatments for the most typical IAD have been described (Nabors *et al.* 1988, Skeen *et al.* 2003, Chen *et al.* 2005, Fisher *et al.* 2013, Flegel *et al.* 2013, Bismuth *et al.* 2014, Lowrie *et al.* 2014, Mauler *et al.* 2014, Meren *et al.* 2017) with the primary aim of removing adhesions and the secondary aim being the prevention of IAD recurrence (McKee & Renwick 1994, Frykman 1999, Meren *et al.* 2017). To our knowledge, there are no current studies surveying what surgical techniques are currently being used to manage this condition and evaluating whether they are any immediate detriment or benefit.

The primary aim of this study was to report the current surgical techniques being used to treat the single focal “tear drop” form of IAD affecting the thoracolumbar spine of dogs showing neurological dysfunction compatible with the location of the lesion.

The secondary aim was to report the immediate (24 hours) short-term (3 to 5 weeks) outcome between the techniques.

## MATERIALS AND METHODS

We performed a multi-centre, retrospective and descriptive study. Veterinary databases from four referral centres (Langford Vets Small Animal Hospital, Willows Veterinary Centre, North Downs Specialist Referrals and the College of Veterinary Medicine, Texas A&M University) were retrospectively reviewed from January 2010 to January 2019 to identify cases of dogs with IAD. Search terms were not standardised between centres; each investigator used search terms and software thought to be the most appropriate to identify the largest number of cases at their centre.

Case notes were reviewed and animals included if the case notes contained a historical description of their neurological disease before presentation, a description of the neurological examination at admission performed by the European Society of Veterinary Neurology (ECVN) diplomate or resident under their supervision, an MRI report written by an recognised specialist in veterinary diagnostic imaging or resident under their supervision describing a single focal “tear drop” dilation of the subarachnoid space causing a compressive myelopathy of the T3 to L3 spinal cord, a description of the surgical technique used, a description of the neurological examination performed within 24 hours of

surgery and a description of the neurological status 3 to 5 weeks after surgery obtained in-person or *via* telephone consultation.

Animals were excluded if the onset of their signs was described as acute within 7 days of presentation, if they had neurological deficits inconsistent with a focal T3 to L3 myelopathy, if they were unable to walk without assistance before surgery or if their MRI report described a stellate or multi-lobed appearance to the arachnoid dilation or additional significant spinal cord disease, *e.g.* compression associated with a disc protrusion or hemivertebra.

All MRI images were then retrospectively reviewed by an ECVN diplomate or resident under their supervision to ensure that the cases being included all conformed to the description of a single focal “tear drop” dilation of the subarachnoid space with secondary spinal cord compression.

For the analysis of surgical techniques used, surgeries were categorised as one of the following techniques:

- Durotomy alone. The area of the IAD was exposed with a routine haemilaminectomy (Kerwin *et al.* 2012). The overlying dura mater was incised so that the non-adhered cord was exposed cranial and caudal to the IAD. The dura was reflected with forceps or stay sutures. Adhesions were broken down with sharp and blunt dissection until the dura and were separated from the spinal cord throughout the exposed field. The dural edges were not sutured together.
- Durectomy alone. In addition to the durotomy, a strip of dura was removed bridging the IAD site so that there was a persistent dural defect. The dural edges were not sutured together.
- Durotomy combined with intra-arachnoid shunt placement. In addition to the durotomy, a rubber or silicone foley catheter was inserted into the arachnoid space cranial to caudal to the IAD as has been previously described (Meren *et al.* 2017). The dural edges were either sutured in apposition over the catheter or to the edges of the catheter using 5/0 nylon sutures.
- Durotomy and/or durectomy combined with marsupialisation. In addition to the durotomy or durectomy, the dural edges were sutured to adjacent paravertebral soft tissues such as the joint capsule so that the dural deficit was held open as has been previously described (McKee & Renwick 1994)
- Durotomy combined with stabilisation. Of the vertebral segments containing the IAD with a 3D-printed titanium buttress plate (O'Malley *et al.* 2017) or a unilateral polyaxial titanium locking plate.

Any intraoperative complications described for each technique were also recorded, but these were not analysed due to the lack of a standardised reporting method.

The contemporaneous examinations of dogs the day following surgery were used to produce assessments of immediate outcome (<24 hours). Notes made at revisit appointments or following telephone consultations within 3 to 5 weeks after surgery were used to produce assessments of short-term outcome. At both these time points, the neurological status was recorded as deteriorated if they were unable to walk without assistance; static if they remained able to walk with persistent ataxia or paresis and improved if they were recorded to be walking nor-

mally at that time or with less ataxia or paresis than before surgery. Urinary and faecal continence was also recorded at these time points.

## RESULTS

### Signalment and presurgical presentation

A total of 57 dogs were identified and fulfilled the inclusion criteria. The process of case selection is shown in Fig 1.

The most common breeds included pugs (31), French bulldogs (12), crossbreeds (seven), English bulldogs (three) and West Highland White terriers (two). The median age was 4.5 years (range from 5 months to 10 years). Thirty-three of 57 (58%) dogs were male (19 male entire and 14 male neutered) and 24 of 57 (42%) dogs were female (22 female neutered and one female entire). The median duration of clinical signs was 9.1 months (range 1 week to 18 months). Presurgical incontinence was present in 27 of 57 (47%) dogs: six (11%) were urinary incontinent only, 14 (25%) were faecally incontinent only and seven (12%) were both faecally and urinary incontinent.

### MRI findings

All dogs had the presence of a focal T2W intramedullary hyperintensity at the level of the diverticulum.

Additional concurrent MRI findings were identified and reported in 18 of 57 dogs (32%) but were deemed non-relevant for the clinical signs, despite their relationship could not be ruled out. These included disc protrusion (6/57), facet hypoplasia or aplasia (7/57) and vertebral malformation (5/57) such as kyphotic malformations or hemivertebrae located at the same site as the IAD. Four dogs had more than one additional finding on MRI.

Postcontrast (gadolinium) T1-W studies were performed in 16 of 57 cases with no cases demonstrating contrast enhancement.

Cerebrospinal fluid sampling was performed in 26 of 57 cases. Median total nucleated cell count was 2.98 cells/ $\mu$ l (range 0 to 17) and total protein 52.5 g/L (range 29 to 116). The increased cell counts were concluded to be secondary to haemodilution based on a red blood cell count.

### Surgical techniques

The most common type of surgery was a durectomy (28 dogs) followed by marsupialisation (11 dogs), durotomy alone (seven dogs), shunt placement (six dogs) and stabilisation (five dogs). Each referral centre had a preferred surgery with the majority of the durectomies (26/28 dogs) performed at Willows Veterinary Centre, durotomy (5/7 dogs) at Langford Vets Small Animal Hospital and marsupialisation (7/11 dogs) at North Downs Specialist Referrals. Only one surgical complication was recorded in the case notes. This was in a dog where stabilisation was performed and there was rupture of the azygos during vertebral body screw placement and subsequent non-fatal haemomediastinum.

There were additional MRI findings in four of five (80%) dogs that had stabilisation compared to 14 of 52 (27%) dogs that were not stabilised. Two dogs were stabilised with a 3D-printed plate and a polyaxial locking system plate in three of five dogs.

### Postoperative outcome

The immediate and short-term outcomes for dogs based on the surgical technique used are shown in Fig 2. Nine dogs deteriorated to become non-ambulatory within 24 hours postsurgery. Eight dogs (2/7 durotomy alone, 3/28 durectomy alone and 3/6 shunt placement) became non-ambulatory paraparetic and one dog (1/6) that underwent a shunt placement became paraplegic with intact pain sensation. At 3 to 5 weeks, 48 of 57 (84%) dogs had improved, seven of 57 (12%) dogs had not improved and remained ambulatory paraparetic whilst two of 57 (4%, both treated with durotomy alone) remained unable to walk without assistance following their

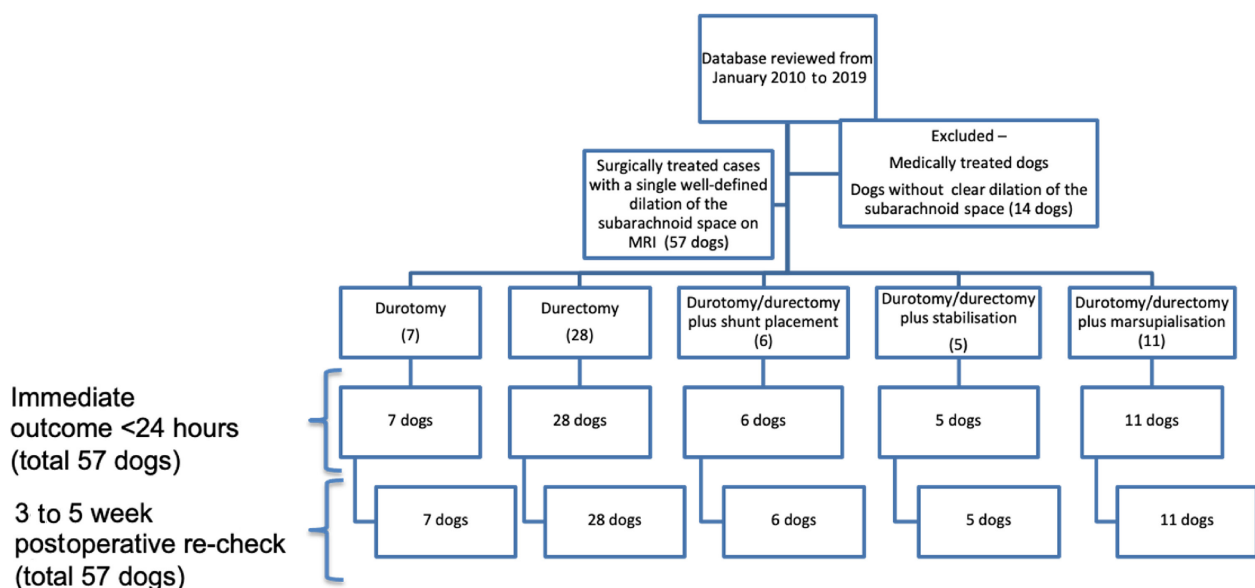
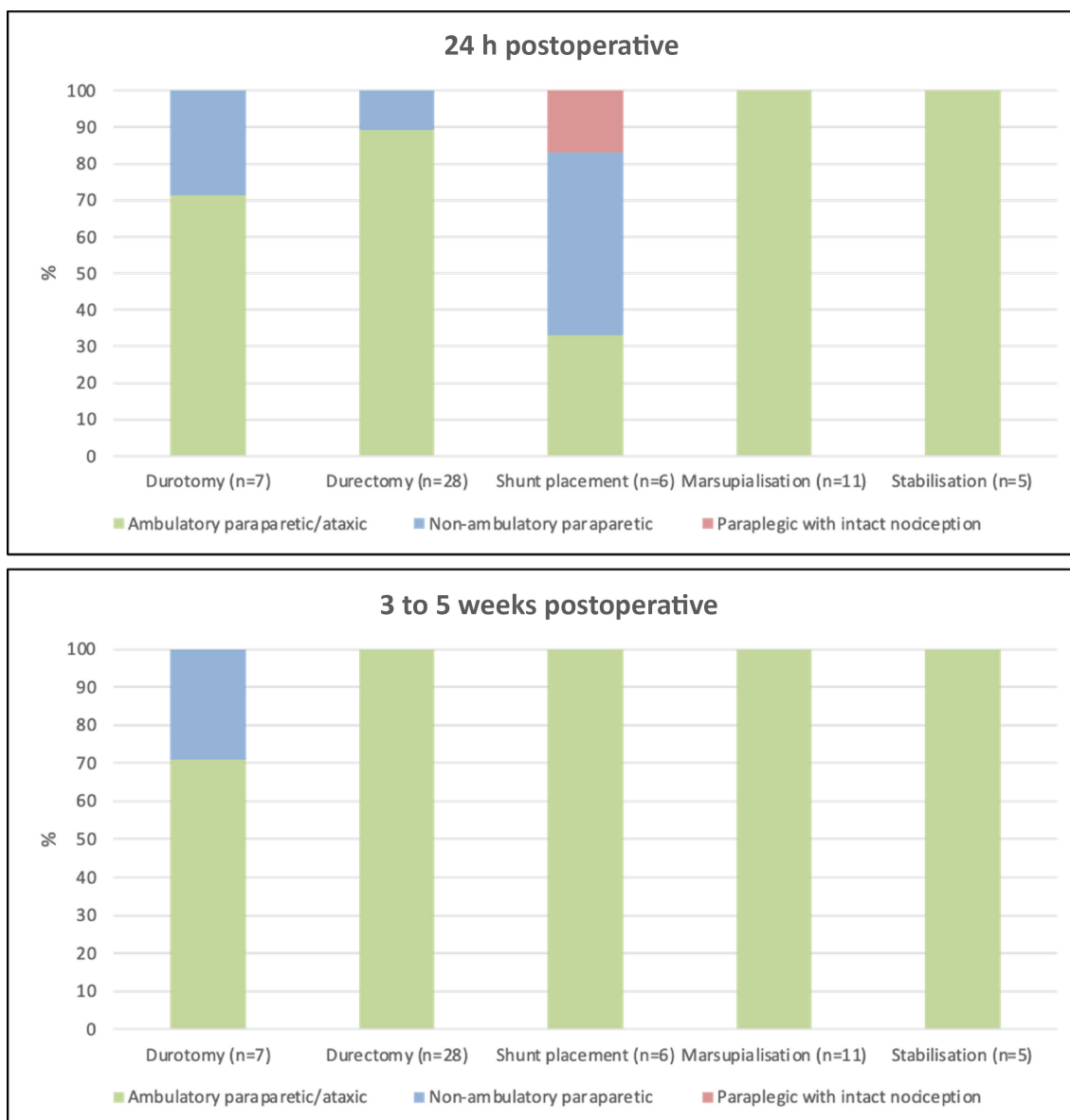


FIG 1. Flow chart displaying the process for case selection



**FIG 2.** Percentage of presurgical ambulatory paraparetic dogs with thoracolumbar intra-arachnoid diverticula based on their neurological status at 24 hours postsurgery (top) and at the 3- to 5-week (bottom) postoperative follow-up based on the surgical technique performed

postoperative deterioration. All other dogs that deteriorated postoperatively were able to walk unaided 3 to 5 weeks after surgery.

All 27 dogs reported to be incontinent presurgery had follow-up data at 3 to 5 weeks. Nineteen of 27 (70%) resolved. All six (100%) urinary incontinent dogs resolved (surgical techniques: one durotomy, four durectomies and one marsupialisation), 11 of 14 (83%) faecally incontinent dogs resolved (surgical techniques: four durectomies, three durotomies, three marsupialisations and one stabilisation) and two of seven (22%) urinary and faecally incontinent dogs resolved (both underwent shunt placement). Two dogs (one durotomy and one marsupialisation) were perceived by their owners to have deteriorated with regards to their preoperative status due to deterioration in continence, despite their gait improving. No dog developed urinary or faecal incontinence after surgery that did not have it before.

## DISCUSSION

Five different surgical techniques to treat IAD were included in this study and there may be additional techniques in use elsewhere. The existence of multiple techniques is suggestive that, currently, no one surgery can be concluded to be superior. The personal experience and preference of the individual surgeon appear to be influential as individual institutions tended to perform one predominant technique. Our data cannot establish which is the most common technique used outside this data set, but the variety of approaches used between and within institutions differs from a review of human surgery for a similar condition where durotomy and fenestration of the cyst was the preferred technique (Eroglu *et al.* 2019).



Major surgical complications appear rare with only one stabilisation-related complication being reported across all surgeries. Comparison of minor complications (such as controllable intraoperative haemorrhage) or complications that were more difficult to assess (such as iatrogenic cord contusion) was not possible with this retrospective data set because there was no standardised reporting method.

We found that a higher proportion of dogs with shunt placement deteriorated (4/6, 66%) immediately postoperatively compared to overall (5/57, 9%), but this deterioration was transient as all dogs improved and recovered ambulation by the time of the postoperative re-check at 3 to 5 weeks. It may be that this apparently higher rate of deterioration reflects iatrogenic cord damage from increased manipulation during this surgery, but the improvement by 3 to 5 weeks postoperatively in all these dogs suggests that this damage is largely reversible.

Overall, 84% of dogs improved in the 3- to 5-week postoperative period and there appeared to be little difference between surgical techniques. We did not analyse these data statistically because there were low case numbers in each surgical group and there was clear surgeon selection, implying that variability in individual cases or the management at specific centres would confound unambiguous detection of differences in outcome between techniques.

Diagnosis of the IAD was based on a board-certified radiologist and neurologist's interpretation with surgical confirmation of a fluid-filled cyst-like structure and intra-arachnoid adhesions. We only included dogs with an MRI describing a single well-defined expansion or "tear drop" dilation of the subarachnoid space and excluded dogs with an unclear dilation or circumferential adhesions because there is evidence that a multitude of intra-arachnoid adhesion phenotypes exists, some of which appear to be characterised by constriction or circumferential fibrosis (Meren *et al.* 2017, Driver *et al.* 2019, Lourinho *et al.* 2020, Rohdin *et al.* 2020). Whether this distinction is accurate and/or has any prognostic importance remains to be elucidated, but if varying proportions of congenital *versus* acquired disease existed in each surgical technique, this might influence outcome.

Another complicating factor may be additional anomalies such as vertebral malformations and Intervertebral disc disease (IVDD) that may contribute to repetitive microtrauma for the formation and subsequent reformation of the adhesions (Driver *et al.* 2019, Lourinho *et al.* 2020). Although additional findings in our data set were not deemed to be clinically relevant, their relationship could not be ruled out entirely. This may ultimately influence the type of surgical technique used for different appearances in future and warrants further work in this area.

Limitations of this study include its retrospective nature and multi-centre cohort which affects the standardisation of surgical techniques and aftercare.

Another limitation is that the comparison of these cases may not have been appropriate if the criteria used to diagnose the disease were different at differing institutions.

Stress myelography has been used in a recent study to aid the clinical decision for vertebral stabilisation (Aikawa *et al.* 2019). No dynamic views were performed in the current study, and this may have been beneficial to assess the contribution of the vertebral malformations and/or IVDD protrusion to a dynamic

component of the IAD in aiding the decision to stabilise the portion of the vertebral column or not.

An important factor regarding the treatment of IAD is the risk of recurrence and reformation of the diverticula postoperatively. Recurrence had previously been reported in 86% of pug dogs up to 12 months (or later) postoperatively (Alisaukaite *et al.* 2019). Evaluating the different surgical techniques for recurrence will therefore be clinically relevant, but this will require a minimum follow-up period of 12 to 24 months.

This study describes the surgical techniques currently being used across four referral centres for dogs with a single thoracolumbar IAD and their immediate postoperative outcome. Dogs with a thoracolumbar IAD that undergo a shunt placement are likely to deteriorate neurologically in the immediate 24-hour postoperative period, but appear to improve by 3 to 5 weeks after surgery. Further work is required to investigate whether there is a benefit of one surgical technique over another for preventing or reducing the relapse rate in the long-term period.

### Conflict of interest

None of the authors of this article has a financial or personal relationship with other people or organisations that could inappropriately influence or bias the content of the paper.

### References

- Aikawa, T., Shimatsu, T. & Miyazaki, Y. (2019) Hemilaminectomy, diverticular marsupialization, and vertebral stabilization for thoracolumbar spinal arachnoid diverticula in five dogs. *Journal of the American Animal Hospital Association* **55**, 2-116
- Alisaukaite, N., Cizinauskas, S., Jeserevics, J., *et al.* (2019) Short- and long-term outcome and magnetic resonance imaging findings after surgical treatment of thoracolumbar spinal arachnoid diverticula in 25 pugs. *Journal of Veterinary Internal Medicine* **33**, 1-8
- Bismuth, C., Ferrand, F.-X., Millet, M., *et al.* (2014) Original surgical treatment of thoracolumbar subarachnoid cysts in six chondrodystrophic dogs. *Acta Veterinaria Scandinavica* **56**, 32
- Chen, A. V., Bagley, R. S., West, C. L., *et al.* (2005) Fecal incontinence and spinal cord abnormalities in seven dogs. *Journal of the American Veterinary Medical Association* **227**, 1945-1951
- Driver, C. J., Rose, J., Tauro, A., *et al.* (2019) Magnetic resonance image findings in pug dogs with thoracolumbar myelopathy and concurrent caudal articular process dysplasia. *BMC Veterinary Research* **15**, 182
- Eroglu, U., Bozkurt, M., Kahilogullari, G., *et al.* (2019) Surgical management of spinal arachnoid cysts in adults. *World Neurosurgery* **122**, e1146-e1152
- Fisher, S. C., Shores, A. & Simpson, S. T. (2013) Constrictive myelopathy secondary to hypoplasia or aplasia of the thoracolumbar caudal articular processes in pugs: 11 cases (1993-2009). *Journal of the American Veterinary Medical Association* **242**, 223-229
- Flegel, T., Müller, M. K., Truar, K., *et al.* (2013) Thoracolumbar spinal arachnoid diverticula in 5 pug dogs. *Canadian Veterinary Journal* **54**, 969-973
- Frykman, O. F. (1999) Spinal arachnoid cyst in four dogs: diagnosis, surgical treatment and follow-up results. *Journal of Small Animal Practice* **40**, 544-549
- Gnirs, K., Ruel, Y., Blot, S., *et al.* (2003) Spinal subarachnoid cysts in 13 dogs. *Veterinary Radiology & Ultrasound* **44**, 402-408
- Kerwin, S. C., Levine, J. M. & Hicks, D. G. (2012) Thoracolumbar spine. In: *Veterinary Surgery: Small Animal*. 1st edn. Eds K. M. Tobias and S. A. Johnston. Saunders, St. Louis, MO, USA. pp 449-475
- Lourinho, F., Holdsworth, A., McConnell, J. F., *et al.* (2020) Clinical features and MRI characteristics of presumptive constrictive myelopathy in 27 pugs. *Veterinary Radiology & Ultrasound* **61**, 545-554
- Lowrie, M. L., Platt, S. R. & Garosi, L. S. (2014) Extramedullary spinal cysts in dogs. *Veterinary Surgery* **43**, 650-662
- Mauler, D. A., De Decker, S., De Risio, L., *et al.* (2014) Signalment, clinical presentation, and diagnostic findings in 122 dogs with spinal arachnoid diverticula. *Journal of Veterinary Internal Medicine* **28**, 175-181
- McKee, W. M. & Renwick, P. W. (1994) Marsupialisation of an arachnoid cyst in a dog. *Journal of Small Animal Practice* **35**, 108-111
- Meren, I. L., Chavera, J. A., Alcott, C. J., *et al.* (2017) Shunt tube placement for amelioration of cerebrospinal fluid flow obstruction caused by spinal cord subarachnoid fibrosis in dogs. *Veterinary Surgery* **46**, 289-296
- Nabors, M. W., Pait, T. G., Byrd, E. B., *et al.* (1988) Updated assessment and current classification of spinal meningeal cysts. *Journal of Neurosurgery* **68**, 366-377

- O'Malley, F., & Shaw, T. & Harcourt-Brown, T. (2017) A novel surgical system for stabilization of congenital thoracic spinal malformations in dogs using a custom made 3D-printed titanium plate and drill guide. European Society of Veterinary Neurology (ECVN) Conference in Helsinki, Finland.
- Oxley, W. & Pink, J. (2011) Amelioration of caudal thoracic syringomyelia following surgical management of an adjacent arachnoid cyst. *Journal of Small Animal Practice* **53**, 67-72
- Rohdin, C., Ljungvall, I., Häggström, J., et al. (2020) Thoracolumbar meningeal fibrosis in pugs. *Journal of Veterinary Internal Medicine* **34**, 797-807
- Rylander, H., Lipsitz, D., Berry, W. L., et al. (2002) Retrospective analysis of spinal arachnoid cysts in 14 dogs. *Journal of Veterinary Internal Medicine* **16**, 690-696
- Skeen, T. M., Olby, N. J., Muñana, K. R., et al. (2003) Spinal arachnoid cysts in 17 dogs. *Journal of the American Animal Hospital Association* **39**, 271-282