Check for updates

Received: 18 July 2024 | Revised: 16 July 2025 | Accepted: 20 July 2025

DOI: 10.1111/vsu.14322

CLINICAL RESEARCH

WILEY

Comparison of the effect on blood flow of two intradermal suture patterns in feline skin: A within animal randomized controlled trial

Sylvia Bayrakdarian BS, MPS | **Galina M. Hayes DACVS (Small Animal), DACVECC, PhD**

Cornell University, Ithaca, New York, USA

Correspondence
Galina M. Hayes, Cornell University, Ithaca, NY, USA.
Email: gmh59@cornell.edu

Funding information
College of Agriculture and Life Sciences, Cornell University

Abstract

Objective: To compare the effect of two continuous intradermal suture patterns (modified Allgower-Donati [mAD] vs. horizontal mattress [SP]) on acute changes in cutaneous perfusion following closure of the skin incision in cats undergoing ovariohysterectomy.

Study design: Within animal randomized controlled trial conducted at three animal shelters.

Animals: A total of 32 cats.

Methods: Adult cats receiving elective ovariohysterectomy underwent standardized skin incisions closed with two intradermal suture patterns (mAD or SP) randomly assigned to the cranial or caudal half. All procedures were performed by an ACVS board certified surgeon. Incisional margin cutaneous perfusion was measured using a laser Doppler perfusion imager at baseline and following closure. Baseline perfusion was subtracted from post-suturing perfusion at each region obtaining a delta effect for each pattern. Incisional complications in the 30 days following surgery were also recorded.

Results: Mean (±SD) surgical time was 19.3 ± 4.1 min. Cutaneous perfusion increased by a mean of 59.7 ± 124.1 blood perfusion units (BPU) from baseline with the mAD pattern, compared with a decrease of 20.2 ± 119.9 BPU from baseline for the standard suture pattern ($p < .01$). No cats re-presented for incisional complications.

Conclusion: The mAD pattern resulted in improved wound margin perfusion compared with the SP pattern.

Clinical significance: The mAD pattern offers an alternative to the current standard of care intradermal pattern, maintaining the advantages of a buried pattern while improving perfusion to the wound margin.

1 | INTRODUCTION

Closure of cutaneous wounds following surgical incision or penetrating injury is a common procedure in feline veterinary practice. Over 40% of cats presented for trauma management have cutaneous wounds.[1] Management of

Abbreviations: BPU, blood perfusion units; IACUC, institutional animal care and use; mAD, modified Allgower-Donati pattern; SD, standard deviation; SP, standard pattern (horizontal mattress).

This study was partially funded by a grant from Cornell University CALS professional programs.

 © 2025 American College of Veterinary Surgeons.

traumatic wounds in cats can be challenging, with certain wound presentations having a high risk of dehiscence and reconstructive failure.[2] Similarly, relatively routine reconstructions and surgical closures can be complication prone,[3–5] with the potential for unexpected late wound opening.[6]

Some of these challenges may be explained by differences in cutaneous anatomy and wound healing between cats and other species. Compared with dogs, the skin of cats has a lower vascular density and is not as well perfused,[7,8] while wounds are slower to granulate and regain tensile strength.[7] Wound closure techniques that optimize perfusion to the skin margin may therefore be more critical in this species.

A cutaneous closure method for feline wounds currently in common use is a running intradermal horizontal pattern using absorbable suture.[9] The popularity of this technique may be due to several reasons including reduced potential for patient interference, a cosmetic postoperative wound appearance and shortened or eliminated recheck appointments as the suture does not require removal. However, this pattern requires multiple suture bites to be taken parallel and close to the wound margin, which may not optimize perfusion.

The Allgower-Donati suture pattern has become established in the field of trauma management for human patients as a pattern that optimizes perfusion to the incision margin and minimizes strangulation of soft tissues.[10,11] The pattern has been recommended by the AO-ASIF group for the management of skin flaps with compromised microcirculation[12] and relies on dermal bites taken at 90° to the wound margin, parallel to incident feeder vessels. The effect of the pattern on skin perfusion in cats has not been evaluated.

The purpose of this study was to compare the effect of the Allgower-Donati suture pattern on skin perfusion in cats with the running intradermal horizontal pattern, using an objective measure of skin perfusion in a standardized setting. For the purpose of this study, a modified form of the continuous Allgower-Donati pattern[13] was used in which all suture was maintained in a buried position.

2 | MATERIALS AND METHODS

2.1 | Study design and inclusion criteria

This was a within animal randomized controlled trial[14] (IACUC protocol no.: 2023-0181) conducted at three animal shelters located in the upstate New York area between December 2023 and January 2024. The shelters hosted sterilization services provided by a single local non-profit corporation (Shelter Outreach Services). The sterilization services met or exceeded the guidelines set by the Association of Shelter Veterinarians for high quality high volume spay neuter programs.[15] Following provision of informed consent from their owners or the shelter, adult cats presented for elective ovariohysterectomy underwent skin closure with two intradermal suture patterns. All cats received a physical examination prior to any procedure. Cats that appeared unwell or dehydrated, had any skin irritation, mixed skin pigmentation, or a surgical scar at the intended surgical site were excluded. For the skin closure, the incision was divided in two halves, and one of two intradermal suture patterns was randomly assigned to either the cranial or caudal half of the incision using a random number generator (www.calculator.net/randomnumber). Randomization was performed within blocks of 10. All procedures were performed by an ACVS board certified surgeon (GH). All wounds were closed from caudal to cranial. The two suture patterns under test (Figure 1) were a running intradermal horizontal pattern where the dermal bites were taken parallel to the incision (SP group) and a running intradermal pattern where the dermal bites were taken at 90 degrees to the incision (mAD group).[11] The dermal bites were approximately 5 mm in length with for both groups. For the mAD group, bites were spaced approximately 5 mm apart. For both patterns the start and end knots were buried with four square throws, and 4/0 poliglecaprone (Monocryl, Ethicon, Raritan, New Jersey) on a 13 mm 3/8c reverse cutting needle was used.

2.2 | Data collection and outcomes

Cats were premedicated with dexmedetomidine 5 mcg/kg IM and butorphanol 0.2 mg/kg IM. General anesthesia was induced with ketamine 10 mg/kg IV and midazolam 0.2 mg/kg IV and maintained following intubation with isoflurane in 100% oxygen. Blood pressure was continuously monitored through the anesthetic period using a doppler flowmeter (Parks Medical Ultrasonic Doppler, Aloha, Oregon) and blood pressure cuff positioned on a forelimb, with titration of IV fluid support/ isoflurane administration to maintain a mean arterial blood pressure > 70 mmHg. The animal was positioned in dorsal recumbency, clipped, and an initial skin preparation using a chlorhexidine scrub solution was performed. A skin temperature probe was secured to the ventral abdominal skin. A 4 cm distance was marked in the appropriate location for a midline spay incision using a sterile marker pen, and the incision divided into two 2 cm halves. The marks were positioned away from the intended surgical incision. Prior to surgical incision, the baseline cutaneous blood flow was measured every second

1532950x, 2026, 2, Downloaded from https://onlinelibrary.wiley.com/doi/10.1111/vsu.14322 by Mathieu Jourdain - Oniris Chantrerie , Wiley Online Library on [24/02/2026]. See the Terms and Conditions (https://onlinelibrary.wiley.com/terms-and-conditions) on Wiley Online Library for rules of use; OA articles are governed by the applicable Creative Commons License

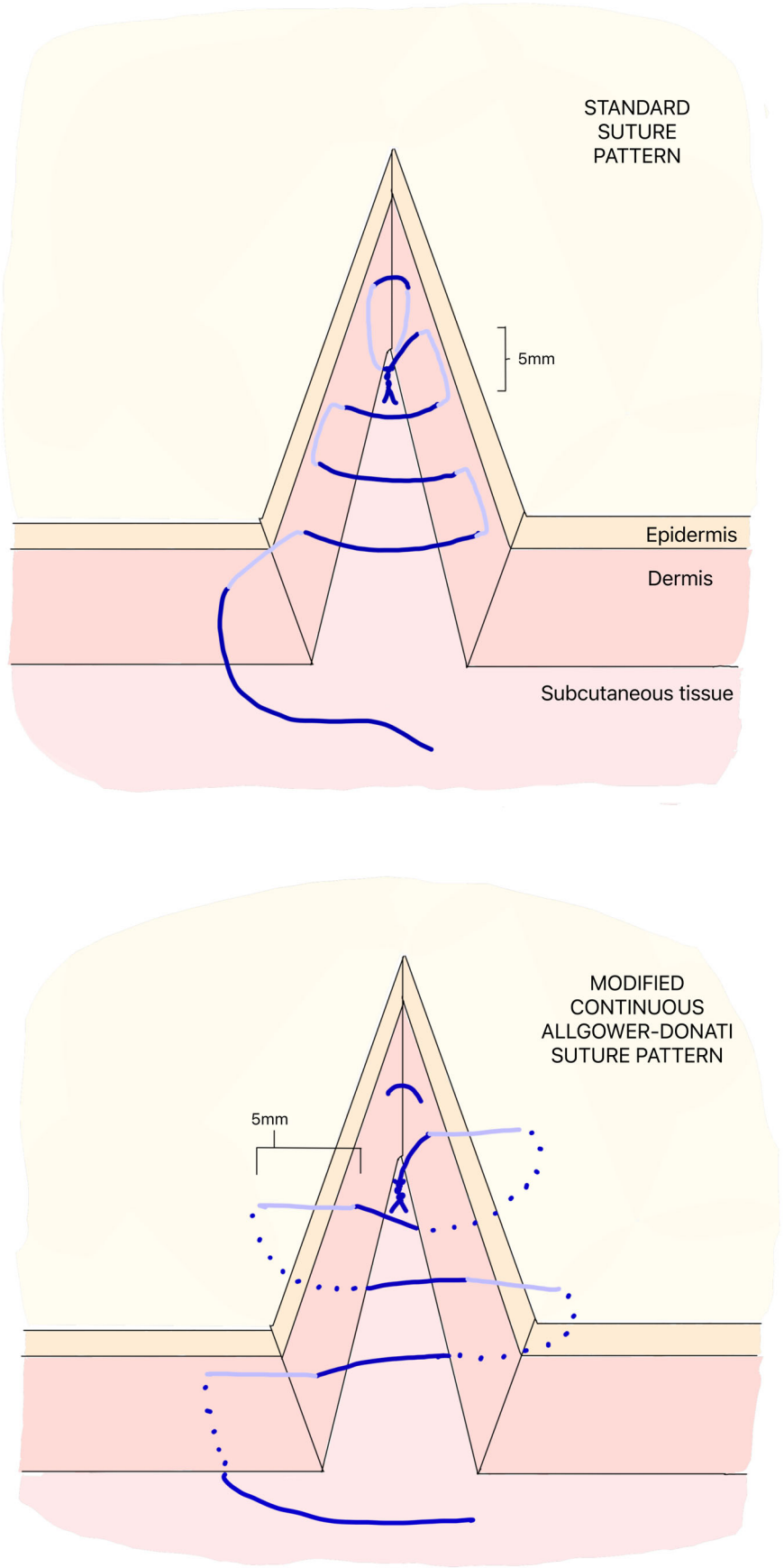

FIGURE 1 Diagram of intradermal suture patterns-modified continuous Allgower-Donati versus standard continuous horizontal patterns.

1532950x, 2026, 2, Downloaded from https://onlinelibrary.wiley.com/doi/10.1111/vsu.14322 by Mathieu Jourdain - Oniris Chantrerie , Wiley Online Library on [24/02/2026]. See the Terms and Conditions (https://onlinelibrary.wiley.com/terms-and-conditions) on Wiley Online Library for rules of use; OA articles are governed by the applicable Creative Commons License

for a 30 s period using laser doppler perfusion with a cutaneous probe (AD instruments, Colorado Springs, Colorado) and the average value recorded for each location (cranial and caudal) in blood perfusion units (BPU). The probe was positioned 1 mm lateral to the intended incision location, in the center of each half. A routine ovariohysterectomy was performed using standard technique. The linea alba was closed using 2/0 polydioxanone (PDS, Ethicon), and the subcutaneous fat was closed using 4/0 poliglecaprone (Monocryl, Ethicon) in a quilting pattern[16] when a subcutaneous fat layer was present. The skin was closed as described above. Following skin closure, cutaneous blood flow was measured again as described above at each of the incision halves with the probe positioned in the center of each half, 1 mm lateral to the incision. Skin temperature was recorded at the start and end of surgery using a skin temperature probe (AD instruments). Perioperative analgesia was administered in all cases, consisting of meloxicam (Boehringer, Ridgefield, Connecticut) 0.1 mg/kg given subcutaneously prior to induction.

The primary outcome was the change in cutaneous microcirculation blood perfusion units from baseline for each of the two suture patterns assessed. Data were also collected on known or estimated cat age, bodyweight, body condition score, skin temperatures and surgical time. Active in-person follow-up of individual cats participating in the study was not possible due to the shelter setting; however, the owners and shelters were encouraged to re-present the cats should any issues arise, and data was collected on any cats re-presenting with incisional complications in the 30 days following surgery.

2.3 | Statistical analysis

Power analysis identified a group size of 32 as sufficient to detect a 30% between group difference in blood flow change from baseline, based on prior reported data.[11] Continuous data was assessed for normality using a Shapiro–Wilk test. Means and SD are reported as population descriptors where the data was normal, and median (range) where the data was not normal. Baseline perfusion was subtracted from post-suturing perfusion to obtain a delta effect for each suture pattern. Normal data groups paired within cat were compared using a paired *t*-test.

3 | RESULTS

3.1 | Baseline population data

Cats were recruited until enrollment satisfied power calculations ($n = 35$). Data from the first three cats was discarded due to issues with inconsistent signal acquisition from the laser doppler flowmeter. Within the remaining 32 cats the cranial half of the incision was closed with the mAD pattern and the caudal half with the SP pattern on 16 occasions, and the caudal half of the incision was closed with the mAD and the cranial half of the incision with the SP pattern on a further 16 occasions (Figure 2). Three cats lacked sufficient subcutaneous fat to perform a subcutaneous closure. Median known or estimated age was 1 year (range: 0.3–10 years). Mean (±SD) bodyweight was 3.1 kg ± 0.6 kg. All cats were intact females. Mean interval from anesthesia induction to baseline blood flow measurements was 14.9 ± 4.9 min. Mean (± SD) surgical time was 19.3 ± 4.1 min. Skin temperature at the region of the incision rose a mean of 0.28°F (± 1.39°F) over the course of surgery, and did not parallel rectal temperature change, which decreased a mean of 1.92°F (±1.37°F) over the same time period.

3.2 | Cutaneous perfusion data

Cutaneous perfusion was slightly higher in the cranial half of the incision compared with the caudal half of the incision at baseline (109.0 ± 74.1 BPU vs. 84.3 ± 83.2 BPU, $p = .15$) although this difference did not reach statistical significance. The change in cutaneous perfusion with intradermal suturing was substantially different between the mAD pattern and the SP pattern. With the mAD pattern, cutaneous perfusion increased a mean of 59.7 ± 124.1 BPU from baseline, compared with a decrease of 20.2 ± 119.9 BPU for the SP pattern ($p < .01$) as shown in Figure 3. These changes reflected a mean

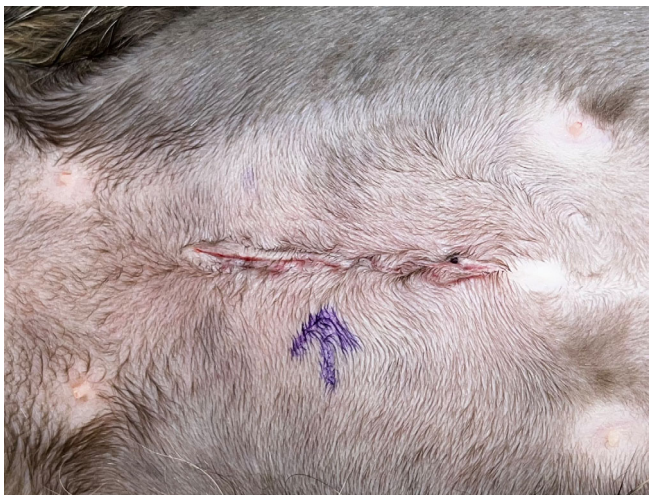

FIGURE 2 Cat ovariohysterectomy incision following closure with intradermal modified Allgower-Donati (to left of arrow) versus continuous horizontal mattress (to right of arrow).

1532950x, 2026, 2, Downloaded from https://onlinelibrary.wiley.com/doi/10.1111/vsu.14322 by Mathieu Jourdain - Oniris Chantrerie , Wiley Online Library on [24/02/2026]. See the Terms and Conditions (https://onlinelibrary.wiley.com/terms-and-conditions) on Wiley Online Library for rules of use; OA articles are governed by the applicable Creative Commons License

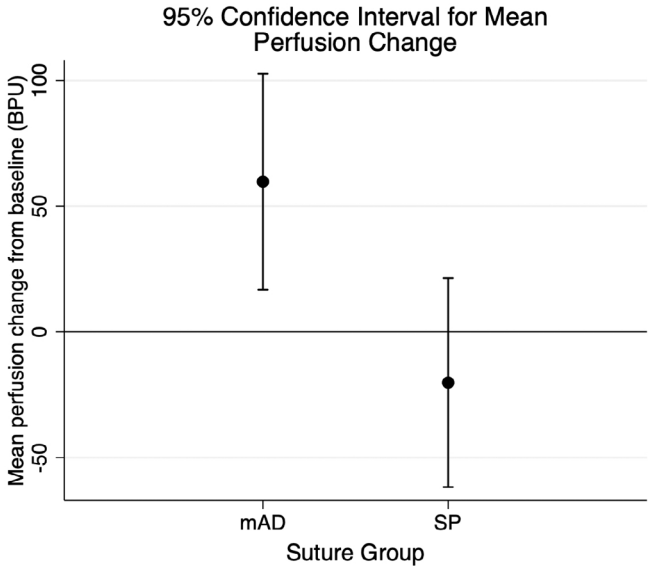

FIGURE 3 Graph to show the mean perfusion changes from baseline with the modified Allgower Donati pattern versus the continuous horizontal mattress pattern.

115.3% ± 261.2% increase from baseline with the mAD pattern and a mean 24.1% ± 130.3% decrease from baseline for the SP pattern.

3.3 | Follow-up data

No cats were re-presented for management of incisional complications in the 30 day period following the study.

4 | DISCUSSION

Consistent with previous studies, this study found a perfusion sparing effect from the mAD pattern.[10,11] Following surgical incision, wound margin perfusion typically increases from baseline due to inflammation induced vasodilation.[17] With the mAD pattern, this increase was identified, suggesting that the pattern allows the tissues to manifest a normal healing response. Notably, however, with the SP pattern perfusion decreased from baseline despite incision, which may have been due to the suture line compressing and impeding capillary flow at the wound margin. Interestingly, despite the relative inferiority of SP to mAD observed in this data, a study comparing SP to interrupted vertical mattress and to skin staples found SP to compromise perfusion less than the two alternatives.[18]

Two buried suture patterns that fundamentally differed only in the direction of the suture bites relative to the incision line were evaluated in this study. Several variants of the Allgower-Donati pattern are available, including an interrupted version with the knot tied externally[9] and a continuous version where the running component is passed external to the skin surface.[13] When evaluated in human skin, no difference in perfusion effect was found between the interrupted and continuous variants of the pattern.[13] In this study the continuous Allgower-Donati pattern was modified further to provide a veterinary version where the running component was passed through the subcutaneous space rather than externally, with the hypothesized advantage that this would be less prone to patient breakage. The perfusion findings suggest that this modification has not compromised the perfusion sparing nature of the pattern. The cosmesis of the two patterns was not formally assessed, but appeared to be very similar.

The mechanisms by which the Allgower-Donati patterns exert their perfusion sparing effect have not been characterized, but studies comparing them to traditional interrupted patterns have offered several theories.[9,10] These include less kinking of feeder arterioles; intradermal plane anchoring sparing the cutaneous microcirculation; and increased ease of correct tensioning relative to other patterns. As both the patterns here were anchored intradermally and at a shared tension yet a substantial effect was still seen, a further theory could be considered. Wounds are almost invariably closed in the direction of lowest tension, which typically places the closed incision in a position parallel to the feeder vessel of the angiosome in which the wound was made. The tributaries of the local direct cutaneous artery are therefore often approaching the wound at an oblique angle. By taking a bite of the intradermal layer at 90° to the incision margin rather than parallel to it, more of the feeder vessels are spared and perfusion is optimized.

Similar to other studies,[10,17,19] this study utilized laser doppler imaging to provide an objective measure of wound perfusion. With this technology, a probe containing a light source transmits laser light into the tissue, where it contacts both stationary cells and circulating red blood cells. Photons are scattered randomly when the laser light strikes the tissues. When the light strikes the moving red blood cells, the incident photons are doppler shifted. This is recorded at the probe head and converted to an electrical signal proportional to blood flow. Because blood flow is not being directly measured, units of measure are relative, making the technology ideal for intra-subject comparisons. This study was able to use a within animal randomized design[14] in which two concurrent interventions were evaluated. Analyzing changes from baseline also allowed each animal to act as its own control.

Studies in other species have found heterogeneity in the perfusion of different regions of abdominal skin.[20,21]

1532950x, 2026, 2, Downloaded from https://onlinelibrary.wiley.com/doi/10.1111/vsu.14322 by Mathieu Jourdain - Oniris Chantrerie , Wiley Online Library on [24/02/2026]. See the Terms and Conditions (https://onlinelibrary.wiley.com/terms-and-conditions) on Wiley Online Library for rules of use; OA articles are governed by the applicable Creative Commons License

For this reason, the intervention was randomized over the two different incision zones to avoid the risk of systematic bias.

This study suffered from several limitations. There is no known perfusion threshold below which wound healing is known to be compromised. The laser doppler perfusion imager was sensitive to patient movement, so anesthesia or heavy sedation was required for accurate use. This limited perfusion measurement to a single immediate post-surgery time period. In addition, although no incisional complications prompted re-presentation to the shelters for any cat in the study, active in-person follow-up was not performed. The suturing time intervals for each pattern were not compared, although it was the authors clinical impression that the two suture patterns took the same amount of time to perform. Finally, the researchers involved in the perfusion measurements could not be blinded due to the visible differences between closure techniques, and only two suture patterns were assessed.

In conclusion, the modified Allgower-Donati intradermal pattern offers an alternative to the standard continuous horizontal intradermal pattern that appears to maintain the advantages of a buried pattern but results in improved perfusion to the wound margin, at least in the acute setting. Although we cannot currently correlate clinical incisional outcomes with higher mean incision perfusion, surgeons may wish to take these findings into consideration when deciding on wound closure technique in cats.

AUTHOR CONTRIBUTIONS

Bayrakdarian S, BS, MPS: Assisted with study design, data acquisition and interpretation; paper draft, revisions, and final approval; agrees to be accountable for all aspects of the work in ensuring that questions related to the accuracy and integrity of any part of the work are appropriately investigated and resolved. Hayes GM, DACVS, DACVECC, PhD: Created the study design, assisted with data acquisition and interpretation; paper draft, revisions, and final approval; agrees to be accountable for all aspects of the work in ensuring that questions related to the accuracy and integrity of any part of the work are appropriately investigated and resolved.

FUNDING INFORMATION

This study was supported by a grant from the College of Agriculture and Life Sciences (CALS), Cornell University.

CONFLICT OF INTEREST STATEMENT

The authors have no conflicts of interest to report.

ORCID

Galina M. Hayes https://orcid.org/0000-0002-1365-3284

REFERENCES

1. Lee JA, Huang C, Hall K. Epidemiology of severe trauma in cats: an ACVECC VetCOT registry study. *J Vet Emerg Crit Care*. 2022;32(6):705-713.
2. Lascelles BD, White RA. Combined omental pedicle grafts and thoracodorsal axial pattern flaps for the reconstruction of chronic, non-healing axillary wounds in cats. *Vet Surg*. 2001; 30(4):380-385.
3. Forster K, Cutando LS, Ladlow J, Anderson D, et al. Outcome of caudal superficial epigastric axial pattern flaps in dogs and cats: 70 cases. *J Small Anim Pract*. 2022;63(2):128-135.
4. Maske M, McClaran JK, Mariano A. Short term wound complications and predictive variables for complication after limb amputation in dogs and cats. *J Small Anim Pract*. 2015;56(4): 247-252.
5. Cantatore M, Ferrari R, Boracchi P, et al. Factors influencing wound healing complications after wide excision of injection site sarcomas of the trunk in cats. *Vet Surg*. 2014;43(7):783-790.
6. Bohling MW, Henderson RA. Differences in cutaneous wound healing between dogs and cats. *Vet Clin North Am*. 2006;36(4): 687-692.
7. Bohling MW, Henderson RA, Swaim SF, Kincaid SA, Wright JC. Cutaneous wound healing in the cat: a macroscopic description and comparison with cutaneous wound healing in the dog. *Vet Surg*. 2004;33:579-587.
8. Taylor G, Minabe T. The angiosomes of the mammals and other vertebrates. *Plastic Reconstr Surg*. 1992;89(2):181-215.
9. Smeak DD. Buried continuous intradermal suture closure. *Compend Contin Euduc Pract Vet*. 1992;14:907-919.
10. Shannon SF, Houdek MT, Wyles CC, et al. Allgower-Donati versus vertical mattress suture technique impact on perfusion in ankle fracture surgery: a randomized clinical trial using intraoperative angiography. *J Orthop Trauma*. 2017;31(2):97-102.
11. Sagi H, Papp S, Dipasquale T. The effect of suture pattern and tension on cutaneous blood flow as assessed by laser Doppler flowmetry in a pig model. *J Orthop Trauma*. 2008;22(3):171-175.
12. Mueller ME, Allgower M, Scheider R, et al. *Manual of Internal Fixation. Techniques Recommended by the AO-ASIF Group*. 3rd ed. Springer-Verlag; 1995.
13. Thamyongkit S, Luksameearunothai K, Shafiq B, et al. Peri-incisional perfusion does not differ between running versus interrupted Allgower-Donati suture technique in ankle fracture surgery: a pilot randomized controlled trial of wound perfusion. *OTA Int*. 2021;18(4):1-8.
14. Pandis N, Chung B, Scherer R, et al. CONSORT 2010 statement: extension checklist for reporting within person randomized trials. *BMJ*. 2017;367:j2835.
15. Griffin B, Bushby PA, McCobb E, et al. The association of shelter veterinarians' 2016 veterinary medical care guidelines for spay-neuter programs. *J Am Vet Med Assoc*. 2016;249:165-188.
16. Lopez DJ, Hayes GM, Fefer G, et al. Effect of subcutaneous closure technique on incisional complications and postoperative pain in cats undergoing midline celiotomy: a randomized, blinded, controlled trial. *Vet Surg*. 2020;49(2):321-328.
17. Rendell MS, Millikan BK, Finnegan MF. The skin blood flow response in wound healing. *Microvasc Res*. 1997;53:222-234.
18. Wyles C, Jacobson SR, Houdek MT, et al. Running subcuticular closure enables the most robust perfusion after TKA: a randomized clinical trial. *Clin Orthop Relat Res*. 2016;474:47-56.

1532950x, 2026, 2, Downloaded from https://onlinelibrary.wiley.com/doi/10.1111/vsu.14322 by Mathieu Jourdain - Oniris Chantrerie , Wiley Online Library on [24/02/2026]. See the Terms and Conditions (https://onlinelibrary.wiley.com/terms-and-conditions) on Wiley Online Library for rules of use; OA articles are governed by the applicable Creative Commons License

19. Zografos GC, Martis K, Morris DL. Laser Doppler flowmetry in evaluation of cutaneous wound blood flow using various suturing techniques. *Ann Surg*. 1992;215(3):266-268.
20. Tregaskiss A, Goodwin A, Acland R. The cutaneous arteries of the anterior abdominal wall: a three-dimensional study. *Plastic Recon Surg*. 2007;120(2):442-450.
21. Casal D, Pais D, Iria I. Blood supply to the integument of the abdomen of the rat: a surgical perspective. *Plastic Recon Surg*. 2017;5(9):e1454.

How to cite this article: Bayrakdarian S, Hayes GM. Comparison of the effect on blood flow of two intradermal suture patterns in feline skin: A within animal randomized controlled trial. *Veterinary Surgery*. 2026;55(2):356-362. doi:10.1111/vsu.14322

1532950x, 2026, 2, Downloaded from https://onlinelibrary.wiley.com/doi/10.1111/vsu.14322 by Mathieu Jourdain - Oniris Chantrerie , Wiley Online Library on [24/02/2026]. See the Terms and Conditions (https://onlinelibrary.wiley.com/terms-and-conditions) on Wiley Online Library for rules of use; OA articles are governed by the applicable Creative Commons License